



Long-Term Survival for 10 Years of a Patient with Amyloidosis of the Gastro-Intestinal Tract : Improvement of Clinical Manifestations by Using Oral DMSO and Intravenous...

Isobe, Takashi ; Banno, Kohji ; Banno, Yasuo ; Yamamoto, Sadahiro ; Koike, Akihiko ; Takeshige, Kotohito ; Kanemitsu, Yasuishi ; Kato,...

(Citation)

Bulletin of allied medical sciences Kobe : BAMS (Kobe), 13:185-191

(Issue Date)

1997-12-26

(Resource Type)

departmental bulletin paper

(Version)

Version of Record

(URL)

<https://hdl.handle.net/20.500.14094/00188187>



Long-Term Survival for 10 Years of a Patient with Amyloidosis of the Gastro-Intestinal Tract—Improvement of Clinical Manifestations by Using Oral DMSO and Intravenous Hyperalimentation

Takashi Isobe¹, Kohji Banno², Yasuo Banno³, Sadahiro Yamamoto², Akihiko Koike², Kotohito Takeshige², Yasuishi Kanemitsu² and Kenichi Kato².

At the age of 58, the patient started to recognize clinical manifestations of diarrhea and abdominal pain. Unresponsive to glucocorticoid administration or sarazopyrin intake, a clinical diagnosis of nonspecific enterocolitis was made. However, a histological examination on a rectal biopsy introduced her an admission to the hospital obtaining a histological diagnosis of amyloid deposits. On admission, she was found to be poorly nourished and anemic. The skin was slightly edematous and abdominal surface was slightly distended. She had remarkable improvement under total parenteral nutrition with oral intake of dimethylsulfoxide (7.5 gm daily for a year and 3 gm daily for subsequent 3 years), observing clinical and laboratory findings. She has been well at home for the following 10 years, when she was found to have increased proteinuria and high blood urea nitrogen. Manual peritoneal dialysis started, 4 times a week at out-patient clinic. A total 10 years survival of gastro-intestinal amyloidosis in this patient was here in described.

Key words

Amyloidosis,
GI tract,
Rheumatoid arthritis,
Dimethylsulfoxide (DMSO),
Intravenous alimentation.

INTRODUCTION

Amyloidosis, as a clinical disorder of physiologically insoluble amyloid materials in various organs and tissues, severely impaired functions of involved organs and poor prognosis of

amyloidotic patients.^{1,2)} In the present paper, more than 10 years of survival in a patient with gastro-intestinal amyloidosis is described and discussed. Total parenteral nutrition (TPN) with oral intake of dimethylsulfoxide (DMSO)³⁻¹⁰⁾ appeared to give clinical improvements. Long-term survival is very rare among amyloidotic cases.

Case presentation

Ban. 61year-old female was found to have abdominal pain, diarrhea and fever for several months, resulting in generalized malnutrition.

Her family and past histories are

Faculty of Allied Medical Science, Kobe University School of Medicine¹, Kobe, Japan. First Department of Surgery, Aichi Medical College School of Medicine², Nagakute, Aichi, Banno clinic³. Nagoya, Japan.

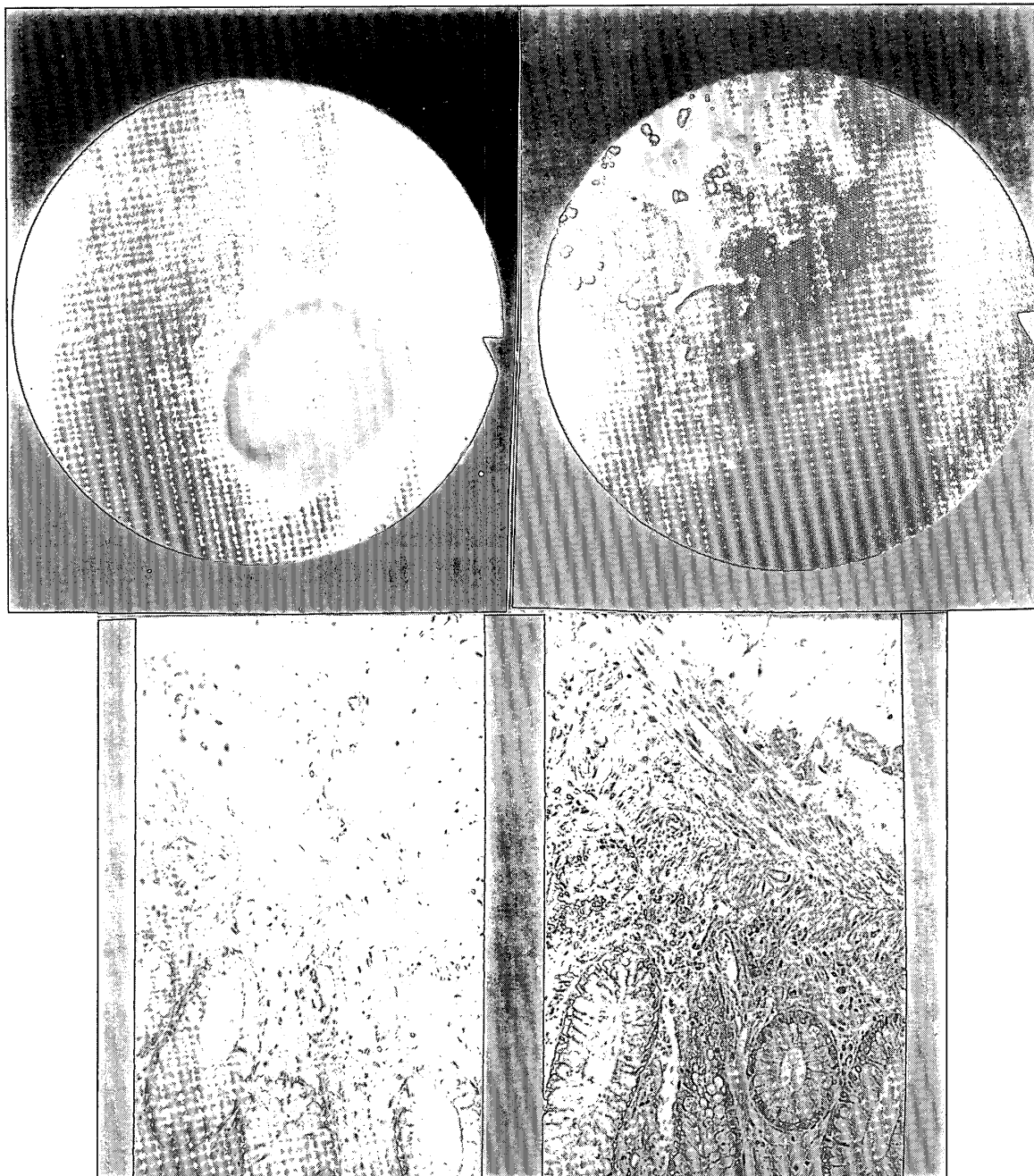


Figure 1. Colonofiber revealed anemic and edematous mucous membranes of the colon (right upper), and histologic findings of the biopsy revealed eosinophilic substance of amyloid was seen in the subcutaneous tissue (right lower), gastrofiber (left upper) also showed anemic and edematous. The biopsied (left lower) material also showed amyloid.

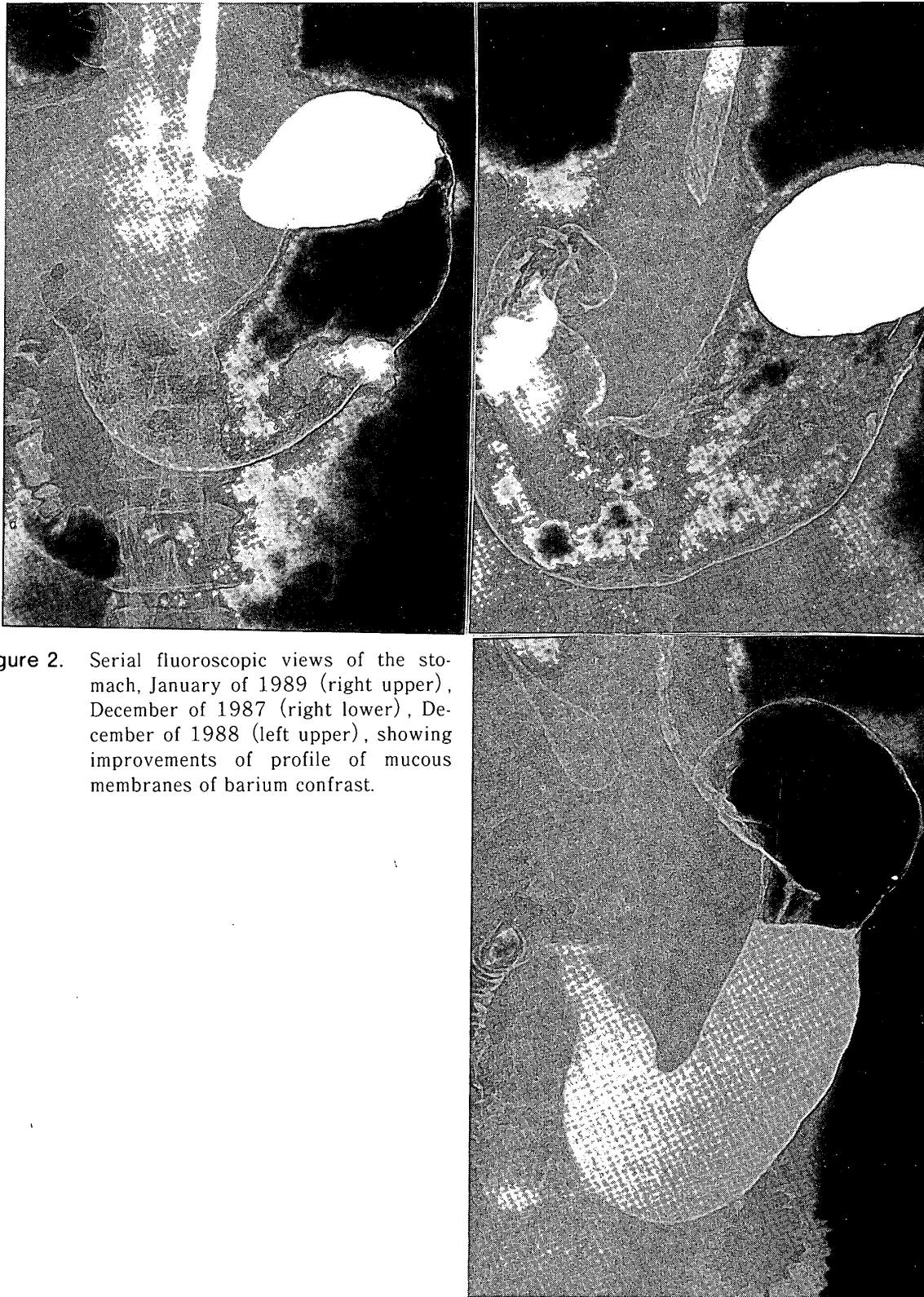


Figure 2. Serial fluoroscopic views of the stomach, January of 1989 (right upper), December of 1987 (right lower), December of 1988 (left upper), showing improvements of profile of mucous membranes of barium contrast.




Figure 3. Barium enema and silhouette of mucous membrane of the colon, with gradual improvement (see in the text) December of 1987 (right upper), May of 1988 (right lower), June of 1989 (left upper), and December of 1988 (left lower).

contributory, since her mother died of collagen disease of unknown aspects in details after a long-term suffering of joint pain and chronic rheumatoid arthritis.

Past history of the patient started about 20 years ago when she was found to have chronic rheumatoid arthritis (RA), followed by gradual development to stage III RA with joint deformity. She had neither gold-injection therapy nor adreno-cortico-steroid administration.

An abdominal X-ray film showed gas forming appearance from transverse to descending colon, suggestive of edematous mucous membranes of the colon. An additional finding was calcification in the left kidney on a plain film. Further investigations on mucous membrane of the colon were performed as in Figure 1, by means of barium enema and colonofiber examination. Firstly, barium enema demonstrated disappearance of folds and haustra of the colon showing sclerotic pattern. Secondly, a colonofiber provided macroscopic profile of mucous membrane being anemic, edematous and coarse in nature with a mixture of small-sized granules and micro-ulcers of 1 to 2 mm in diameter. Biopsied materials were of whitish and jelly-like material. Congo-red stained histology showed amyloid deposits in the muscularis mucosae and submucosal area, especially around small arteries, as in Figure 1. Fluoroscopy showed decreased motion of peristalsis of the esophagus, stomach and duodenum, at the time of an examination on admission. A gastrointestinal fiber demonstrated similar abnormality to that of the colonofiber ie, the mucous membrane to be ane-

mic, edematous and coarse in nature in association of mixture of micro-granules of amyloid and small ulcer as in Figure 1. Biopsied materials from the duodenum were also congo-red positive, with a result of KMnO₄ sensitive congo-red positivity, which is considered amyloid as amyloidosis of A protein (AA) type. In a short summary, she was found to have AA type amyloidosis in the gastrointestinal tract, probably secondary to chronic rheumatoid arthritis.

As for clinical manifestations, she had a marked improvement of malnutrition within a month after admission, she could be released from TPN. As for the treatment for gastrointestinal amyloid, oral intake of DMSO was started 7.5 gm as a daily dose for a year, then the daily dose increased up to 15 gm during hospitalization. After she was discharged from the hospital, the maintenance dose of oral DMSO was continuously 3 gm a day for the subsequent 3 years. Figure 2 demonstrated an improvement of profile of mucous membranes of barium contrast in the stomach with 14 months interval, firstly on Dec. 1987 to and secondly Jan. 1989.

There also showed reappearance of flattened haustra ie, abnormal lead-pipe like pattern in the colon to normal looking intestine profile examined repeatedly, 1st on December 1987, secondly May 1988, thirdly December 1988 and fourthly January 1989, as already shown in Figure 1 and 3.

Clearly normalization of the mucous membrane of the colon was obtained, she was back to home and fortunately, both husband and a son of her own are surgeons who could manage the

present case under their meticulous control of nutrition, body weight with repeated laboratory examinations.

Ordinary meals, alimentary supply, as well as electrolyte-fluid balance were strictly managed at Banno clinic, without any abnormal manifestation of abdominal pain, diarrhea, and vomiting, she has been doing well and certainly is well at present at home for the following 10 years after the discharge from the hospital.

Recently she was found to be slightly anemic and to have increased tendency of blood urea nitrogen level up to 80 mg/dl with increased proteinuria (mainly albumin on the basis of urinary protein electrophoretic fractionation). Selecting the maneuver of manual and handy peritoneal dialysis (PD) performed 4 times a day with 6 hours interval at Banno Clinic at a supplemental bedside in order to reduce hyperazotemia. Approximate improvement of BUN from 80 to 15 mg/dl and serum K from 6 to 4 mEq/l was obtained by handling peritoneal dialysis. In summary, continuous DMSO administration 3 gm daily in association with intravenous alimentation appeared to be effective to maintain daily active life and so-called quality of life (QOL) of a 58 year-old patient with gastro-intestinal amyloidosis and clinically malabsorption syndrome at the onset of the disease. A long-term survival for 10 years of life under controlled alimentation followed by manually-continued peritoneal dialysis for the chronic renal failure probably secondary to renal amyloidosis.

DISCUSSION

Amyloidosis is a group of clinical disorders consisting of systemic amyloidosis such as amyloidosis of immunoglobulin L-chain type (AL), amyloidosis of A protein type (AA), familial amyloid polyneuropathy (FAP) and of localized organ-limited amyloidosis. Amyloidosis is defined to have certain organs or tissues which are precipitated by insoluble substance called as amyloid fibril proteins, and have impaired their physiologic functions of organs or tissues due to amyloid depositions. Systemic type has multiorgans involved, while organ-limited type has thus a single organ involved. Gastro-intestinal amyloidosis is usually seen in systemic amyloidosis particularly in AL (so-called primary amyloidosis or myeloma-associated amyloidosis) as well as in AA (so-called reactive or secondary) amyloidosis.

The author published a paper describing another patient with more than 10 year's observation for amyloid deposits in the gastro-intestinal tract in a patient with AL amyloidosis with 10 year's out-patient clinic without medication,⁵⁾ where a 77 year old female was found to have the amyloid in the stomach and duodenum and the colon. The patient was also doing well without medication except oral intake of DMSO 5 gm a day for 2 years and gefarnate for 6 years. Ischemia could be a cause of narrowing and ulceration that stimulate regional enteritis. However, the prognosis study in gastro-intestinal amyloidosis has not been well documented. Prognosis may depend on the location and intensity of the infiltration of amyloid deposits. Furth-

ermore, in the present case of AA type amyloidosis, proteinuria and chronic renal failure representing such as increases of blood urea nitrogen may strongly influence the patient's prognosis, this renal failure, the patient had fortunately had opportunities of aggressive and repeated manual handling at home of continuous intraperitoneal dialysis.

REFERENCES

- 1 . Kyle RA and Bayard ED : Amyloidosis, Review of 236 cases. *Med* 54 : 271-299, 1975
- 2 . Glenner GG : Amyloid deposits and amyloidosis. *New Engl J. Med* 302 : 1336, 1980
- 3 . Van Rijiswigk MH : Treatmeant of renal amyloidosis with dimethyl sulfoxide and colchicine therapy, *Proc. EDTA* 16 : 500, 1979
- 4 . Kisilevsky R : Kinetics of amyloid deposition II , The effects of dimethyl sulfoxide and colchicine therapy. *Lab Invest* 48 : 60, 1983
- 5 . Isobe T, Kayama T, Morishita N et al. : Amyloid deposits in the gastro-intestinal tract in a patient with AL amyloidosis with 10 year's out patient clinic without medication. *Bull Kobe Allied Med Sci, Kobe* 11 : 161-166, 1995
- 6 . Ravid M, Lang R, Kedor I : Prolonged dimethyl sulfoxide treatment in 13 patients with systemic amyloidosis. *Ann Rheum Dis* 41 : 587- 592, 1982
- 7 . Hasegawa Y, Matsuo T, Ishibashi H et al : Amyloid A protein in a case of primary amyloidosis. *Jap J Intern Med*, 72 : 56-62, 1983
- 8 . Imai Y, Himeno S, Shinomura Y et al. : Improvements of gastoro intestinal symptoms in a case of AA type amyloidosis by the combination therapy of prednisolone and dimethyl sulfoxide. *Jap J Intern Med* 73 : 90-95, 1984
- 9 . Lake B and Andrews G : Rheumatoid arthritis with secondary amyloidosis and malabsorption syndrome. Effect of D-penicillamines. *Am J Dig Dis* 13 : 613-618, 1968
10. Isobe T, Matsumoto J, Tomita M et al. : DMSO therapy using dermal application, to patients with systemic amyloidosis. In. *Amyloid and Amyloidosis*, PP 815-832, Plenum press, New York, 1987