



Tumor Shrinkage by Metyrapone in Cushing Disease Exhibiting Glucocorticoid-Induced Positive Feedback

Tsujimoto, Yasutaka ; Shichi, Hiroki ; Fukuoka, Hidenori ; Yamamoto, Masaaki ; Sato, Itsuko ; Imanishi, Takamitsu ; Nakamura, Tomoaki ;...

(Citation)

Journal of the Endocrine Society, 5(6):bvab055

(Issue Date)

2021-06

(Resource Type)

journal article

(Version)

Version of Record

(Rights)

© The Author(s) 2021. Published by Oxford University Press on behalf of the Endocrine Society.

This is an Open Access article distributed under the terms of the Creative Commons Attribution-NonCommercial-NoDerivs licence (<http://creativecommons.org/licenses/by-nc-nd/4.0/>)

(URL)

<https://hdl.handle.net/20.500.14094/0100476438>



Clinical Research Article

Tumor Shrinkage by Metyrapone in Cushing Disease Exhibiting Glucocorticoid-Induced Positive Feedback

Yasutaka Tsujimoto,^{1,*} Hiroki Shichi,^{2,*} Hidenori Fukuoka,³
Masaaki Yamamoto,³ Itsuko Sato,⁴ Takamitsu Imanishi,⁴
Tomoaki Nakamura,¹ Naoko Inoshita,⁵ Atsushi Ishida,⁶ Shozo Yamada,^{6,7}
Yutaka Takahashi,² and Kazuo Chihara¹

¹Division of Diabetes and Endocrinology, Akashi Medical Center Hospital, Akashi 674-0063, Japan; ²Division of Diabetes and Endocrinology, Kobe University School of Medicine, Kobe 650-0017, Japan; ³Division of Diabetes and Endocrinology, Kobe University Hospital, Kobe 650-0017, Japan; ⁴Department of Clinical Laboratory, Kobe University Hospital, Kobe 650-0017, Japan; ⁵Department of Pathology, Tokyo Metropolitan Geriatric Medical Center, Tokyo 173-0015, Japan; ⁶Pituitary Center, Moriyama Memorial Hospital, Tokyo 134-0088, Japan; and ⁷Department of Hypothalamic and Pituitary Surgery, Toranomon Hospital, Tokyo 105-8470, Japan

ORCID numbers: 0000-0002-6028-1022 (Y. Tsujimoto); 0000-0001-9255-653X (H. Fukuoka).

*Yasutaka Tsujimoto, and Hiroki Shichi contributed equally to this work.

Abbreviations: ACTH, adrenocorticotropic hormone; ACTHoma, ACTH-secreting pituitary adenoma; CD, Cushing disease; Dex, dexamethasone; DST, dexamethasone suppression test; EAS, ectopic ACTH syndrome; GC, glucocorticoid; HDDST, high-dose DST; IRMA, immunoradiometric assay; LDDST, low-dose DST; MRI, magnetic resonance imaging; PCR, polymerase chain reaction; UFC, urinary free cortisol.

Received: 30 October 2020; Editorial Decision: 23 March 2021; First Published Online: 30 March 2021; Corrected and Typeset: 24 May 2021.

Abstract

Context: Paradoxical increases in serum cortisol in the dexamethasone suppression test (DST) have been rarely observed in Cushing disease (CD). Its pathophysiology and prevalence remain unclear.

Case Description: A 62-year-old woman with suspected CD showed paradoxical increases in cortisol after both 1-mg and 8-mg DST (1.95-fold and 2.52-fold, respectively). The initiation of metyrapone paradoxically decreased plasma adrenocorticotropic hormone (ACTH) levels and suppressed cortisol levels. Moreover, the pituitary tumor considerably shrank during metyrapone treatment.

Ex Vivo Experiments: The resected tumor tissue was enzymatically digested, dispersed, and embedded into Matrigel as 3D cultured cells. ACTH levels in the media were measured. In this tumor culture, ACTH levels increased 1.3-fold after dexamethasone treatment ($P < 0.01$) while control tumor cultures exhibited no increase in ACTH levels, but rather a 20% to 40% suppression ($P < 0.05$).

ISSN 2472-1972

© The Author(s) 2021. Published by Oxford University Press on behalf of the Endocrine Society. This is an Open Access article distributed under the terms of the Creative Commons Attribution-NonCommercial-NoDerivs licence (<http://creativecommons.org/licenses/by-nc-nd/4.0/>), which permits non-commercial reproduction and distribution of the work, in any medium, provided the original work is not altered or transformed in any way, and that the work is properly cited. For commercial re-use, please contact journals.permissions@oup.com

Clinical Study: A cross-sectional, retrospective, multicenter study that included 92 patients with CD who underwent both low-dose and high-dose DST from 2014 to 2020 was performed. Eight cases (8.7%) showed an increase in serum cortisol after both low-dose and high-dose DST.

Conclusion: This is the first report of a patient with glucocorticoid (GC)-driven positive feedback CD who showed both ACTH suppression and tumor shrinkage by metyrapone. Our cohort study revealed that 8.7% of patients with CD possibly possess GC-driven positive-feedback systems, thereby suggesting the presence of a new subtype of CD that is different from the majority of CD cases. The mechanisms exhibiting GC positive feedback in CD and the therapeutic approach for these patients remain to be investigated.

Key Words: Cushing disease, positive feedback, metyrapone, tumor shrinkage, 3D culture

The dexamethasone (Dex) suppression test (DST) has been used to differentiate Cushing disease (CD) from pseudo-CDs such as depression and alcoholism. Glucocorticoid (GC) resistance against a small Dex dose has been elucidated by the presence of a higher threshold in CD, since adrenocorticotropic hormone (ACTH) secretion has been found to be suppressed by a larger dose of Dex in the majority of CD cases [1, 2]. The molecular mechanism by which the GC-driven negative feedback system is disrupted in CD has been explained partly by the high expression of 11 β -hydroxysteroid dehydrogenase-2 (HSD2) and heat shock protein 90 (HSP90), along with low nuclear Brg1 protein levels in ACTH-secreting pituitary adenomas (ACTHomas) [3].

Additionally, a paradoxical rise in serum cortisol after DST has been reported in several cases of ectopic ACTH syndrome (EAS), mostly pheochromocytomas [4-12]; however, there are limited reports describing this paradoxical glucocorticoid response in CD [13]. Although these reports suggest the presence of a GC-driven positive feedback loop, none of them has experimentally established the GC-driven positive regulation of ACTH in ACTHomas. Furthermore, the effect of GC on tumor proliferation in these tumors remains unclear. Here, we present a case of CD showing clear clinical and pathophysiological evidence of a GC positive feedback system. In this case, GC suppression by metyrapone resulted in clinical tumor shrinkage. Additionally, we also established an ex vivo 3-dimensional (3D) culture system of ACTHomas to assess the hormonal response to drugs including Dex and demonstrated the response of the tumor culture to GC. Finally, we performed a retrospective analysis to investigate the prevalence of GC-driven positive feedback in CD according to the DST results.

Methods

Multicenter Retrospective Study

For the cross-sectional retrospective multicenter study, 92 patients with CD who underwent both low-dose DST

(LDDST) and high-dose DST (HDDST) from 2014 to 2020 in Akashi Medical Center Hospital, Kobe University Hospital, Toranomon Hospital, and Moriyama Memorial Hospital were included. In all these subjects, the diagnosis of CD was performed according to the guidelines [14], and the diagnosis was confirmed by pathological findings.

Hormone Assays

Plasma ACTH and serum cortisol levels were measured by an enzyme immunoassay (Electro Chemiluminescence Immunoassay and Enzyme Immunoassay; TOSOH, Tokyo, Japan) and the urinary free cortisol (UFC) levels were measured by immunoradiometric assay (IRMA; TFB, Tokyo, Japan). The reference range of ACTH is 7.2 to 63.3 pg/mL, that of cortisol is 7.07 to 19.6 μ g/dL, and that of UFC is 11.2 to 80.3 μ g/day. In the multicenter study, some UFC levels were measured by chemiluminescent immunoassay (CLIA; Siemens, Tokyo, Japan). Therefore, UFC levels measured by CLIA were corrected into the value measured by IRMA, using the following formula ($Y = 0.917X - 2.80$, $Y = \text{IRMA}$, $X = \text{CLIA}$). ACTH levels in the cultured media were measured using an enzyme immunoassay kit (ECLIA; Roche, Tokyo, Japan).

DNA Extraction and Gene Sequencing

Genomic DNA was isolated from the surgically resected ACTHoma tissues using QIAamp \rightarrow DNA FFPE kit (QIAGEN Inc., Hilden, Germany). Hotspot coding sequences of *USP8*, *UPS48*, and *BRAF* genes were amplified with GoTaq DNA polymerase (Promega, Mannheim, Germany) by polymerase chain reaction (PCR). The PCR products were verified by gel electrophoresis and extracted by using the QIAquick Gel Extraction kit (QIAGEN Inc., Hilden, Germany) and sequenced using BigDye Terminator Cycle Sequencing Kit and ABI PRISM 310 Genetic Analyzer as previously described [15, 16]. The details of the primers are shown in Table 1.

3D Culture of ACTHomas

The resected tumor tissue was immediately stored in ice-cold phosphate-buffered saline. The cells were then transferred to the bench and enzymatically digested using Dulbecco's Modified Eagle Medium (DMEM) containing 0.3% bovine serum albumin, 0.35% collagenase, and 0.15% hyaluronidase, after which they were dispersed. Matrigel (growth factor reduced; phenol red free; BD Biosciences) was polymerized for 10 minutes at 37 °C. The cells were embedded into Matrigel and placed in 48-well plates (Corning) (8000 cells per well). A volume of 250 μ L culture medium (DMEM [Gibco] supplemented with 10% fetal bovine serum [Gibco] and antibiotics) was added to each well. The cells were incubated at 37 °C in a 5% CO₂ incubator. On the day after plating, the medium was replaced with a serum-starved medium (DMEM with 0.5% bovine serum albumin). After 24 hours of serum starvation, the cells were treated with Dex (10nM) or the vehicle (DMSO), as previously shown [17]. The medium was collected at 24, 48, and 72 hours and the ACTH levels were measured as described in "Hormone Assays." Each experiment was performed in triplicates.

Ethics

All experiments and studies were conducted in compliance with the protocol that was reviewed and approved by the Research Ethics Committee of Kobe University Hospital (IRB#1363). Additionally, written informed consent was obtained from all the patients.

Statistical Analysis

All statistical analyses were performed using SAS 11.2 (Statistical Analysis Software release 11.2; SAS Institute Inc., Cary, NC, USA). Data were presented as mean \pm standard deviation. The paired *t* test was used to compare the values of the means between 2 related samples. The correlation between nonparametric data was assessed using Spearman's rank correlation. The cutoff of *P* \leq 0.05 was considered as statistically significant.

Table 1. Primer sequences used in this study

Gene	F/R	Sequence
USP8	Forward	5'-CTTGACCCAATCACTGGAAC-3'
	Reverse	5'-TTACTGTTGGCTTCCTCTTCTC-3'
USP48	Forward	5'-TGCCTGCTATAATCCTGGAAA-3'
	Reverse	5'-TCAGCAGAACCTTCTAAGTCTCA-3'
BRAF	Forward	5'-GGCCAAAAATTTAATCAGTGGA-3'
	Reverse	5'-CATAATGCTTGCTCTGATAGGA-3'

Case Description

A 62-year-old woman was referred to the endocrinology department complaining of general malaise, edema, and hypokalemia. At age 60, she was prescribed antihypertensive drugs. Three months before the visit, she developed a vertebral fracture and sudden back pain. Currently, she consulted a primary physician chiefly due to facial and leg edema. Her laboratory test results showed hypokalemia, after which she was referred to our department for further examination. She had a history of surgery for breast cancer at age 53. She had been taking indapamide, candesartan, and amlodipine for hypertension, celecoxib for back pain of vertebral fracture, and rebamipide for peptic ulcer. She had not used topical or oral steroids as far as it could be confirmed. Her family had no history of endocrine metabolic diseases or neoplasms. Patient characteristics are shown in Table 1. Her blood pressure was high despite taking antihypertensive drugs. She presented with a typical Cushingoid appearance including a moon face, central obesity, and ecchymosis of her trunk and extremities. The remainder of the physical examination was unremarkable.

Laboratory test results were shown in Table 2. She showed hypokalemia with enhanced urinary K excretion. An analysis of whole white blood cells and their fractions showed leukocytosis with high neutrophilia, low lymphopenia, and eosinopenia. Electrocardiography and chest radiography did not reveal remarkable findings.

Endocrinological findings revealed a high serum cortisol level (27.72 μ g/dL) with an elevated plasma ACTH level (299.2 pg/mL). Since the plasma ACTH level was remarkably high compared to cortisol, we performed gel filtration chromatography for the patient's plasma, showing that there was 2 fraction peak. One peak around 47 kDa suggested ¹⁻³⁹ACTH fraction, while a higher fraction indicated the presence of big ACTH (Fig. 1). An impaired cortisol circadian rhythm was observed with elevated midnight cortisol levels (43.14 μ g/dL) (Table 3). Furthermore, her UFC levels were remarkably high (988 μ g/day). Intriguingly, 1-mg DST revealed a paradoxical rise in ACTH (from 175.8 to 351.4 pg/mL) and cortisol (from 19.98 to 39.03 μ g/dL) rather than impaired suppression (Table 3). A corticotropin-releasing hormone test showed a slight increase in ACTH (1.4-fold) within 45 minutes (Table 4). Furthermore, 8-mg DST also exhibited a paradoxical elevation in both plasma ACTH (from 175.8 to 233.9 pg/mL) and serum cortisol (from 19.98 to 50.28 μ g/dL) levels (Table 3). Additionally, magnetic resonance imaging (MRI) of the pituitary revealed a 14-mm macroadenoma (Knosp grade 2) [Fig. 2A and 2B]. We clinically diagnosed this patient with Cushing disease according to the guidelines [14]. Notably, these data indicated a positive feedback response to GC in the pituitary tumor.

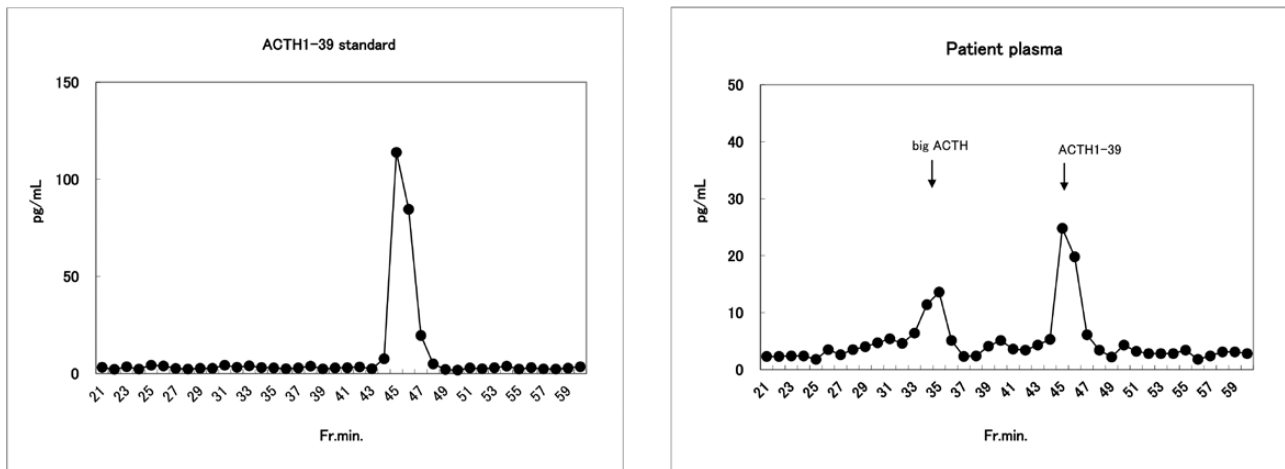


Figure 1. ACTH fraction analysis by gel filtration chromatography.

Table 2. Patient Characteristics and Laboratory Findings

Variable	Result	Reference range
Height (m)	1.53	
Body weight (kg)	54.0	
Body mass index (kg/m ²)	23.1	
Blood pressure (mmHg)	168/84	
Pulse rate (/min)	97	
Blood		
White-cell count (/μL)	14 890	4500–8000
Neutrophils (%)	90.3	40–70
Eosinophils (%)	0.2	0.0–7.0
Basophils (%)	1.9	0.0–1.0
Monocytes (%)	4.5	2.0–7.0
Lymphocytes (%)	3.1	27–47
Hemoglobin (g/dL)	12.1	12–16
Hematocrit (%)	36.5	35–50
Platelet count (/μL)	341 000	100 000–330 000
Total protein (g/dL)	6.0	6.3–8.2
Albumin (g/dL)	3.9	3.5–5.0
Urea nitrogen (mg/dL)	13.6	8.0–20.0
Creatinine (mg/dL)	0.47	0.5–1.2
Sodium (mEq/L)	148	135–147
Potassium (mEq/L)	2.1	3.3–4.8
Chloride (mEq/L)	97	98–108
Aspartate aminotransferase (U/L)	26	8–38
Alanine aminotransferase (U/L)	52	4–44
Lactate dehydrogenase (U/L)	514	106–211
Alkaline phosphatase (U/L)	919	104–338
γ-glutamyl transpeptidase (U/L)	167	16–73
Creatine kinase (U/L)	61	25–170
C-reactive protein (mg/dL)	0.6	0.0–0.3
Urine		
Creatinine (mg/dL)	48.84	
Sodium (mEq/L)	80	70–250
Potassium (mEq/L)	32.4	25–100
Chloride (mEq/L)	75	70–250

Table 3. Dexamethasone suppression test

	Basal	Midnight	LDDST	HDDST
ACTH (pg/mL)	175.8	261.7	351.4	233.9
Cortisol (μg/dL)	19.98	43.14	39.03	50.28

Plasma ACTH and serum cortisol levels at early morning as basal, after low-dose (1 mg) dexamethasone suppression test (LDDST), and after high-dose (8 mg) dexamethasone suppression test (HDDST) are shown.

To block the positive feedback loop by GC and control hypercortisolemia, metyrapone (1000 mg/day) administration was initiated. Thereafter, plasma ACTH levels gradually declined to 147 pg/mL as the cortisol level dropped to 4.12 μg/dL. Surprisingly, remarkable tumor shrinkage was observed in the pituitary MRI 2 months after the initiation of metyrapone [Fig. 2C and 2D]. For further treatment, the patient was referred to the Department of Neurosurgery. Surgical findings revealed no macroscopic apoplexy of the tumor, such as bleeding or necrosis, and no extensive invasion of the tumor into the cavernous sinus. Additionally, a pathological investigation ruled out intratumoral bleeding and necrosis, and immunostaining for ACTH revealed positive results in the resected tumor that was diagnosed as a densely granulated corticotroph adenoma, although Crooke's degeneration was partially recognized (Fig. 3). On postoperative day 8, early morning plasma ACTH and cortisol were 35.8 pg/mL and 7.63 μg/dL, respectively. Although UFC dropped to normal levels (39.4 μg/day), the detection of modest ACTH levels 8 days after adenomectomy is suspicious for the existence of a residual tumor. Nevertheless, the possibility of the detectable ACTH being derived from normal corticotrophs recovered by decreased cortisol because of metyrapone treatment

Table 4. Corticotropin-releasing hormone test

	0 min	30 min	60 min	90 min
ACTH (pg/mL)	160.2	227.7	215.2	
Cortisol (µg/dL)	17.17		24.92	22.28

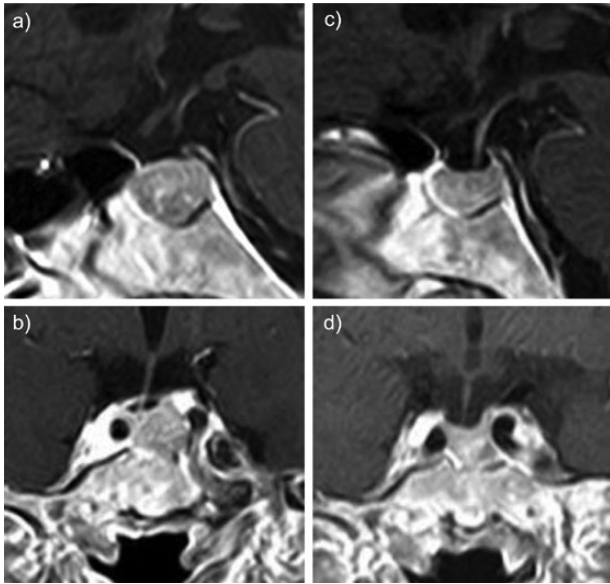


Figure 2. Pituitary magnetic resonance imaging (MRI) before and following metyrapone treatment. The gadolinium-enhanced MRI T1 weighted imaging findings of the sagittal section (a) and coronal section (b) of the patient are shown. Tumor shrinkage after metyrapone initiation is shown in the sagittal section (c) and coronal section (d).

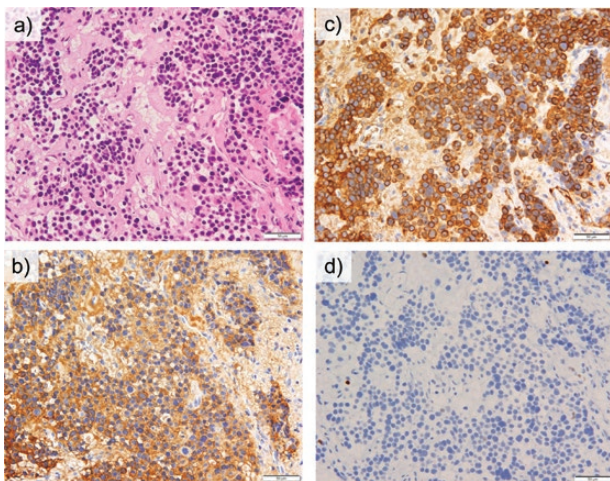


Figure 3. Histological findings of the resected pituitary tumor. Pathological findings of the resected ACTHoma are shown as hematoxylin and eosin (a), ACTH (b), CAM 5.2 (c), and Ki-67 (d) stainings.

is not ruled out. Three months after transsphenoidal surgery, her symptoms and Cushingoid appearance improved and plasma ACTH levels were 40.5 pg/mL, with a cortisol level of 6.98 µg/dL. At the same time, we discontinued

hydrocortisone replacement therapy. Five months after transsphenoidal surgery, 0.5-mg DST resulted in a plasma ACTH of 11.1 pg/mL and cortisol of 1.78 µg/dL.

Ex Vivo Studies

To determine the direct effect of Dex on ACTH secretion in the tumors, we used the 3D culture spheroid of resected ACTHoma cells as described in the methods (Fig. 4A).

In this case, ACTH levels in the media were significantly increased by 10nM Dex treatment at 48 hours (1.27-fold, $P = 0.02$) and 72 hours (1.30-fold, $P < 0.01$) (Fig. 4B). In addition, we further conducted 3D culture experiments using 2 other tumors as controls. The clinical findings of control patients with CD are as follows:

In control patient 1, serum cortisol levels after HDDST were suppressed, while a slight elevation after LDDST was exhibited. In control patient 2, serum cortisol levels after LDDST were slightly reduced (Table 5). Although HDDST was not performed in this patient due to the severe disease with marked UFC levels (1400 µg/day) and the presence of typical CD, plasma ACTH levels were elevated after metyrapone initiation; ACTH levels increased (from 171.5 to 301.0 pg/mL) and cortisol suppression was observed (from 30.6 to 3.1 µg/dL), indicating the presence of a GC-mediated negative-feedback mechanism with a modestly higher threshold for ACTH secretion in this tumor.

A 3D culture experiment of ACTHoma from control patient 1 showed that ACTH levels in the media were suppressed by 10nM Dex 24 hours after treatment (21.5%, $P = 0.04$) (Fig. 4C). In control patient 2, ACTH levels were suppressed at 72 hours (50.0%, $P = 0.01$) (Fig. 4D).

These findings confirm not only the consistency between the clinical findings and ex vivo data but also that the GC-feedback mechanism is exerted in the adenoma itself.

Genetic analyses of well-known pathogenic genes related to ACTHomas were performed using adenoma tissues including *USP8*, *USP48*, and *BRAF*. In these gene analyses, no genetic variant was detected at the previously described hotspot region [15, 16].

Prevalence of CD with GC Positive Feedback

To investigate the prevalence of CD patients with paradoxical increases in ACTH secretion by Dex, we performed a retrospective multicenter analysis. Ninety-two patients with CD who underwent both LDDST and HDDST were included (Table 6). We found 8 patients (8.7%) who showed higher serum cortisol levels, both after LDDST (2.56-fold [1.06- to 4.89-fold]) and HDDST (1.52-fold [1.08- to 2.08-fold]), than the basal one. Next, clinical characteristics of these 8 patients; namely “Paradoxical rise”, were compared

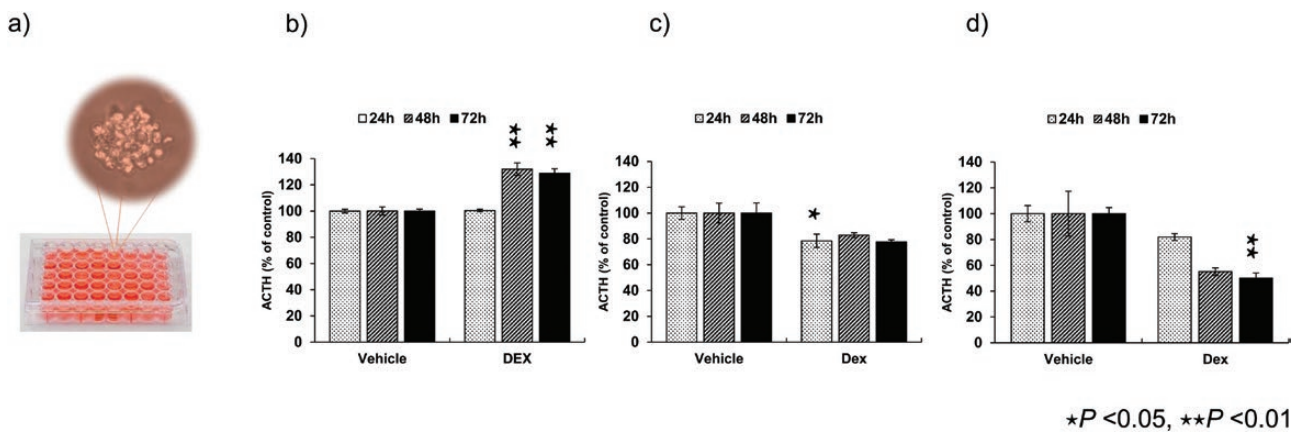


Figure 4. Patient-derived ACTHoma tumor spheroid; the 3D culture method. The resected ACTHoma was dispersed and embedded into Matrigel and placed in 48-well plates as 3D spheroids (8000 cells/well) (a). In this particular tumor, ACTH levels were elevated 48 and 72 hours after dexamethasone (Dex) treatment (b), while ACTH levels were reduced by Dex treatment from control patient 1 (c) and control patient 2 (d). Results are expressed as mean \pm standard error. * $P < 0.05$, ** $P < 0.01$.

Table 5. Laboratory data of control patients

		Basal cortisol	Cortisol after LDDST	Cortisol after HDDST
Control patient 1	($\mu\text{g/dL}$)	36.6	41.9	14.1
Control patient 2	($\mu\text{g/dL}$)	33.6	30.6	N/A

Abbreviations: HDDST, high-dose dexamethasone suppression test; LDDST, low-dose dexamethasone suppression test; N/A, not applicable.

Table 6. Clinical characteristics of the patients with Cushing disease

Characteristic	Median (range)
Sex, male/female	12 / 80
Age (years)	44 (15–87)
UFC ($\mu\text{g/day}$)	334 (36.5–2760)
ACTH (pg/mL)	61.8 (10.2–570.5)
Cortisol ($\mu\text{g/dL}$)	19.3 (5.4–54.8)
Tumor diameter (mm)	7 (1.8–36)

Abbreviations: ACTH, adrenocorticotropic hormone; UFC, urinary free cortisol.

to those with decrease of cortisol after LDDST and/or HDDST; namely “Decreased” (Table 7). In the Paradoxical rise group, both tumor diameter and Knosp grade was higher than the Decreased group (22 [5–35] vs 7 [1.8–36]; $P = 0.02$, $P < 0.01$), respectively. In contrast, sex, age, and hormonal levels did not differ between them.

Discussion

In this report, we present a case of CD due to an ACTH-secreting pituitary macroadenoma clearly showing a

Table 7. Clinical characteristics of CD patients with paradoxical cortisol increase both after LDDST and HDDST

	Paradoxical rise	Decreased	P value
Sex, male/female	1/7	11/73	0.96
Age (years)	60.5 [19–87]	42.5 [15–78]	0.17
Basal cortisol ($\mu\text{g/dL}$)	16.8 [5.4–25.9]	18.7 [8.4–54.8]	0.14
Cortisol after LDDST ($\mu\text{g/dL}$)	38.9 [22.5–84.0]	18.4 [3.5–43.0]	<0.01
Cortisol after HDDST ($\mu\text{g/dL}$)	28.5 [11.0–67.0]	4.5 [1.2–31.9]	<0.01
UFC ($\mu\text{g/day}$)	289 [54.5–2110]	338 [36.5–2760]	0.89
Tumor diameter (mm)	22 [5–35]	7 [1.8–36]	0.02
Knosp grade (0/1/2/3/4)	0/1/2/1/2	34/20/3/10/3	<0.01
MIB-1 index (%)	2.5 [0.1–25]	2.5 [0.1–20]	0.85

Paradoxical rise refers to patients with paradoxical rise of cortisol both after LDDST and HDDST; Decreased refers to patients with decreased cortisol after LDDST and/or HDDST.

Abbreviations: HDDST, high-dose dexamethasone suppression test; LDDST, low-dose dexamethasone suppression test; UFC, urinary free cortisol.

positive-feedback-regulated ACTH increase by Dex administration. This paradoxical ACTH response was confirmed by ex vivo studies of excised tumor 3D culture cells to be a direct effect of Dex on the tumor. Interestingly, this tumor exhibited shrinkage after 2 months of metyrapone administration. To the best of our knowledge, this is the first report to theoretically establish CD with a GC-driven positive feedback loop that further showed tumor shrinkage by enzymatic cortisol suppression.

Partial GC resistance to ACTH suppression is a characteristic feature in typical CD; therefore, LDDST and HDDST are widely used in the diagnosis of CD [1, 2]. In contrast, paradoxical ACTH and cortisol increases by Dex administration have been quite rare in patients with CD

[13, 18-22]. A GC-driven positive feedback loop has been reported in a few patients with cyclic CD [13, 22]. In these cases, endogenous or exogenous hypercortisolism has been proven to induce ACTH hypersecretion clinically, which might cause a cyclic CD-like behavior. However, the mechanisms remain unclear. On the other hand, more reports associated with paradoxical ACTH elevation after Dex administration have been reported in EAS, especially due to pheochromocytomas [4-12].

Metyrapone is an 11 β -hydroxylase inhibitor that blocks cortisol biosynthesis. In Cushing disease, metyrapone treatment generally causes ACTH elevation by interrupting the negative feedback of endogenous cortisol in pituitary tumors [23, 24]. However, in several cases, especially in those with EAS, plasma ACTH concentrations have been shown to be suppressed during metyrapone treatment; however, the direct inhibitory effect on ACTH has not been confirmed [5, 10, 25-28]. In many of these EAS cases, paradoxical increases of ACTH after Dex administration have been described, suggesting the presence of a GC positive feedback loop [4-12]. Consistent with these observations, our present CD case also exhibited decreased plasma ACTH levels after metyrapone treatment. Taken together with our case, these results support our hypothesis that metyrapone can successfully interrupt the GC-driven positive feedback loop in CD.

The most notable characteristic of the present case is the shrinkage of the ACTH-secreting macroadenoma after the initiation of metyrapone. The possibility of pituitary apoplexy needs to be excluded to determine whether the drug caused the tumor to shrink [29]. In this case, no changes related to hemorrhage or infarction were observed both in the MRI and from the pathological investigation of the tumor specimen. To our knowledge, only 1 case of EAS due to lung tumor has shown tumor shrinkage after the use of metyrapone with the suppression of ACTH, and no paradoxical reaction to GC was shown in this case [30]. Although the mechanism of tumor shrinkage in this case remains unclear, retraction of tumor size by reduced cortisol levels could be a plausible mechanism. In general, the effect of GC on tumor growth is bidirectional and is known to be tumor-specific [31]. Dex has been shown to suppress tumor growth by inhibiting tumor angiogenesis via vascular endothelial growth factor and interleukin-8 reduction [32] and by upregulating microRNA-708 expression resulting in reduced IKK β expression [33]. In contrast, Dex has been shown to promote tumor progression by modulating the following mechanisms: inhibition of p53-mediated apoptosis and activation of protein kinase B (Akt) and mitogen-activated protein kinase (MAPK) [31]. Further studies are needed to clarify the mechanism of metyrapone-induced tumor shrinkage, to determine whether it is mediated by

cortisol suppression or by other mechanisms. However, the tumor shrinkage effect of metyrapone not mediated by the cortisol inhibitory effect cannot be excluded. In this study, we used a 3D culture method for resected tumors. Recently, the 3D culture spheroid method, especially that using patient-derived tumor cell cultures, has been developed for studying cancer mechanisms and drug screening [34]. This system is thought to be closer to the real tumor environment than 2D cultures and is considered a better screening model to study drug effects [35, 36]. In fact, Dex treatment clearly proved that the adenoma in this case had a GC-induced ACTH positive feedback system, while the 2 control tumors had a partial negative feedback system. In the present experiments, we used 10nM concentration of Dex, which is compatible with the human serum concentration of Dex at 8 AM after 1-mg Dex midnight oral administration. Although a higher concentration of Dex (eg, 100nM) could be the better choice to prove the GC-induced paradoxical ACTH rise, we could see the significant difference between control tumors using 10nM Dex, indicating the sufficient data to show the positive feedback response to GC in this particular tumor. Several molecular mechanisms related to impaired GC negative feedback have been shown, including a high expression of 11 β -hydroxysteroid dehydrogenase-2 [37] and heat shock protein 90 [38], and a loss of nuclear Brg1 [39]. However, these hypotheses are not sufficient to explain the positive feedback response mediated by GC.

On the other hand, there are some hypotheses for the mechanisms by which GC might drive positive feedback on ACTH secretion in EAS caused by pheochromocytomas [4-12]. GC can enhance catecholamine secretion via the induction of tyrosine hydroxylase and/or phenylethanolamine N-methyltransferase synthesis, thereby stimulating ACTH secretion in situ [10]. A CpG island hypomethylation at the promoter region of proopiomelanocortin (*POMC*), a coding gene of the ACTH precursor, has been identified in the chromaffin tumor. Hypomethylation has been shown at the proximal E2F binding motif [10]. Furthermore, GC-dependent demethylation has been shown in ACTH-producing thymic carcinoids [40]. Additionally, GC-mediated suppression of DNA methyltransferase 1 has also been reported, suggesting that GC-mediated demethylation of the *POMC* promoter region can be an explanation for the GC-driven positive feedback loop. In fact, E2F has been shown to be a key mediator of ACTH hypersecretion not only in EAS [41], but also in CD [42]. However, demethylation of the *E2F* motif in *POMC* has not yet been elucidated in ACTHomas. In addition, a genetic variant analysis of this tumor suggested no involvement of already-known pathogenesis such as *USP8*,

USP48, and *BRAF* variants in our study. Further investigation is needed to elucidate the underlying mechanism of GC-mediated positive feedback, including the methylation status of the *POMC* promoter region in these ACTHomas.

In this study, we performed a retrospective multicenter analysis, showing that the prevalence of paradoxical rise both after LDDST and HDDST was 8.7%, which is more than expected. In these paradoxical rise subjects, tumor diameter was larger and MRI findings exhibited a more invasive than decreased group. These data support the previous reports that showing the recurrent rates is higher in cyclic Cushing disease [43].

In conclusion, we presented a case of CD that clearly showed GC-driven positive feedback, both clinically and experimentally. Intriguingly, tumor shrinkage in this case was seen during metyrapone treatment, suggesting GC positive feedback response not only to ACTH secretion but also to tumor proliferation. Further studies are needed to explore the detailed molecular mechanisms by which these tumors have GC-dependent tumor progression and ACTH production. Regarding the prevalence of ACTHoma with a GC positive feedback loop, our CD cohort study discovered it in 8.7% of the 92 patients with CD, which is not infrequent, thereby suggesting the presence of a new subtype of CD different from the majority of CD cases.

Acknowledgments

The authors thank Prof. Takashi Aoi for helping in the development of the 3D culture system. We also thank Ms. C. Ogata and Ms. A. Shitara for their excellent technical assistance. We appreciate the Director of the Department of Clinical Laboratory of the following institutes; Akita University Hospital, Kitazato University Hospital, Aomori Rosai Hospital, Fukushima Medical University Hospital, Gifu Prefectural Tajimi Hospital, Hamamatsu University Hospital, Hirosaki University Hospital, Hiroshima University Hospital, Hyogo Prefectural Kakogawa Medical Center, Iwate Prefectural Chuo Hospital, Japanese Red Cross Shizuoka Hospital, Jichi Medical University Hospital, Kawakita General Hospital, Kawasaki Medical School Hospital, Kindai University Hospital, Kochi Medical School Hospital, Kurashiki Central Hospital, Kyorin University Hospital, Nara Medical University Hospital, National Center for Global Health and Medicine, National Hospital Organization Kyoto Medical Center, Niigata Central Hospital, Noguchi Thyroid Clinic and Hospital Foundation, Oita University Hospital, Okayama University Hospital, Omagari Kousei Medical Center, Osaka City General Hospital, Osaka Saiseikai Nakatsu Hospital, Saiseikai Yokohamashi Tobu Hospital, Saitama Medical Center, Shizuoka General Hospital, Showa University Fujigaoka Hospital, St. Luke's International Hospital, St. Marianna University School of Medicine Hospital, The Jikei University Hospital, Tohoku University Hospital, Tokai University Hospital, Tokyo Medical University Hospital, Tokyo Women's Medical University Hospital

and University of the Ryukyus Hospital in presenting UFC measurement system information.

Financial Support: Grant-in-Aid for Scientific Research from the Japanese Ministry of Education, Culture, Sports, Science and Technology 15K09432 and 19K09003.

Additional Information

Correspondence: Hidenori Fukuoka MD, PhD., Division of Diabetes and Endocrinology, Kobe University Hospital, 7-5-2, Kusunoki-cho, Chuo-ku, Kobe 650-0017, Japan. Email: fukuokah@med.kobe-u.ac.jp.

Disclosures: The authors declare no conflicts of interest associated with this manuscript.

Data Availability: All data generated or analyzed during this study are included in this published article or in the data repositories listed in References.

References

- Melmed S. Pituitary-Tumor Endocrinopathies. *N Engl J Med*. 2020;382(10):937-950.
- Nieman LK, Biller BM, Findling JW, et al. The diagnosis of Cushing's syndrome: an Endocrine Society Clinical Practice Guideline. *J Clin Endocrinol Metab*. 2008;93(5):1526-1540.
- Gjerstad JK, Lightman SL, Spiga F. Role of glucocorticoid negative feedback in the regulation of HPA axis pulsatility. *Stress*. 2018;21(5):403-416.
- Forman BH, Marban E, Kayne RD, et al. Ectopic ACTH syndrome due to pheochromocytoma: case report and review of the literature. *Yale J Biol Med*. 1979;52(2):181-189.
- Terzolo M, Ali A, Pia A, et al. Cyclic Cushing's syndrome due to ectopic ACTH secretion by an adrenal pheochromocytoma. *J Endocrinol Invest*. 1994;17(11):869-874.
- Oh HC, Koh JM, Kim MS, et al. A case of ACTH-producing pheochromocytoma associated with pregnancy. *Endocr J*. 2003;50(6):739-744.
- Danilovic DL, Brandão Neto RA, D'Abronzio H, Menezes MR, Lucon AM, Mendonca BB. Ectopic ACTH syndrome caused by pheochromocytoma: computed tomography-guided percutaneous ethanol injection as an alternative treatment. *J Endocrinol Invest*. 2007;30(9):780-786.
- Brenner N, Kopetschke R, Ventz M, Strasburger CJ, Quinkler M, Gerl H. Cushing's syndrome due to ACTH-secreting pheochromocytoma. *Can J Urol*. 2008;15(1):3924-3927.
- Cassarino MF, Ambrogio AG, Pagliardini L, et al. ACTH-secreting pheochromocytoma with false-negative ACTH immunohistochemistry. *Endocr Pathol*. 2012;23(3):191-195.
- Sakuma I, Higuchi S, Fujimoto M, et al. Cushing syndrome due to ACTH-secreting pheochromocytoma, aggravated by glucocorticoid-driven positive-feedback loop. *J Clin Endocrinol Metab*. 2016;101(3):841-846.
- Falhammar H, Calissendorff J, Höybye C. Frequency of Cushing's syndrome due to ACTH-secreting adrenal medullary lesions: a retrospective study over 10 years from a single center. *Endocrine*. 2017;55(1):296-302.
- Inoue M, Okamura K, Kitaoka C, et al. Metyrapone-responsive ectopic ACTH-secreting pheochromocytoma with a vicious

- cycle via a glucocorticoid-driven positive-feedback mechanism. *Endocr J*. 2018;**65**(7):755-767.
13. Seki Y, Morimoto S, Saito F, et al. ACTH-dependent cyclic Cushing syndrome triggered by glucocorticoid excess through a positive-feedback mechanism. *J Clin Endocrinol Metab*. 2019;**104**(5):1788-1791.
 14. Kageyama K, Oki Y, Sakihara S, Nigawara T, Terui K, Suda T. Evaluation of the diagnostic criteria for Cushing's disease in Japan. *Endocr J*. 2013;**60**(2):127-135.
 15. Reincke M, Sbiha S, Hayakawa A, et al. Mutations in the deubiquitinase gene USP8 cause Cushing's disease. *Nat Genet*. 2015;**47**(1):31-38.
 16. Chen J, Jian X, Deng S, et al. Identification of recurrent USP48 and BRAF mutations in Cushing's disease. *Nat Commun*. 2018;**9**(1):3171.
 17. Parvin R, Saito-Hakoda A, Shimada H, et al. Role of NeuroD1 on the negative regulation of Pomc expression by glucocorticoid. *PLoS One*. 2017;**12**(4):e0175435.
 18. French FS, Macfie JA, Baggett B, Williams TF, Van Wyk JJ. Cushing's syndrome with a paradoxical response to dexamethasone. *Am J Med*. 1969;**47**(4):619-624.
 19. Ronald DB, Brown Ronald D, Van Loon GR, Orth DN, Liddle GW. Cushing's disease with periodic hormonogenesis: one explanation for paradoxical response to dexamethasone. *J Clin Endocrinol Metab*. 1973;**36**(3):445-451.
 20. Liberman B, Wajchenberg BL, Tambascia MA, Mesquita CH. Periodic remission in Cushing's disease with paradoxical dexamethasone response: an expression of periodic hormonogenesis. *J Clin Endocrinol Metab*. 1976;**43**(4):913-918.
 21. Kuchel O, Bolté E, Chrétien M, et al. Cyclical edema and hypokalemia due to occult episodic hypercorticism. *J Clin Endocrinol Metab*. 1987;**64**(1):170-174.
 22. Checchi S, Brilli L, Guarino E, et al. Cyclic Cushing's disease with paradoxical response to dexamethasone. *J Endocrinol Invest*. 2005;**28**(8):741-745.
 23. Nieman LK, Biller BM, Findling JW, et al.; Endocrine Society. Treatment of cushing's syndrome: an endocrine society clinical practice guideline. *J Clin Endocrinol Metab*. 2015;**100**(8):2807-2831.
 24. Verhelst JA, Trainer PJ, Howlett TA, et al. Short and long-term responses to metyrapone in the medical management of 91 patients with Cushing's syndrome. *Clin Endocrinol (Oxf)*. 1991;**35**(2):169-178.
 25. White A, Ray DW, Talbot A, Abraham P, Thody AJ, Bevan JS. Cushing's syndrome due to pheochromocytoma secreting the precursors of adrenocorticotropin. *J Clin Endocrinol Metab*. 2000;**85**(12):4771-4775.
 26. Schönesöfer M, Fenner A, Claus M. Suppressing effect of metyrapone on plasma corticotrophin immunoreactivity in normal man. *Clin Endocrinol (Oxf)*. 1983;**18**(4):363-370.
 27. van Dam PS, van Gils A, Canninga-van Dijk MR, de Koning EJ, Hofland LJ, de Herder WW. Sequential ACTH and catecholamine secretion in a pheochromocytoma. *Eur J Endocrinol*. 2002;**147**(2):201-206.
 28. Fukasawa M, Sawada N, Miyamoto T, et al. Laparoscopic unilateral total and contralateral subtotal adrenalectomy for bilateral adrenocorticotrophic hormone-secreting pheochromocytoma: report of a rare case. *J Endourol Case Rep*. 2016;**2**(1):232-234.
 29. Loh KC, Gupta R, Shlossberg AH. Spontaneous remission of ectopic Cushing's syndrome due to pheochromocytoma: a case report. *Eur J Endocrinol*. 1996;**135**(4):440-443.
 30. Iwayama H, Hirase S, Nomura Y, et al. Spontaneous adrenocorticotrophic hormone (ACTH) normalisation due to tumour regression induced by metyrapone in a patient with ectopic ACTH syndrome: case report and literature review. *BMC Endocr Disord*. 2018;**18**(1):19.
 31. Ayroldi E, Cannarile L, Delfino DV, Riccardi C. A dual role for glucocorticoid-induced leucine zipper in glucocorticoid function: tumor growth promotion or suppression? *Cell Death Dis*. 2018;**9**(5):463.
 32. Yano A, Fujii Y, Iwai A, Kageyama Y, Kihara K. Glucocorticoids suppress tumor angiogenesis and in vivo growth of prostate cancer cells. *Clin Cancer Res*. 2006;**12**(10):3003-3009.
 33. Lin KT, Sun SP, Wu JL, Wang LH. Low-dose glucocorticoids suppresses ovarian tumor growth and metastasis in an immunocompetent syngeneic mouse model. *PLoS One*. 2017;**12**(6):e0178937.
 34. Shinozawa T, Yoshikawa HY, Takebe T. Reverse engineering liver buds through self-driven condensation and organization towards medical application. *Dev Biol*. 2016;**420**(2):221-229.
 35. Takebe T, Zhang B, Radisic M. Synergistic engineering: organoids meet organs-on-a-chip. *Cell Stem Cell*. 2017;**21**(3):297-300.
 36. Tuveson D, Clevers H. Cancer modeling meets human organoid technology. *Science*. 2019;**364**(6444):952-955.
 37. Korbonits M, Bujalska I, Shimojo M, et al. Expression of 11 beta-hydroxysteroid dehydrogenase isoenzymes in the human pituitary: induction of the type 2 enzyme in corticotropinomas and other pituitary tumors. *J Clin Endocrinol Metab*. 2001;**86**(6):2728-2733.
 38. Riebold M, Kozany C, Freiburger L, et al. A C-terminal HSP90 inhibitor restores glucocorticoid sensitivity and relieves a mouse allograft model of Cushing disease. *Nat Med*. 2015;**21**(3):276-280.
 39. Bilodeau S, Vallette-Kasic S, Gauthier Y, et al. Role of Brg1 and HDAC2 in GR trans-repression of the pituitary POMC gene and misexpression in Cushing disease. *Genes Dev*. 2006;**20**(20):2871-2886.
 40. Mizoguchi Y, Kajiume T, Miyagawa S, Okada S, Nishi Y, Kobayashi M. Steroid-dependent ACTH-produced thymic carcinoid: regulation of POMC gene expression by cortisol via methylation of its promoter region. *Horm Res*. 2007;**67**(5):257-262.
 41. Araki T, Liu NA, Tone Y, et al. E2F1-mediated human POMC expression in ectopic Cushing's syndrome. *Endocr Relat Cancer*. 2016;**23**(11):857-870.
 42. Araki T, Liu X, Kameda H, et al. EGFR induces E2F1-mediated corticotroph tumorigenesis. *J Endocr Soc*. 2017;**1**(2):127-143.
 43. Meinardi JR, Wolffenbuttel BH, Dullaart RP. Cyclic Cushing's syndrome: a clinical challenge. *Eur J Endocrinol*. 2007;**157**(3):245-254.