Kobe University Repository : Kernel

PDF issue: 2025-12-04

A new clinical classification and reconstructive strategy for post-sternotomy surgical site infection

Kitano, Daiki ; Takahashi, Hiroaki ; Nomura, Tadashi ; Okada, Kenji ; Terashi, Hiroto ; Sakakibara, Shunsuke

(Citation)
Regenerative Therapy,21:519-526

(Issue Date)
2022-12

(Resource Type)
journal article

(Version)
Version of Record

(Rights)
© 2022 The Japanese Society for Regenerative Medicine. Production and hosting by Elsevier B.V.
This is an open access article under the CC BY-NC-ND license (http://creativecommons.org/licenses/by-nc-nd/4.0/).

(URL)
https://hdl.handle.net/20.500.14094/0100477598

Regenerative Therapy 21 (2022) 519–526

Contents lists available at ScienceDirect

Regenerative Therapy

journal homepage: http://www.elsevier.com/locate/reth

Original Article

A new clinical classification and reconstructive strategy for post-sternotomy surgical site infection

Daiki Kitano [a, *], Hiroaki Takahashi [b], Tadashi Nomura [a], Kenji Okada [b], Hiroto Terashi [a], Shunsuke Sakakibara [a]

[a] Department of Plastic Surgery, Kobe University Graduate School of Medicine, Kobe, Japan
[b] Department of Cardiovascular Surgery, Kobe University Graduate School of Medicine, Kobe, Japan

ARTICLE INFO

Article history:
Received 4 September 2022
Received in revised form
7 October 2022
Accepted 15 October 2022

Keywords:
Surgical site infection
Cardiovascular surgery
Mediastinitis
Classification

ABSTRACT

Introduction: Post-sternotomy surgical site infection (SSI) is a serious complication of cardiovascular surgery. Here, we proposed a new clinical classification and reconstructive strategy for this condition.
Methods: A retrospective study based on medical records was performed on 100 consecutive cases requiring wound management by plastic surgeons for post-sternotomy SSI at Kobe University Hospital between January 2009 and December 2021. We classified 100 cases into four categories according to the anatomical invasiveness of the infection (type 1, superficial SSI; type 2, sternal osteomyelitis; type 3, mediastinitis; and type 4, aortic graft infection). The standard treatment plan comprised initial debridement, negative pressure wound therapy with continuous irrigation, and reconstructive surgery. Reconstructive methods and their outcomes (in-hospital mortality rate, follow-up period, and infection recurrence rate) were investigated for each SSI category.
Results: There were nine SSI cases in type 1, 28 in type 2, 25 in type 3, and 38 in type 4. The pectoralis major (PM) muscle advancement flap was mainly selected in types 1 and 2 (100 and 70.4%, respectively), while the omental flap or latissimus dorsi (LD) myocutaneous flaps were mainly selected in types 3 and 4 (77.3 and 81.8%, respectively) for reconstructive surgery. The in-hospital mortality rates for types 1, 2, 3, 4 were 44.4, 3.6, 12.0, and 15.8%, respectively. The mean follow-up periods for types 1, 2, 3, 4 were 542.8, 1514.5, 1154.5, and 831.1 days, respectively. Infection recurrence rates for types 1, 2, 3, 4 were 0, 11.5, 13.3, and 19.2%, respectively. All of these recurrent cases, except for 4 cases of type 4 that required surgical intervention, were treated with conservative wound management.
Conclusion: A volume-rich flap (omental or LD flap) was required to fill the dead space after debridement in mediastinitis (type 3) or aortic graft infection (type 4), whereas superficial SSI (type 1) or sternal osteomyelitis (type 2) received a less-invasive flap (PM muscle advancement flap). Our new classification method was based on the anatomical invasiveness of the infection, providing both a simple and easy diagnosis and definitive treatment strategy.
© 2022, The Japanese Society for Regenerative Medicine. Production and hosting by Elsevier B.V. This is an open access article under the CC BY-NC-ND license (http://creativecommons.org/licenses/by-nc-nd/4.0/).

1. Introduction

Surgical site infection (SSI) is one of the complications associated with an increase in postoperative mortality and health-care costs [1]. SSI incidence correlats with intra-operative wound contamination [2]. Preoperative bathing or showering of the surgical site, sterilization of the surgical field with an aseptic solution, and wound lavage before wound closure are encouraged to reduce wound contamination risk during surgery. However, it is almost impossible to obtain a completely sterilized surgical wound immediately after surgery, because wound contamination during the operative procedure is almost inevitable [3]. The inoculated bacteria grow within the surgical wound and develop SSI at a certain rate. While the infection is usually localized in the superficial layer of the closed wound, a deep-layer wound infection, osteomyelitis, or peri-organ space infection were encountered in some cases [4].

Abbreviations: AGI, aortic graft infection; CT, computed tomography; LD, latissimus dorsi; NPWTci, negative-pressure wound therapy with continuous irrigation; PM, pectoralis major; SSI, surgical site infection.

* Corresponding author. Department of Plastic Surgery, Kobe University Graduate School of Medicine, 7-5-2, Kusunoki-cho, Chuo-ku, Kobe 650-0017, Japan.
E-mail address: dkitano.kobe.prs@gmail.com (D. Kitano).

Peer review under responsibility of the Japanese Society for Regenerative Medicine.

https://doi.org/10.1016/j.reth.2022.10.007
2352-3204/© 2022, The Japanese Society for Regenerative Medicine. Production and hosting by Elsevier B.V. This is an open access article under the CC BY-NC-ND license (http://creativecommons.org/licenses/by-nc-nd/4.0/).

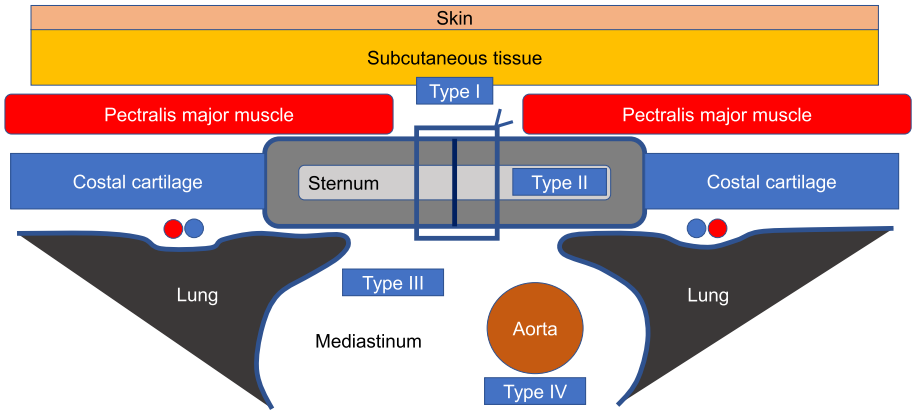

Fig. 1. Our classification of post-sternotomy SSI. We classified post-sternotomy SSI cases into four categories according to the anatomical invasiveness of the infection. Type 1, superficial SSI; type 2, sternal osteomyelitis; type 3, mediastinitis; and type 4, AGI. Abbreviations: AGI, aortic graft infection; SSI, surgical site infection

Fig. 2. Type 1: superficial SSI. (a) A 70-year-old man after total arch replacement for aortic dissection presented with fever and wound discharge. (b), (c) Subcutaneous abscess was confirmed, but there was no sternal instability. (d), (e), (f) The wound was reconstructed with the PM muscle advancement flap after NPWTci. (g), (h) CT before and after reconstruction. Abbreviations: AGI, aortic graft infection; CT, computed tomography; NPWTci, negative-pressure wound therapy with continuous irrigation; PM, pectoralis major; SSI, surgical site infection.

Post-sternotomy SSI occurred in 1–7% of cardiovascular surgery [5]. Mediastinitis is a deep-layer SSI, which is associated with a devastating clinical course. The in-hospital mortality rate of mediastinitis was approximately 10% [6], and the involvement of aortic graft infection (AGI) worsens this grave condition. In 1999, Coselli et al. reported that the mortality rate of AGI cases receiving in-situ graft replacement surgery was as high as 42% [7]. Various surgical techniques have been developed to avoid in-situ replacement. Among these, extra-anatomical bypass grafting is a representative operation aiming to avoid re-infection of the graft [8]. However, even with this challenging surgical approach, no significant reduction in AGI mortality rate has been achieved [9].

Several classifications have been proposed for post-sternotomy SSI [10–15]. The majority of these classifications were based on the clinical course of patients, onset of SSI [10,11,13] or general condition [11,12]. In other words, they did not provide any constructive suggestions for the diagnosis and treatment plan for each patient. Although van Wingerden et al. reported a treatment strategy using clinical classification that was based on the anatomical invasiveness of the infection, AGI was not mentioned [14]. Here, we advocated a new clinical classification of post-sternotomy SSI based on the anatomical invasiveness of the infection and discuss the strategy of reconstructive surgery and its outcome.

2. Methods

2.1. Patients

One hundred consecutive patients with post-sternotomy SSI, who received surgical intervention between January 2009 and December 2021, were included in this study. All SSI cases (including suspected SSI) were referred to the department of plastic surgery. They were classified into four categories according to the anatomical invasiveness of the infection. Based on medical records, we performed a retrospective study of the reconstructive method and its outcome.

Fig. 3. Type 2: sternal osteomyelitis. (a) A 82-year-old man after aortic valve replacement presented with fever and wound discharge. (b), (c) The exposed sternal wire and necrotic bone were removed. (d), (e) Favorable granulation tissue was formed after NPWTci. (f) The bone defect was filled with the PM muscle advancement flap. (g), (h) CT before and after reconstruction. The PM muscle was placed within the bone defect (arrow). Abbreviations: CT, computed tomography; NPWTci, negative-pressure wound therapy with continuous irrigation; PM, pectoralis major.

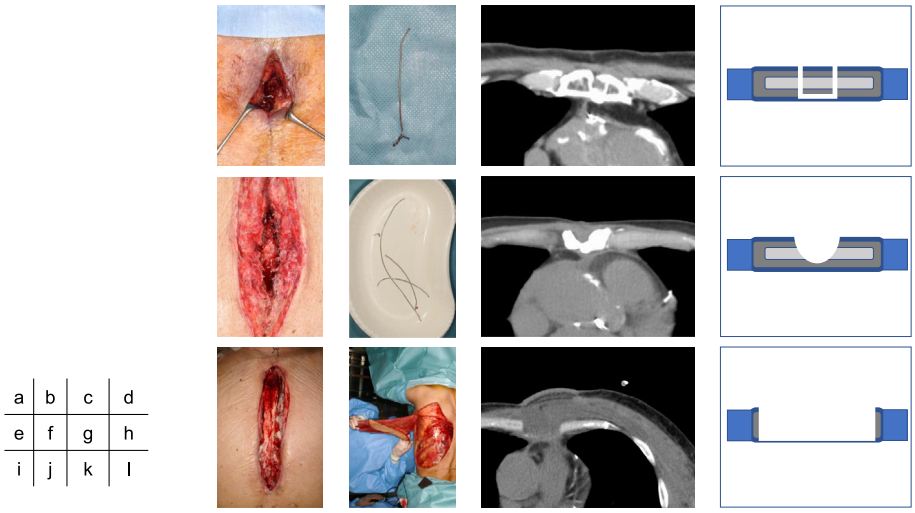

Fig. 4. Subtypes of sternal osteomyelitis. (a) Type 2-a: wire-hole infection. (b) Wire removal and curettage of wire-hole. (c), (d) Postoperative CT and schema. The wire-hole tissue was calcified. (e) Type 2-b: partial sternal osteomyelitis. (f) The infection spread along the wire-hole. The anterior plate and bone marrow were destructed, but the posterior plate was intact. (g), (h) Postoperative CT and schema. The debrided sternal cavity was filled with PM muscle advancement flap. (i) Type 2-c: total sternal osteomyelitis. The infection extended to the posterior plate, but the mediastinum was intact. Granulation tissue was formed on the preserved periosteum. (j) The defect was reconstructed with LD myocutaneous flap (k), (l) Postoperative CT and schema. The sternum was totally removed. Abbreviations: CT, computed tomography; LD, latissimus dorsi; PM, pectoralis major.

2.2. Definition of post-sternotomy SSI

Our diagnostic criteria for post-sternotomy SSI were based on the definitions of post-sternotomy mediastinitis presented by the Center for Disease Control [16], the presence of clinical symptoms (e.g., fever, chest pain, and wound discharge), positive wound culture, or imaging study findings (e.g., subcutaneous abscess).

2.3. Classification

The infectious wound was examined in an operating room under general anesthesia. Necrotic tissue was debrided until viable tissue was confirmed. Wounds were classified into four categories according to the anatomical invasiveness of the infection (Fig. 1). Negative pressure wound therapy with continuous irrigation (NPWTci) [17] was applied to the debrided wound until favorable wound bed preparation was achieved.

2.3.1. Type 1: superficial SSI

The infection was confined to subcutaneous tissue and did not extend into the sternum (Fig. 2). There was no sternal dehiscence, usually accompanied by a clinical finding of periosteal union. Clinical signs of infection (e.g., fever and wound discharge) usually appeared in the first 2 weeks. Type 1 patients tended to have some unique predisposing factors for delayed wound healing, such as unstable postoperative hemodynamics or poor nutritional status. While the amelioration of these factors could promote wound

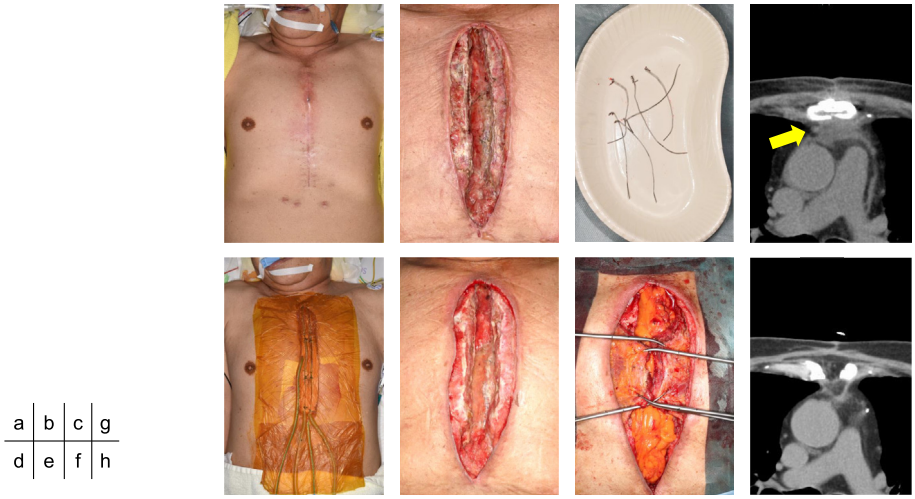

Fig. 5. Type 3: mediastinitis. (a) A 74-year-old man after coronary artery bypass grafting presented with sepsis and subcutaneous swelling. (b) Purulent discharge was accumulated in the mediastinum. (c) The wire-cutting through the sternum was confirmed. (d), (e) Wound bed preparation was achieved by NPWTci. (f) The mediastinum was reconstructed with the omental flap. (g), (h) CT before and after reconstruction. The retrosternal abscess (arrow) was debrided. The defect was filled with the omental flap. Abbreviations: CT, computed tomography; NPWTci, negative-pressure wound therapy with continuous irrigation.

Fig. 6. Type 4: AGI. (a) A 78-year-old man after total arch replacement for arch aortic dissection presented with sepsis and wound discharge. (b) The aortic graft was exposed after re-sternotomy. (c) The wire and necrotic bone were removed. (d), (e) The wound was managed by NPWTci. (f) The omental flap was placed into the mediastinum so as to fill the dead space around the graft. (g), (h) CT before and after reconstruction. The abscess around the graft was removed. The perivascular space was filled with the omental flap. Abbreviations: AGI, aortic graft infection; CT, computed tomography; NPWTci, negative-pressure wound therapy with continuous irrigation.

healing, many patients died from the despairing general condition before reconstructive surgery.

2.3.2. *Type 2: sternal osteomyelitis*

The infection involved the sternum, but did not extend into the mediastinum (Fig. 3). Necrotic sternum was often accompanied by wire-cutting through the cortical bone. Meticulous debridement and curettage of the necrotic bone marrow, following reconstruction with well-vascularized soft tissue, were required to repress the infection and prevent recurrence.

The sternum consists of the anterior plate, bone marrow, and posterior plate. The three-layer structure resembles a “wafer”. The sternal osteomyelitis could be classified into three subtypes, depending on the depth of infection (Fig. 4). Type 2-a was a wire-hole infection spreading along the sternal fixation wire. However, it was confined to the wire-hole area. Wire extraction and debridement led to wound healing with secondary intention. Type 2-b was partial sternal osteomyelitis, in which the infection spread to the anterior plate and bone marrow but the posterior plate was intact. Curettage of the infected bone marrow and flap coverage were optimal treatments. Type 2-c was total sternal osteomyelitis, in which all three layers were completely destroyed, but the periosteum of the posterior plate was intact. The infection did not extend to the mediastinum. Total resection of the sternum was inevitable. However, if the periosteum was preserved, granulation tissue was formed.

2.3.3. *Type 3: mediastinitis*

The infection extended into the mediastinum (Fig. 5) and was often associated with severe systemic infections (e.g., sepsis). While it was usually concurrent with sternal osteomyelitis, rare case presented as a mediastinitis alone. Involvement of the heart or great vessels could cause fatal bleeding events. Immediate surgical debridement and reconstruction with a well-vascularized

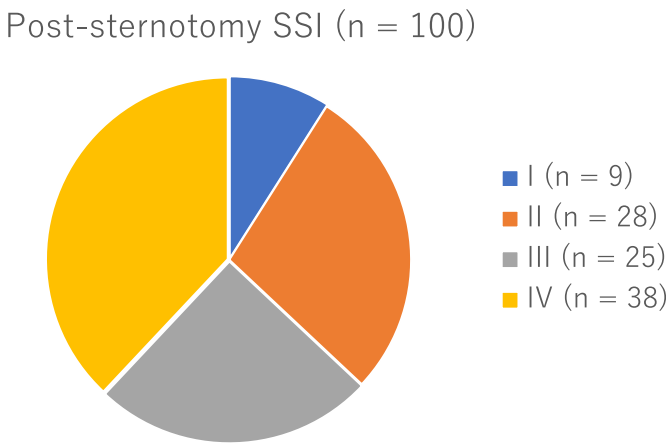

Fig. 7. Case and classification. Abbreviations: SSI, surgical site information.

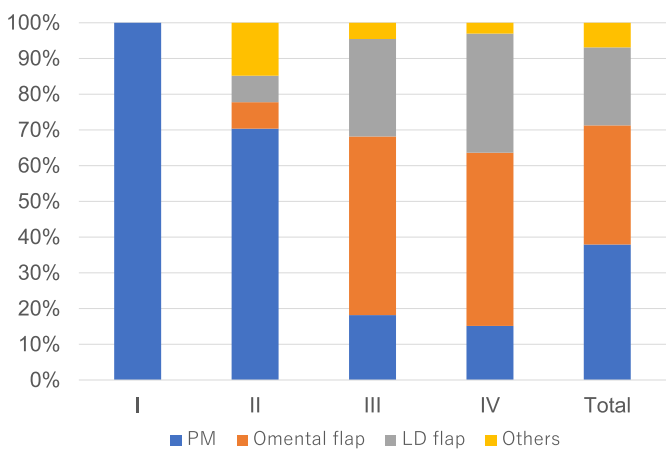

Fig. 8. Reconstructive method. Abbreviations: LD, latissimus dorsi; PM, pectoralis major.

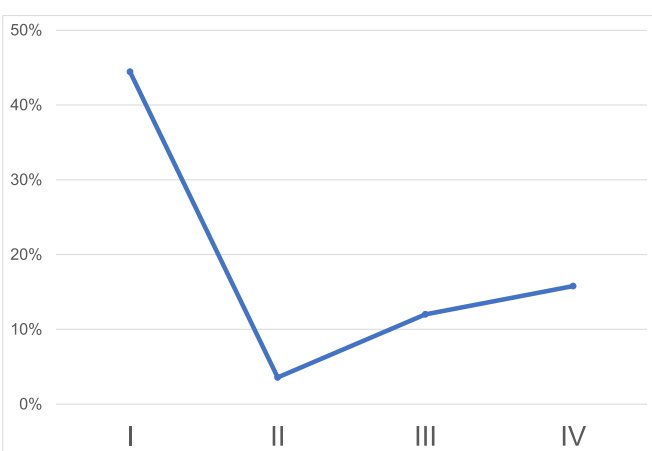

Fig. 9. In-hospital mortality rate.

flap (e.g., omental or latissimus dorsi [LD]) were essential to control infection and save the patient's life.

2.3.4. Type 4: AGI

AGI is referred to as mediastinitis with prosthetic graft infection after aortic arch replacement for aortic dissection or aneurysm (Fig. 6).

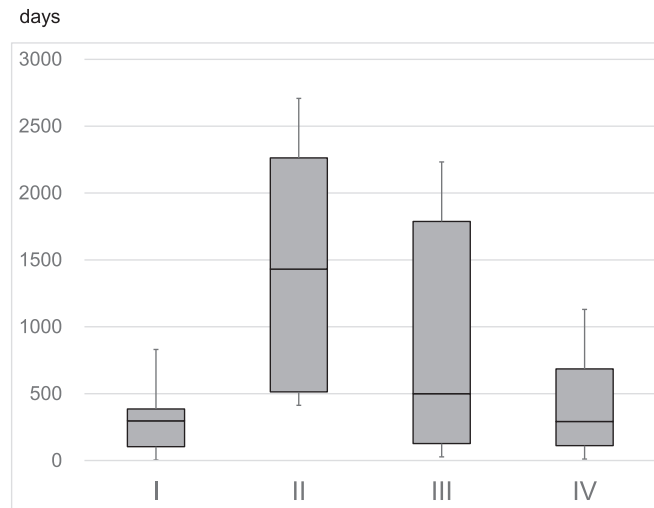

Fig. 10. Mean postoperative follow-up period.

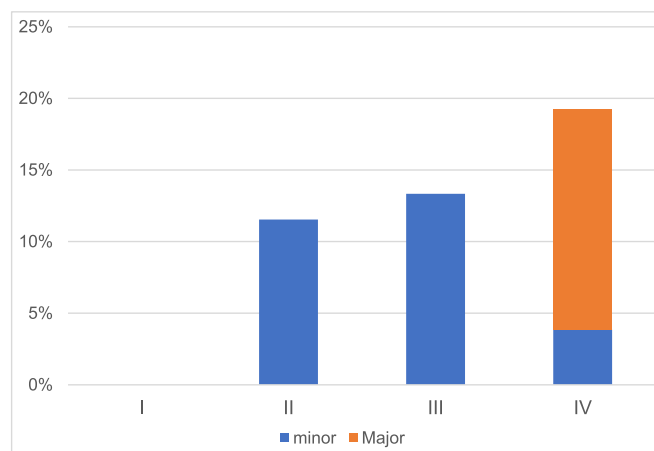

Fig. 11. Infection recurrence rate. The major recurrence was referred as serious case which required surgical intervention, while the minor recurrence received conservative treatment.

Prosthetic graft exposure exacerbated wound healing because it did not have any anti-microbial activity. The infected graft was preferred to be replaced with a new graft; however, the re-replacement surgery was associated with a high-mortality rate [7]. We have reported the combination method of NPWTci and omental flap reconstruction to avoid re-replacement surgery in AGI [17]. However, in some cases, the infection recurrence was inevitable (Type 4-r).

2.4. Primary outcome

For each patient, the treatment plans were discussed by a clinical conference of cardiovascular surgeons with plastic surgeons. However, the final decision was made according to the operative findings. We investigated the reconstructive method (e.g., pectoralis major [PM], omental, or LD flap) performed after wound bed preparation. We also determined whether there was a relationship between the classification and reconstructive methods.

2.5. Secondary outcomes

Clinical outcomes (in-hospital mortality rate, postoperative follow-up, and infection recurrence rate) were investigated. The

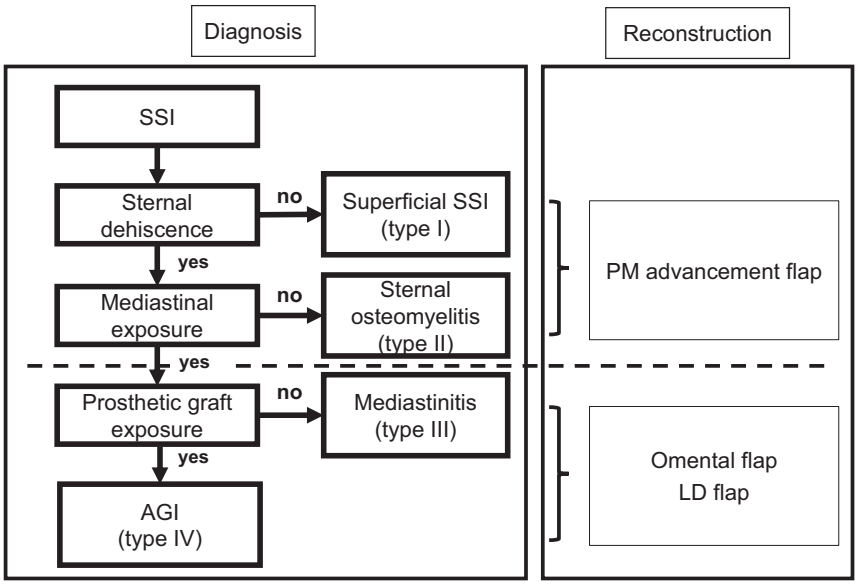

Fig. 12. Our diagnostic and reconstructive algorithm. Abbreviations: AGI, aortic graft information; LD, latissimus dorsi; PM, pectoralis major; SSI, surgical site infection.

postoperative follow-up period was defined as the period between the reconstructive surgery and last visit. Infection recurrence was classified into two types: major recurrence (required surgical intervention for treatment) and minor recurrence (cured by conservative treatment without surgery).

2.6. Statistical analysis

Cochran-Armitage and Jonkheer-Terpstra trend tests were performed to determine if there was a relationship between the classification and clinical outcomes by using EZR [18]. Difference with a p-value < 0.05 was defined as statistically significant.

3. Results

3.1. Patient characteristics

A total of 100 patients (74 men and 26 women) with a mean age of 69.6 years, were classified into four categories. The numbers of patients with types 1, 2, 3, and 4 were 9, 28, 25, and 38, respectively (Fig. 7).

3.2. Primary outcome

Among 100 patients with SSI, 87 underwent reconstructive surgery. The PM muscle advancement flap was selected in 33 patients (37.9%), omental flap in 29 (33.3%), LD flap in 19 (21.9%), and other flaps in six (6.9%). The PM advancement flap was selected in five patients with type 1 (100%), 19 out of 27 patients with type 2 (70.4%), four out of 22 patients with type 3 (18.2%), and five out of 33 patients with type 4 (15.2%). In contrast, omental or LD flaps were selected in none of the patients with type 1 (0%), four out of 27 patients with type 2 (14.8%), 17 out of 22 patients with type 3 (77.3%), and 27 out of 33 patients with type 4 (81.8%). Types 1 and 2 were predisposed to be closed with a less-invasive (PM muscle advancement) flap, whereas types 3 and 4 were volume-rich (omental or LD) flaps (Fig. 8). The Cochran-Armitage trending test showed a very strong correlation between the classification and reconstructive methods ($p = 4.52 \times 10^{-7}$).

3.3. Secondary outcome

Of the 100 patients, 14 died in the hospital. The in-hospital mortality rates for type 1, 2, 3, and 4 were 44.4, 3.6, 12.0, and 15.8%, respectively (Fig. 9). The Cochran-Armitage trend test found no statistical correlation between the classification and in-hospital mortality rate for types 1 to 4 ($p = 0.94$), whereas a significant correlation was found among types 2, 3, and 4 ($p = 0.04$).

The mean follow-up periods for types 1, 2, 3, and 4 were 542.8, 1514.5, 1154.5, and 831.1 days, and the medians were 296.5, 1431.0, 499.5, and 292.0 days, respectively (Fig. 10). The Jonckheere-Terpstra trend test did not show a correlation between the classification and follow-up period for types 1 to 4 ($p = 0.10$), while there was a significant correlation among types 2, 3, and 4 ($p = 0.01$).

Of the 71 patients who were followed-up for more than 6 months after reconstruction, 10 (14.1%) had recurrence of infection. Six patients were treated with conservative wound care (minor recurrence), while four patients required surgical intervention (major recurrence). Minor recurrence was confirmed in three patients with type 2, two with type 3, and one with type 4, while major recurrence was detected in four patients with type 4. All major recurrence cases received debridement, NPWTci, and reconstructive procedure in the operation room. The incidence rates of infection recurrence for types 1, 2, 3, and 4 were 0.0, 11.5, 13.3, and 19.2%, respectively (Fig. 11). The Cochran-Armitage trend test did not demonstrate a correlation between classification and infection recurrence ($p = 0.30$).

4. Discussion

Post-sternotomy SSI is a serious postoperative complication that affects patient prognosis. Collaboration between well-trained cardiovascular and reconstructive surgeons is necessary for successful surgical management. One of the most important missions is to clarify the treatment plan and instruct the team members. An optimal outcome will not be achieved unless the team does not move towards the same goal. Therefore, there is a need to establish a basic treatment strategy for post-sternotomy SSI.

Several researchers have reported some classifications of post-sternotomy SSI [10–15]. However, the majority of these classifications were based on clinical information (e.g., onset of symptoms) and were less associated with the diagnosis or treatment strategy. Our classification was based on the anatomical invasiveness of the infection. Therefore, it was simple and easy to understand, even for inexperienced team members. We expect that our classification will be utilized for sharing treatment plans with team members and facilitating constructive discussions.

Our study demonstrated a strong correlation between the classification and reconstructive methods. Superficial SSI (type 1) or sternal osteomyelitis (type 2) was managed with a less-invasive (PM muscle advancement) flap, whereas mediastinitis (type 3) or AGI (type 4) required a volume-rich (omental or LD) flap to fill the dead space (Fig. 12). This trend could be explained by the defect size arising after debridement; as the infection became deeper, the defect size became lager. In other words, a large flap was not always necessary if the defect was confined to the superficial area. We traditionally selected a volume-rich flap (e.g., omental flap or LD flap) for the reconstruction of type 2 (sternal osteomyelitis) cases. However, now we found that PM advancement flap provided sufficient results in type 2 cases. Our classification system could provide a precise diagnosis and contribute to revise the treatment plans so that we could avoid unnecessary invasive procedures.

The prognosis of patients with post-sternotomy SSI worsened in the order of classification number, suggesting that more serious consequences (e.g., great vessel rupture) would be expected as the infection involved deeper areas. Superficial SSI (type 1) was associated with a high mortality rate, presumably due to the common presentation of an extremely poor general condition status after cardiovascular surgery in patients with type 1, causing inadequate perfusion in the surgical wound. Consequently, the subcutaneous tissue was necrotic.

As a strategy for AGI (type 4), maximum efforts were provided to avoid the removal of infected grafts and redo-replacement surgery (graft-preservation approach). Meticulous debridement concomitant with NPWTci and timely reconstructive surgery were essential to achieve favorable outcomes. While the omental flap was our first-choice, the LD flap was selected for patients with a history of laparotomy. We previously reported that the graft-preservation approach could prevent both redo-replacement surgery and infection recurrence [18].

However, we need to be aware of the potential infection recurrence risk in the graft-preservation approach. It was difficult to perform wound cleansing in the deep-sternal area, which particularly involved the descending aorta. Additionally, it was difficult to cover the descending aorta with well-vascularized tissue because the arc of rotation of the flap was limited (e.g., the omental or LD flap could not reach the descending aorta). As such, there have been several cases of infection recurrence in AGI (type 4-r). We considered redo-replacement of the infected graft for AGI recurrence. We have advocated the versatility of trans-thoracic LD muscle flap reconstruction using the anterolateral partial sternotomy approach [19]; this method was useful for the treatment of recurrent AGI cases that involved the descending aorta.

Our classification was based on the basic principle of SSI development. In this regard, it was assumed that the bacteria invaded the wound surface and spread to deeper areas. In other words, if the infection was confined to the sternum or a more superficial area, the mediastinum was considered intact. However, we sometimes encountered some exceptional cases, in which late-onset mediastinitis developed even after the subcutaneous tissue or sternum was completely fused. We reported a case of mediastinitis with hematogenous metastasis of infection [20] or dissemination from a tracheostomy hole [21]. These mediastinitis cases were characterized by non-malunion of the sternum. Careful attention should be paid to cases of superficial or sternal osteomyelitis if the clinical course after debridement is undesirable, and re-sternotomy should not be performed to confirm the mediastinal condition. We hope that our classification and strategy will facilitate appropriate decision-making for the treatment of post-sternotomy SSI and offer an opportunity to address further discussion in the future.

5. Conclusion

We advocate a new clinical classification and reconstructive strategy for post-sternotomy SSI. Our classification system consisted of four categories according to the anatomical invasiveness of the infection. There was a strong correlation between the classification and reconstructive methods. We must be aware of potential exceptional cases of late-onset mediastinitis. Further research is warranted to investigate the treatment of post-sternotomy SSI.

Authors' contributions

All authors were involved in the operative procedures. Daiki KitanoShunsuke SakakibaraHiroaki TakahashiTadashi NomuraKenji OkadaHiroto Terashi

Conflict of Interest

None.

Ethical approval

This study was approved by the ethics committee of Kobe University Hospital (No. B220041).

References

[1] Berrios-Torress SI, Umscheid CA, Bratzler DW, Leas B, Stone EC, Kelz RR, et al. Centers for disease control and prevention guideline for the prevention of surgical site infection. JAMA Surg 2017;152(8):784–91.
[2] Sainz de la Cuesta R, Mohedano R, Sainz de la Cuesta S, Guzma B, Serrera A, Paulos S, et al. Intraoperative subcutaneous culture as a predictor of surgical site infection in open gynecological surgery. PLoS One 2021;16(1):e0244551.
[3] Kuhme T, Isaksson B, Dahlin LG. Wound contamination in cardiac surgery: a systematic quantitative and qualitative study of the bacterial growth in sternal wounds in cardiac surgery patients. APMIS 2007;115(9):1001–7.
[4] Surgical Site Infection (SSI) Events – January 2022. Centers for Disease Control and Prevention (CDC). https://www.cdc.gov/nhsn/pdfs/pscmanual/9pscssicurrent.pdf (accessed 2022-3-8).
[5] Bustamante-Munguira J, Herrera-Gómez F, Ruiz-Álvarez M, Figuerola-Tejerina A, Hernández-Aceituno A. A new surgical site infection risk score: infection risk index in cardiac surgery. J Clin Med 2019;8(4):480.
[6] Goh SSC. Post-sternotomy mediastinitis in the modern era. J Card Surg 2017;32(9):556–66.
[7] Coselli JS, Köksoy C, LeMaire SA. Management of thoracic aortic graft infections. Ann Thorac Surg 1999;67(6):1990–8.
[8] Kitano D, Matsuo J, Sakakibara S, Oomura A, Osaki T, Okada K, et al. Extra-anatomical bypass grafting and latissimus dorsi myocutaneous flap reconstruction for post-sternotomy mediastinitis with prosthetic aortic graft infection. Cureus. 13(9): e18086. doi:10.7759/cureus.18086.
[9] Bianco V, Kilic A, Gleason TG, Arnaoutakis GJ, Sultan I. Management of thoracic aortic graft infections. J Card Surg 2018;33(10):658–65.
[10] Pairolero PC, Arnold PG. Management of infected median sternotomy wounds. Ann Thorac Surg 1986;42(1):1–2.
[11] El Oakley RM, Wright JE. Postoperative mediastinitis: classification and management. Ann Thorac Surg 1996;61(3):1030–6.
[12] Jones G, Jurkiewicz MJ, Bostwicket J, Wood R, Bried JT, Culbertson J, et al. Management of the infected median sternotomy wound with muscle flaps. The Emory 20-year experience. Ann Surg 1997;225(6):766–76. ; discussion 776-8.
[13] Mekontso Dessap A, Vivier E, Girou E, Brun-Buisson C, Kirsch M. Effect of time to onset on clinical features and prognosis of post-sternotomy mediastinitis. Clin Microbiol Infect 2011;17(2):292–9.
[14] van Wingerden JJ, Ubbink DT, van der Horst CM, de Mol BA. Poststernotomy mediastinitis: a classification to initiate and evaluate reconstructive management based on evidence from a structured review. J Cardiothorac Surg 2014;19:179.

[15] Anger J, Dantas DC, Arnoni RT, Farsky PS. A new classification of post-sternotomy dehiscence. Rev Bras Cir Cardiovasc 2015;30(1):114–8.
[16] CDC/NHSN Surveillance Definition of Specific Types of Infections – January 2022. Centers for Disease Control and Prevention (CDC). https://www.cdc.gov/nhsn/pdfs/pscmanual/17pscnosinfdef_current.pdf (accessed 2022-3-8).
[17] Ikeno Y, Sakakibara S, Yokawa K, Kitani K, Nakai H, Yamanaka K, et al. Post-sternotomy deep wound infection following aortic surgery: wound care strategies to prevent prosthetic graft replacement. Eur J Cardiothorac Surg 2019;55(5):975–83.
[18] Kanda Y. Investigation of the freely available easy-to-use software 'EZR' for medical statistics. Bone Marrow Transplant 2013;48:452–8.
[19] Kitano D, Sakakibara S, Yamanaka K, Osaki T, Nomura T, Okada K, et al. Versatility of anterolateral partial sternotomy for mediastinal reconstruction with trans-thoracic latissimus dorsi muscle flap in aortic graft infection. Int J Surg Wound Care 2022;3(3):81–7.
[20] Kitano D, Sakakibara S, Osaki T, Maruguchi H, Nomura T, Terashi H. Late-onset post-sternotomy mediastinitis with hematogenous metastasis of infection in hemodialysis patient. Int J Surg Wound Care 2021;4(2):107–10.
[21] Kitano D, Kitamura Y, Yonezawa K, Nishio W, Iwae S, Nakahara M, et al. Combined type mediastinitis after thyroidectomy managed by negative pressure wound therapy with instillation; a case report. Eplasty 2019;19:ic10. eCollection 2019.