Kobe University Repository : Kernel

PDF issue: 2025-12-05

Impella inlet area adjacent to mitral valve leaflets potentially leads to mitral chordal rupture

Osumi, Yuto
Toba, Takayoshi
Hisamatsu, Eriko
Hirata, Ken-Ichi
Otake, Hiromasa

(Citation)
European Heart Journal : Case Reports,6(12):ytac451

(Issue Date)
2022-12

(Resource Type)
journal article

(Version)
Version of Record

(Rights)
© The Author(s) 2022. Published by Oxford University Press on behalf of the European Society of Cardiology.
This is an Open Access article distributed under the terms of the Creative Commons Attribution-NonCommercial License (https://creativecommons.org/licenses/by-nc/4.0/),…

(URL)
https://hdl.handle.net/20.500.14094/0100478228

European Heart Journal - Case Reports (2022) **6**, 1–2
https://doi.org/10.1093/ehjcr/ytac451

CARDIOVASCULAR FLASHLIGHT
Other

Impella inlet area adjacent to mitral valve leaflets potentially leads to mitral chordal rupture

Yuto Osumi, Takayoshi Toba *, Eriko Hisamatsu, Ken-Ichi Hirata, and Hiromasa Otake

Division of Cardiovascular Medicine, Department of Internal Medicine, Kobe University Graduate School of Medicine, 7-5-1 Kusunoki-cho, Chuo-ku, Kobe 6500017, Japan

Received 20 September 2022; first decision 19 October 2022; accepted 18 November 2022; online publish-ahead-of-print 22 November 2022

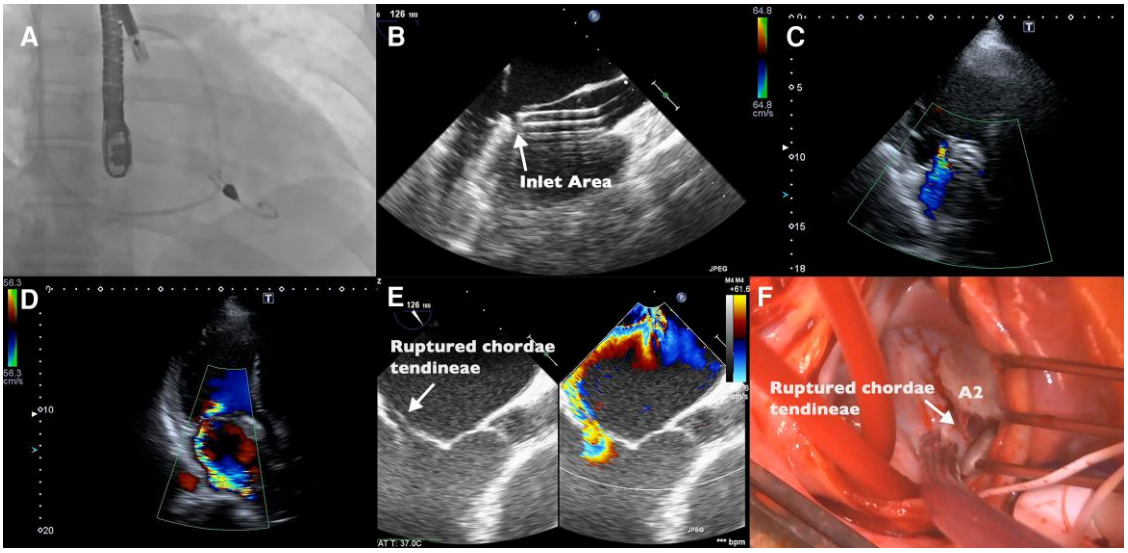

A 42-year-old man with acute heart failure due to dilated cardiomyopathy was admitted to our institution. Transthoracic echocardiography (TTE) showed severe left ventricular (LV) dysfunction and moderate mitral regurgitation (MR). As his condition was not well-controlled with intra-aortic balloon pumping and dobutamine infusion, Impella 5.0 was inserted via the right subclavian artery. Although we attempted to advance this device towards the LV apex and away from mitral valve apparatus, it was forced into the position adjacent to the anterior mitral valve leaflet (*Panels A and B*). Transoesophageal echocardiography (TEE) confirmed no change of the mitral valve apparatus motion and no entanglement in the sub-mitral apparatus during the procedure. We performed TTE each day because the Impella positioning was suboptimal and then confirmed no change of the position of Impella catheter and MR grade (*Panel C*); however, 3 days after the implantation, MR worsened to severe with an eccentric jet impinging on the left atrial posterior wall (*Panel D*). TEE showed chordal rupture of the anterior mitral valve leaflet (*Panel E*). Consequently, he underwent mitral valve repair in addition to implantation of the HeartMate3 for bridge to transplantation (*Panel F*). Only a few reports have described mitral chordal rupture during Impella support. In these cases, as in the present case, the inlet area was adjacent to the mitral valve leaflet (see Supplementary material online, *Video S1*). This finding suggests that persistent mechanical damage by

* Corresponding author. Tel: 81-78-382-5846, Fax: 81-78-382-5859, Email: taka02222003@gmail.com
Handling Editor: Faten Yahia
© The Author(s) 2022. Published by Oxford University Press on behalf of the European Society of Cardiology.
This is an Open Access article distributed under the terms of the Creative Commons Attribution-NonCommercial License (https://creativecommons.org/licenses/by-nc/4.0/), which permits non-commercial re-use, distribution, and reproduction in any medium, provided the original work is properly cited. For commercial re-use, please contact journals.permissions@oup.com

Downloaded from https://academic.oup.com/ehjcr/article/6/12/ytac451/6840457 by Kobe University Library user on 19 January 2023

contact of the inlet itself or drawing blood flow may cause mitral chordal rupture. In cases where the inlet area has to be located adjacent to mitral valve leaflets, watchful observation with TTE is needed, and early withdrawal of Impella may be required.

Supplementary material

Supplementary material is available at *European Heart Journal – Case Reports*.

Acknowledgements: The authors thank all staff involved in this case.

Consent: The authors confirm that written consent for submission and publication of this case report including images and associated text has been obtained from the patient in line with COPE guidance.

Conflict of interest: None declared.

Funding: None declared.

Downloaded from https://academic.oup.com/ehjcr/article/6/12/ytac451/6840457 by Kobe University Library user on 19 January 2023