



Absorbable Barbed Continuous versus Nonabsorbable Nonbarbed Interrupted Suturing Methods for Donor-site Closure of the Rectus Abdominis Myocutaneous Flap

Kitano, Daiki

Nomura, Tadashi

Sakakibara, Shunsuke

Terashi, Hiroto

(Citation)

Plastic and Reconstructive Surgery Global Open, 11(1):e4742

(Issue Date)

2023-01

(Resource Type)

journal article

(Version)

Version of Record

(Rights)

© 2023 The Authors. Published by Wolters Kluwer Health, Inc. on behalf of The American Society of Plastic Surgeons.

This is an open-access article distributed under the terms of the Creative Commons Attribution-Non Commercial-No Derivatives License 4.0 (CCBY-NC-ND), where it is...

(URL)

<https://hdl.handle.net/20.500.14094/0100479023>



Absorbable Barbed Continuous versus Nonabsorbable Nonbarbed Interrupted Suturing Methods for Donor-site Closure of the Rectus Abdominis Myocutaneous Flap

Daiki Kitano, MD
Tadashi Nomura, MD, PhD
Shunsuke Sakakibara, MD, PhD
Hiroto Terashi, MD, PhD

Background: Abdominal incisional hernia is a complication of the rectus abdominis myocutaneous (RAMC) flap harvest. This study aimed to compare the incidence of abdominal incisional hernia and donor-site closure time between absorbable barbed continuous (ABC) and non-absorbable non-barbed interrupted (nAnBI) methods.

Methods: This study included 145 patients who underwent free RAMC flap reconstruction after head and neck cancer surgery at Kobe University Hospital between January 2012 and March 2020. The nAnBI method was selected between January 2012 and August 2016, and the ABC method was selected between September 2016 and March 2020. The incidence of abdominal incisional hernia and the average time required for donor-site closure were compared between the two groups.

Results: Of the 145 patients surveyed, 116 (57 and 59 in the nAnBI and ABC groups, respectively) were followed-up for at least 90 days after the surgery. The incidence rates of abdominal incisional hernia were 0% and 5.1% ($n = 3$) in the nAnBI and ABC groups, respectively, with no significant differences ($p = 0.244$). The average donor-site closure times were 127.6 and 111.3 minutes in the nAnBI and ABC groups, respectively, with no significant differences ($p = 0.122$).

Conclusions: No significant differences in the incidence of abdominal incisional hernia and donor-site closure time were observed between the nAnBI and ABC groups. However, there was a tendency for increased hernia occurrence and shorter wound closure time in the ABC group. A randomized prospective multicenter study is warranted to validate our findings of the ABC method. (*Plast Reconstr Surg Glob Open* 2023; 11:e4742; doi: [10.1097/GOX.0000000000004742](https://doi.org/10.1097/GOX.0000000000004742); Published online 12 January 2023.)

INTRODUCTION

The free rectus abdominis myocutaneous (RAMC) flap is one of the most commonly used flaps in head and neck reconstructive surgery.¹ The RAMC flap offers sufficient well-vascularized soft tissues that are suitable for filling wide defects. Although the RAMC flaps have high versatility in reconstructive surgery, there are risks of

donor-site morbidity, including abdominal incisional hernia and bulging.²

Patients with abdominal incisional hernia often complain of a decline in quality of life, including several symptoms, such as abdominal pain. Various techniques have been studied to prevent abdominal incisional hernia after flap harvest.^{3,4} The incidence of abdominal incisional hernia is also associated with disruption of the fascial suture. Traditionally, we have performed the interrupted suturing technique with nonabsorbable sutures to close fascial defects at the flap donor-site. The alternative option is the continuous suturing technique with absorbable sutures.

From the Department of Plastic Surgery, Kobe University Graduate School of Medicine, Kobe, Japan.

Received for publication September 2, 2022; accepted November 11, 2022.

Copyright © 2023 The Authors. Published by Wolters Kluwer Health, Inc. on behalf of The American Society of Plastic Surgeons. This is an open-access article distributed under the terms of the [Creative Commons Attribution-Non Commercial-No Derivatives License 4.0 \(CCBY-NC-ND\)](https://creativecommons.org/licenses/by-nc-nd/4.0/), where it is permissible to download and share the work provided it is properly cited. The work cannot be changed in any way or used commercially without permission from the journal.
DOI: [10.1097/GOX.0000000000004742](https://doi.org/10.1097/GOX.0000000000004742)

Disclosure: The authors have no financial interest to declare in relation to the content of this article.

Related Digital Media are available in the full-text version of the article on www.PRSGlobalOpen.com.

However, this technique predisposes the site to suture loosening and wide abdominal wall breakdown.

In recent years, barbed suture materials have been used for abdominal fascial plication.⁵ These devices incorporate barbs on the side of the nonbarbed threads to allow nonloosening knotless continuous sutures. One benefit of the continuous barbed suturing technique is the shorter duration of surgery.⁶ However, few studies have examined the use of continuous barbed sutures for flap donor-site closure. This study aimed to evaluate the incidence of abdominal incisional hernia and the donor-site closure time with the use of conventional interrupted and continuous barbed sutures.

MATERIALS AND METHODS

Patients

Our study included 145 patients who underwent head and neck reconstruction with a free RAMC flap at Kobe University Hospital between January 2012 and March 2020. Patient characteristics, such as age, sex, body mass index, flap size, and follow-up period, were retrospectively analyzed using medical records. Patients without records or follow-up examinations 90 days or more postoperatively were excluded from this study.

Surgical Procedure

An oval-shaped skin paddle was designed along the unilateral rectus abdominis muscle. After the skin incision, the subcutaneous tissues and muscle were harvested along with the anterior sheath. The width of the anterior sheath defect depends on the size of the skin paddle. If the width of the skin paddle was larger than the width of the rectus abdominis muscle, we undermined the flap medially or laterally to the level of the perforators to spare the anterior sheath (usually 1 cm) so that the suture held the remnant tightly. Recipient vessels in the head and neck area were prepared by another team along with the flap harvest. The deep inferior epigastric artery and veins were anastomosed to the recipient vessels under a microscope. Donor-site closure was initiated simultaneously with microscopic anastomosis.

The anterior sheath remnant was approximated using a nonabsorbable braided nylon thread made from nylon (2-0 Neobraid, Alfresa Pharma, Osaka, Japan) or an absorbable monofilament with unidirectional barbs along the core thread (0-STRATAFIX Symmetric PDS Plus, Johnson & Johnson, Tokyo, Japan). Between January 2012 and August 2016, 2-0 Neobraid was used for the interrupted suture technique [nonabsorbable nonbarbed interrupted (nAnBI) group] (Fig. 1). Between September 2016 and March 2020, 0-STRATAFIX was used for the continuous suture technique [absorbable barbed continuous (ABC) group] (Fig. 2). [See Video (online), which displays the absorbable barbed continuous suturing method. After flap harvest, the anterior sheath remnant was approximated using an absorbable monofilament with

Takeaways

Question: Does the absorbable barbed continuous suturing method reduce the donor-site problems or operation time following the rectus abdominis myocutaneous flap harvest?

Findings: Compared to conventional closure method, no significant differences in the incidence of abdominal incisional hernia and donor-site closure time were observed. However, there was a tendency for increased hernia occurrence and shorter wound closure time in the absorbable barbed continuous suturing method.

Meaning: The adoption of the absorbable barbed continuous suturing method was expected to be helpful because it reduced the vibrations of knot-tying procedures which disturbed reconstructive microsurgery. Further large-scale studies are warranted to confirm the validity of this method.

unidirectional barbs along the core thread (0-STRATAFIX Symmetric PDS Plus). The barbs prevented the loosening of the suture].

After the anterior sheath was closed, a polypropylene mesh was placed to reinforce the suture site. The mesh was placed in an on-lay manner, extending from the arcuate line of the rectus sheath to the caudal end of the donor-site. A closed suction drain was placed to prevent hematoma and seroma. The skin and subcutaneous tissues were then approximated. All patients were instructed to wear a girdle for 3 months to prevent application of pressure to their abdomen.

Primary and Secondary Outcomes

The primary outcome was the incidence of abdominal incisional hernia and abdominal wall protrusion (bulging). Abdominal palpation was performed for all patients during the follow-up visit. Patients with abdominal problems were subjected to imaging studies. Hernia was diagnosed when the protrusion of abdominal contents was detected on computed tomography (Fig. 3). The incidence of hernia and bulge (Fig. 4) was compared between the nAnBI and ABC groups.

The secondary outcome was the time required for flap donor-site closure, which was calculated from the time of vascular pedicle separation to the completion of closure. Patients without records of donor-site closure time were excluded from the secondary outcome survey. The flap size was also investigated in patients surveyed for secondary outcomes.

Statistical Analysis

Fisher exact test was performed to determine if there were associations between two categorical variables. Student *t* test was performed to determine if there was a significant difference between the means of the two groups. The significance level for this study was set at 5%. Statistical analyses were performed using the EZR software.⁷

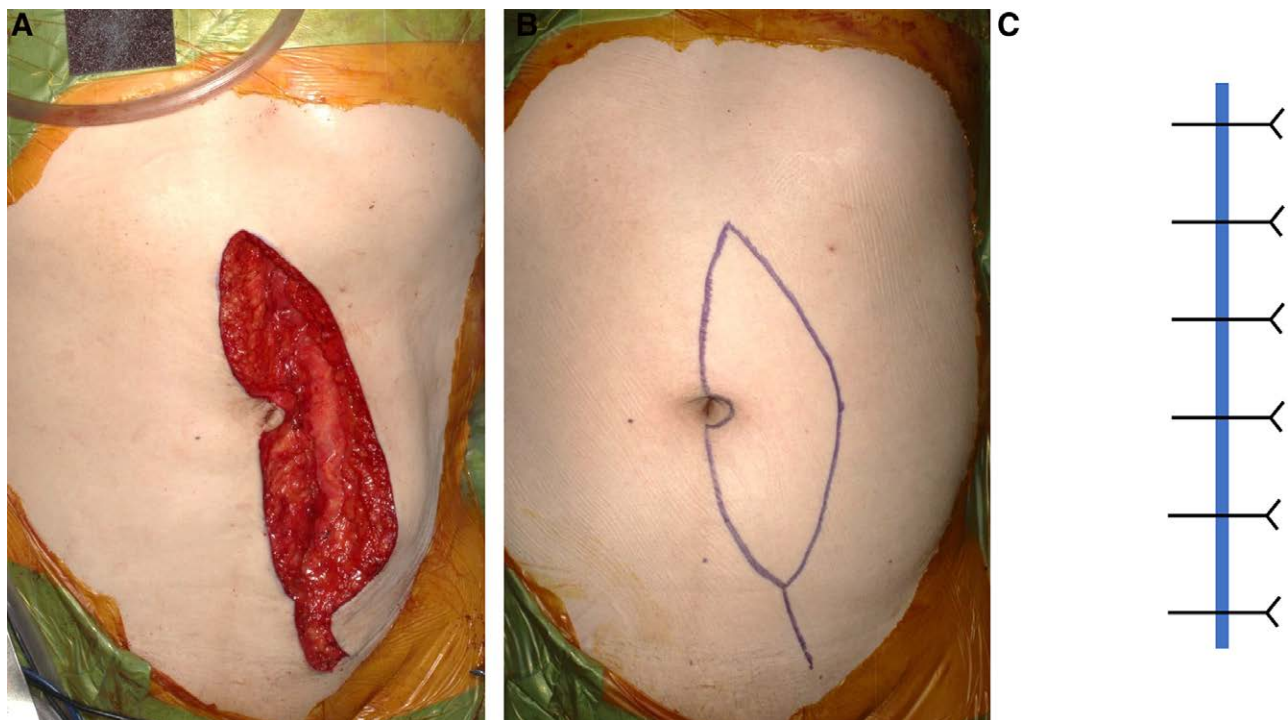


Fig. 1. nAnBI suture method. A, A vertical rectus abdominis myocutaneous flap is designed on the left abdomen. B, After harvesting the flap, the residual anterior sheath of the rectus abdominis muscle is closed with a nAnBI suture (2-0 Neobraid). C, Scheme of the nAnBI method.

Ethical Approval

This study was approved by the ethics committee of Kobe University Hospital (approval number: B210281).

RESULTS

Patient Characteristics

Of the 145 patients surveyed, 116 (57 and 59 in the nAnBI and ABC group, respectively) were followed-up for at least 90 days after the surgery and had complete surgical records (Table 1). There were no significant differences in the mean age (66.3 versus 66.9 years, $P = 0.755$), male sex ratio (71.9 versus 66.1%, $p = 0.498$), body mass index (21.1 versus 21.2 kg/m², $P = 0.844$), vertical length of the flap (18.6 versus 20.3 cm, $P = 0.143$), or transverse diameter of the flap (7.6 versus 7.9 cm, $P = 0.127$) between two groups. The mean observation period was significantly longer in the nAnBI group than in the ABC group (1135.4 versus 680.0 days, $P = 0.003$), because the ABC method was adopted after September 2016.

Abdominal Incisional Hernia and Bulge

Of the 57 patients in the nAnBI group, no patient (0%) developed an abdominal incisional hernia, and three (5.3%) developed abdominal bulging (Table 2). Of the 59 patients in the ABC group, three patients (5.1%) developed abdominal hernia, and six (10.2%) developed abdominal bulging. There was no significant difference in the incidence of hernia and bulge between the two groups ($P = 0.244$ and 0.491 , respectively).

The characteristics of the 12 cases with hernia or bulge are summarized in Table 3. The site of hernia or bulge was the lower quadrant of the abdomen in nine cases, the periumbilical area in two cases, and the upper quadrant in one case. The average time from surgery to onset of hernia and bulge was 295.3 and 249.2 days, respectively. (260.8 days, in total). The mean size of the hernia orifice was 6.7 cm in vertical length and 5.7 cm in transverse length. Of the three cases with a hernia, the area of herniation was confined to a portion of flap donor-site (upper or lower quadrant of the abdomen), which implied that a partial fascial breakdown occurred.

Donor-site Closure Time

Ten patients in the nAnBI group and 24 in the ABC group had records of accurate donor-site closure times (Table 4). The mean flap sizes in the nAnBI and ABC groups were 20.6 and 21.0 cm for vertical length ($P = 0.859$) and 7.6 and 8.0 cm for transverse diameter ($P = 0.427$). The mean donor-site closure time for the nAnBI and ABC groups were 127.6 and 111.3 minutes, respectively. There was no significant difference in donor-site closure time between the two groups ($P = 0.112$).

DISCUSSION

An adequate amount of well-vascularized free tissue transfer is necessary for head and neck reconstruction. Reconstructive surgeons are required to have appropriate knowledge and skills for safe flap harvesting. The deep

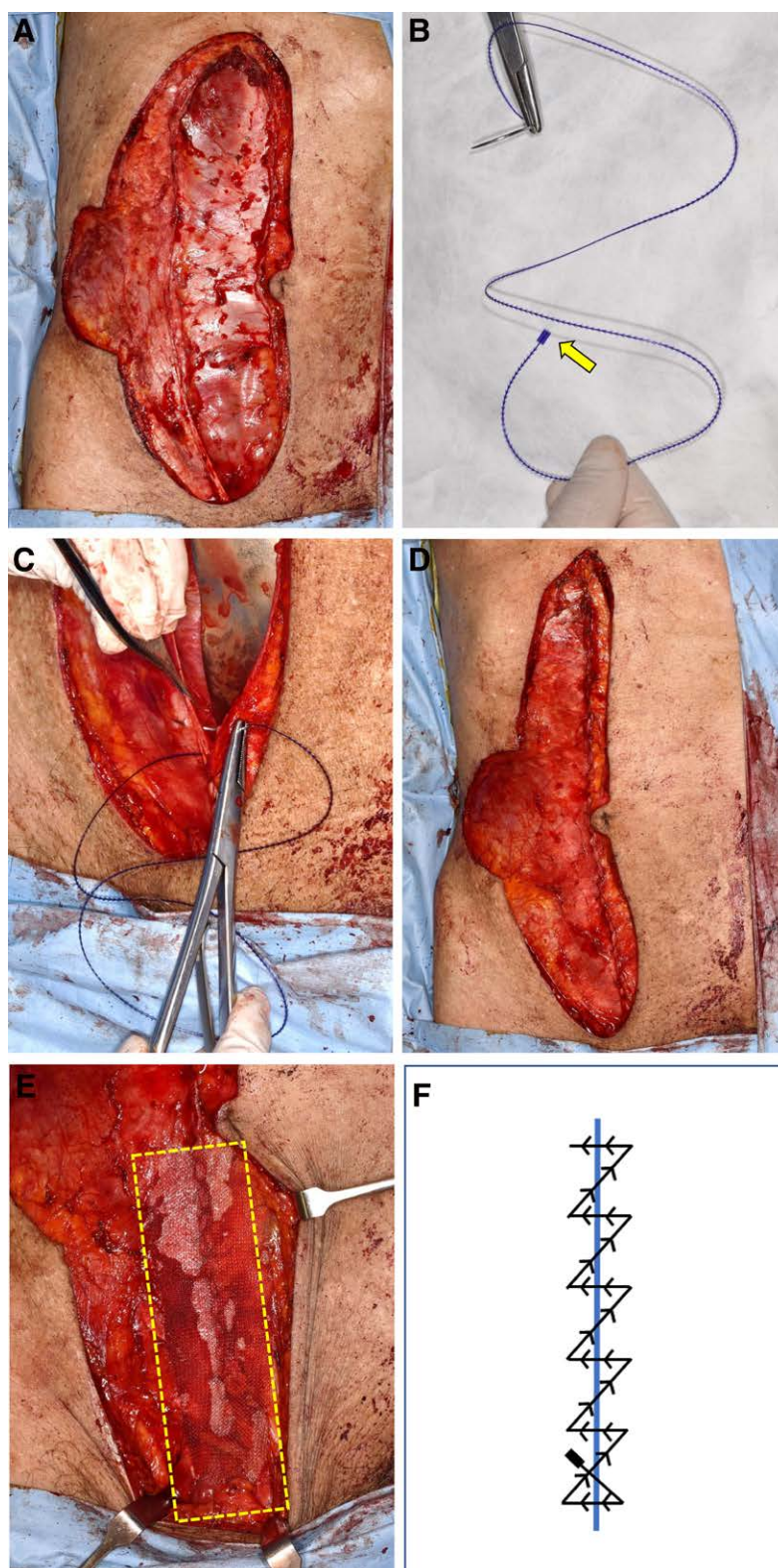


Fig. 2. ABC suture method. A, A bilobed rectus abdominis myocutaneous flap is harvested from the right abdomen. B, The ABC suture material (0-STRATAFIX Symmetric PDS Plus) has a solid core with unidirectional barbs and a fixation tab (arrow) at the end of the core. C, The residual anterior sheath of the rectus abdominis is approximated using 0-STRATAFIX. D, After tight fascial closure with 0-STRATAFIX, the barbs prevent the loosening of the suture. E, Scheme of the ABC method. F, The closed fascia below the arcuate line is reinforced with polypropylene mesh (yellow square).

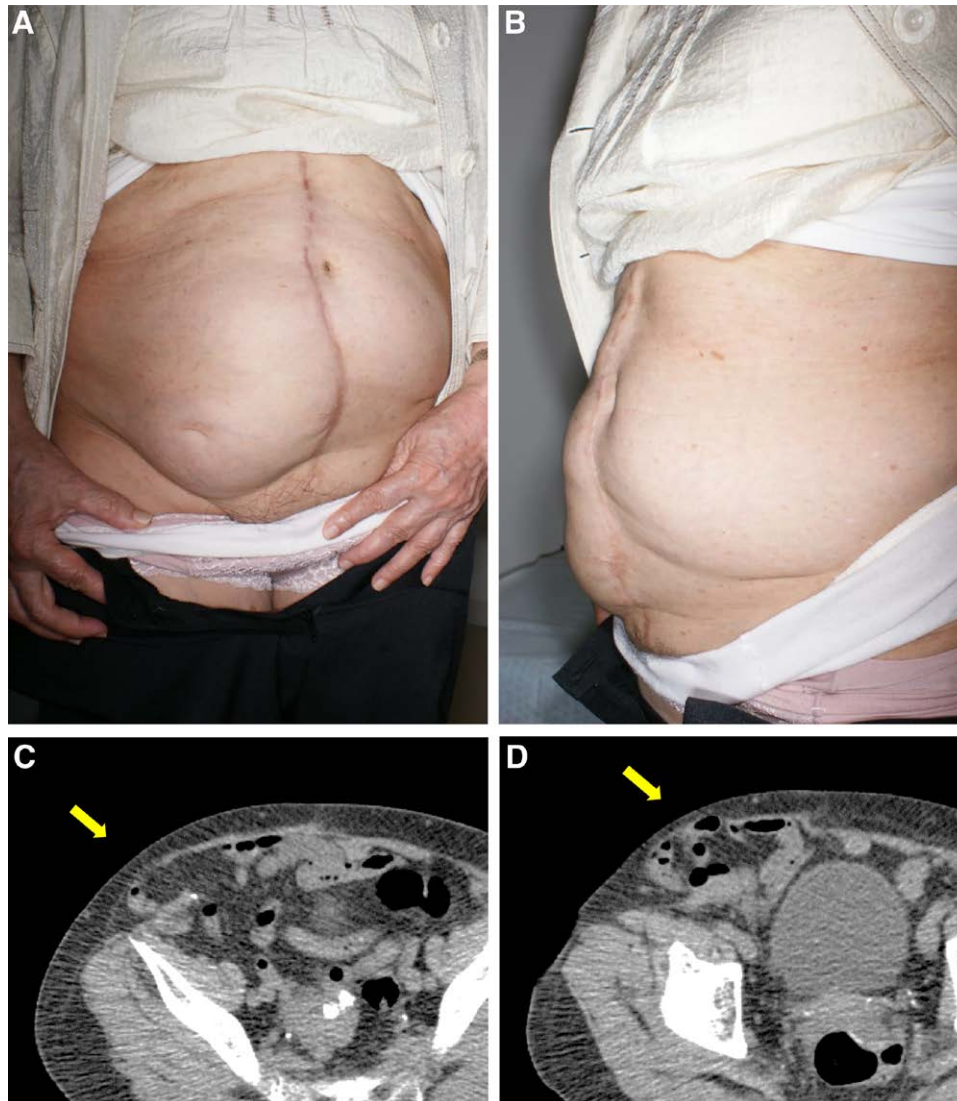


Fig. 3. A case of abdominal incisional hernia (No. 4 in Table 3). A, An abdominal incisional hernia in the right abdominal flap donor-site. B, Left lateral view shows that the right abdomen is highly protruded when compared with the left side. C-D, Abdominal computed tomography showing bowel herniation (arrow) from the right abdominal wall.

inferior epigastric artery (the main vascular pedicle of the free RAMC flap) originates from the external iliac artery and travels through the rectus abdominis muscle. The flap is harvested with some branches of the vascular pedicle (perforators), which stabilize the hemodynamics of the skin paddle and subcutaneous tissues. The skin paddle is usually designed vertically in an oval shape in the unilateral abdomen along the rectus abdominis muscle (v-RAMC flap).⁸

The rectus abdominis muscle is surrounded by the deep fascia, which consists of the abdominal wall. The anterior sheath was partially harvested with the RAMC flap. Extensive defects in the anterior sheath result in abdominal wall weakness. An abdominal incisional hernia refers to protrusion of the intestine from the abdominal cavity. Nakatsuka et al reported that the incidence rate of

abdominal incisional hernia was 3.5% in head and neck reconstruction with a v-RAMC flap.⁹

The lower part of the flap donor-site was more fragile than the upper part. The boundary (the arcuate line) is the inferior margin of the posterior sheath. The lower abdomen is the predominant site of abdominal incisional hernia. Patients with severe symptoms, such as persistent pain or a significant decrease in quality of life, are indicated for surgical intervention.¹⁰ However, there are a few patients who are unwilling to undergo invasive surgery. Therefore, the prevention of abdominal incisional hernia, in other words, secure donor-site closure during the primary surgery, is necessary.

Numerous methods of wound closure have been proposed to minimize the number of complications after laparotomy with a midline abdominal incision. In this regard, many studies focus on the fascial closure materials. As such,

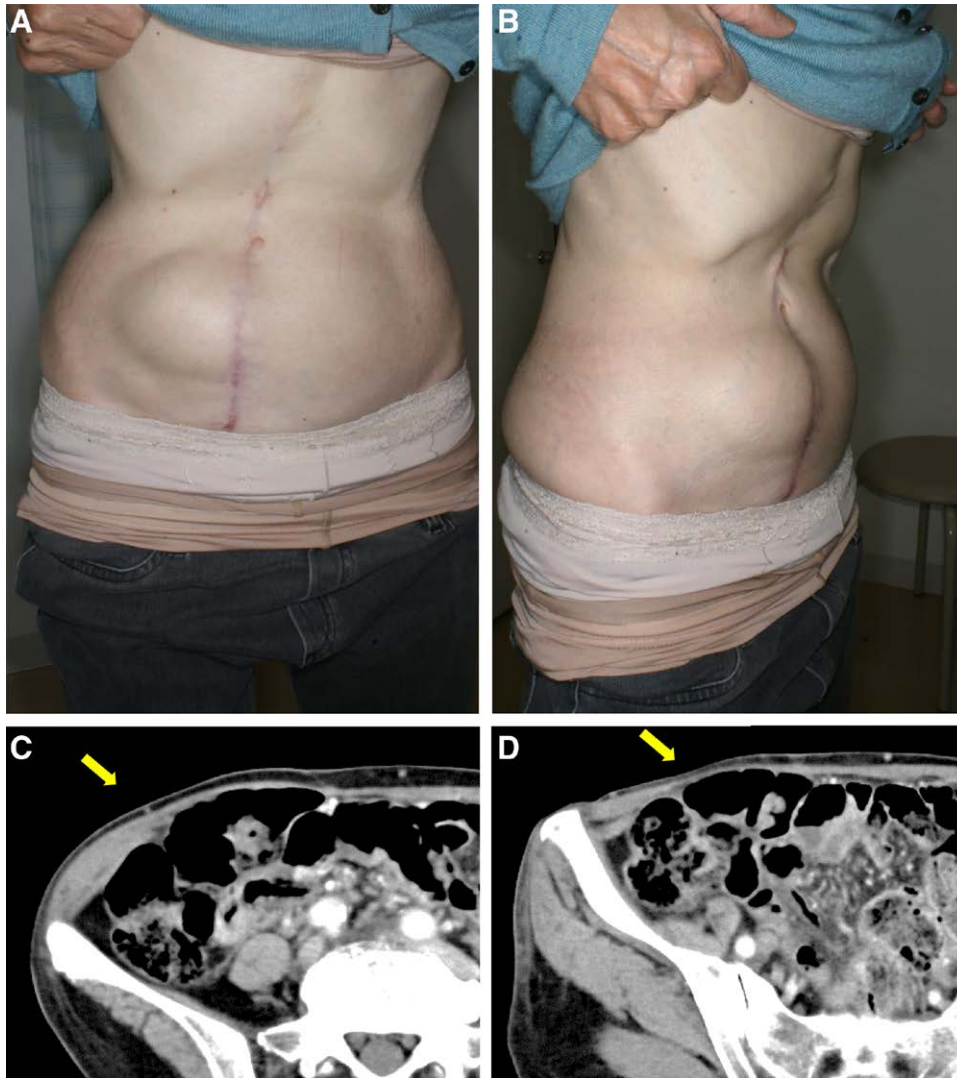


Fig. 4. A case of abdominal bulging (No. 5 in Table 3). A, Abdominal bulging in the right abdominal flap donor-site in the standing position. B, The right lateral view confirms protrusion of the right lower abdomen. C-D, Abdominal computed tomography showing protrusion of the right abdominal wall (arrow). However, there is no bowel herniation outside the abdominal wall.

Table 1. Patient Characteristics

	nAnBI	ABC	<i>P</i>
Number	57	59	
Age (y)	66.3	66.9	0.755
Sex (men, %)	71.9	66.1	0.498
BMI (kg/m ²)	21.1	21.2	0.844
Flap size (length, cm)	18.6	20.3	0.143
Flap size (width, cm)	7.6	7.9	0.127
Follow-up period (d)	1135.4	680.0	0.003

Table 2. The Incidence of Abdominal Hernia and Bulge

	nAnBI	ABC	<i>P</i>
Number	57	59	
Hernia	0	3	0.244
Bulge	3	6	0.491
Total	3	9	0.125

it is important to keep the suture site tension-free until complete fusion of the fascia has been achieved. The use of a rapidly absorbable suture was associated with a higher incidence of hernia and lower postoperative wound pain than with the use of the nonabsorbable suture.¹¹ It has been suggested that the absorbable suture disintegrates before the fascia is fused completely, which predisposes the site to hernia development. The risk of hernia is reduced when slowly absorbable threads are utilized.¹² The herniation incidence of slowly absorbable threads was not different from that with the use of nonabsorbable sutures.¹³ The incidence rate of hernia tends to be lower with the continuous suture method than with the interrupted suture method.¹⁴ While there was no difference in the incidence rate between the use of slowly absorbable and nonabsorbable continuous sutures, a higher incidence of suture abscess was observed in

Table 3. Patient List of Abdominal Hernia and Bulge

No.	Method	Diagnosis	Site of Hernia/Bulge	Days from Surgery to Diagnosis	Vertical Diameter (cm)	Transverse Diameter (cm)
1	nAnBI	Bulge	Lower quadrant	155	—	—
2	nAnBI	Bulge	Lower quadrant	126	—	—
3	nAnBI	Bulge	Lower quadrant	328	—	—
4	ABC	Hernia	Upper quadrant	336	5	4.5
5	ABC	Bulge	Lower quadrant	188	—	—
6	ABC	Bulge	Lower quadrant	181	—	—
7	ABC	Hernia	Lower quadrant	117	7.5	6.2
8	ABC	Bulge	Lower quadrant	552	—	—
9	ABC	Bulge	Periumbilical	181	—	—
10	ABC	Bulge	Periumbilical	188	—	—
11	ABC	Hernia	Lower quadrant	433	7.5	6.5
12	ABC	Bulge	Lower quadrant	344	—	—

Table 4. Donor-site Closure Time

	nAnBI	ABC	P
Number	10	24	
Time (min)	127.6	111.3	0.112
Flap size (length, cm)	20.6	21.0	0.859
Flap size (width, cm)	7.6	8.0	0.427

cases with nonabsorbable sutures.¹⁵ In 2015, the European Society of Hernia published a guideline that recommended continuous suture with slowly absorbable material for fascial closure in elective midline laparotomy.¹⁶

While there is no obvious consensus regarding fascial closure in the RAMC flap donor-site, a majority favor continuous sutures with absorbable material or interrupted sutures with nonabsorbable material. However, the choice of suture material is at the surgeon's discretion.¹⁷ We have traditionally adopted interrupted sutures with nonabsorbable material. However, the vibrations arising from the knot-tying procedure in the abdominal area disturbed the reconstruction team who were simultaneously performing the microsurgical procedure in the neck area. In addition, interrupted sutures required more time than continuous sutures. Therefore, the adoption of continuous sutures was expected to reduce both vibrations and wound closure time. However, we were apprehensive of the risk of abdominal incisional hernia due to the loosening of continuous sutures.

We utilized barbed suture material as an innovative solution that facilitated faster suturing and sutures with less loosening. The barb, which was attached to the slowly absorbable suture, held the fascia tightly, even under high stress. The wound-holding strength with barbed continuous sutures was significantly higher than that with non-barbed continuous sutures.¹⁸ In addition, the barbed suture maintained sufficient holding strength for 6 weeks postoperatively, when the wound edge was considered to be fused completely.¹⁹ However, our results demonstrated that it took several months to develop the abdominal hernia or bulge. The time interval between fascial fusion and hernia development could be explained by the vulnerability of the fascial closure site, even after the fascial fusion was achieved. The durability against tearing strength of the fused fascia was considered to increase with time. We recommend that surgeons instruct patients to avoid applying pressure on their abdomen at least 6 months after the surgery.

Yasuda et al reported 18 cases of absorbable barbed continuous sutures for RAMC flap donor-site closure.²⁰ Their

study included eight v-RAMC flap cases, of which one developed an abdominal incisional hernia. The limitation of their study was the small number of cases and the short follow-up duration. In our study, we examined 59 cases of absorbable barbed continuous suture for an average of 680 days after the surgery. While the incidence of hernia and donor-site closure time was not reduced significantly with the use of absorbable barbed continuous suture when compared with nonabsorbable nonbarbed interrupted sutures, there was a tendency for increased hernia occurrence and shorter wound closure time with the use of the former suturing technique.

The limitations of our study included its retrospective study design and the limited number of cases. There was a much longer follow-up time for the nAnBI group than for the ABC group because this was a retrospective cohort study. The difference in follow-up time between the two groups could lead to a misjudgment regarding the incidence of complications, although no patient developed hernia or bulge more than 2 years after the operation. To overcome these limitations, a randomized prospective multicenter study is warranted.

In conclusion, no significant differences were observed between the nAnBI and ABC groups with respect to the incidence of abdominal incisional hernia and donor-site closure time. However, there was a tendency for the occurrence of increased abdominal incisional hernia and shorter donor-site closure time in the ABC group. Further large-scale studies are warranted to confirm the validity of the ABC method.

Daiki Kitano, MD

Department of Plastic Surgery
Kobe University Graduate School of Medicine
7-5-2, Kusunoki-cho, Chuo-ku, Kobe 650-0017
Japan

E-mail: dkitano.kobe.prs@gmail.com

ACKNOWLEDGMENT

This study was approved by the Kobe University Hospital Ethics Committee (approval number: B210281).

REFERENCES

1. Kroll SS, Baldwin BJ. Head and neck reconstruction with the rectus abdominis free flap. *Clin Plast Surg*. 1994;21:97–105.
2. Aki FE, Besteiro JM, Ferreira MC. Immediate reconstruction of extensive defects in head and neck with the rectus

- abdominis musculocutaneous free flap. *Rev Soc Bras Cir Plast.* 1997;12:37–54.
3. Mortensen AR, Grossmann I, Rosenkilde M, et al. Double-blind randomized controlled trial of collagen mesh for the prevention of abdominal incisional hernia in patients having a vertical rectus abdominis myocutaneous flap during surgery for advanced pelvic malignancy. *Colorectal Dis.* 2017;19:491–500.
4. Schellerer VS, Bartholomé L, Langheinrich MC, et al. Donor site morbidity of patients receiving vertical rectus abdominis myocutaneous flap for perineal, vaginal or inguinal reconstruction. *World J Surg.* 2021;45:132–140.
5. Rosen A, Hartman T. Repair of the midline fascial defect in abdominoplasty with long-acting barbed and smooth absorbable sutures. *Aesthet Surg J* 2011;31:668–673.
6. Gutowski KA, Warner JP. Incorporating barbed sutures in abdominoplasty. *Aesthet Surg J.* 2013;33:76S5–81S5.
7. Kanda Y. Investigation of the freely available easy-to-use software “EZR” for medical statistics. *Bone Marrow Transplant.* 2013;48:452–458.
8. Taylor GI, Palmer JH. The vascular territories (angiosomes) of the body: experimental study and clinical applications. *Br J Plast Surg.* 1987;40:113–141.
9. Nakatsuka T, Harii K, Yamada A, et al. Versatility of a free inferior rectus abdominis flap for head and neck reconstruction: analysis of 200 cases. *Plast Reconstr Surg.* 1994;93:762–769.
10. Meland NB, Fisher J, Irons GB, et al. Experience with 80 rectus abdominis free-tissue transfers. *Plast Reconstr Surg.* 1989;83:481–487.
11. Rucinski J, Margolis M, Panagopoulos G, et al. Closure of the abdominal midline fascia: meta-analysis delineates the optimal technique. *Am Surg.* 2001;67:421–426.
12. Diener MK, Voss S, Jensen K, et al. Elective midline laparotomy closure – the INLINE systematic review and meta-analysis. *Ann Surg.* 2010;251:843–856.
13. van ’t Riet M, Steyerberg EW, Nellensteyn J, et al. Meta-analysis of techniques for closure of midline abdominal incisions. *Br J Surg.* 2002;89:1350–1356.
14. Hodgson NC, Malthaner RA, Ostbye T. The search for an ideal method of abdominal fascial closure: a meta-analysis. *Ann Surg.* 2000;231:436–442.
15. Sajid MS, Parampalli U, Baig MK, et al. A systematic review on the effectiveness of slowly-absorbable versus non-absorbable sutures for abdominal fascial closure following laparotomy. *Int J Surg.* 2011;9:615–625.
16. Muysoms FE, Antoniou SA, Bury K, et al; European Hernia Society. European Hernia Society guidelines on the closure of abdominal wall incisions. *Hernia.* 2015;19:1–24.
17. Butler CE, Gündeslioglu AO, Rodriguez-Bigas MA. Outcomes of immediate vertical rectus abdominis myocutaneous flap reconstruction for irradiated abdominoperineal resection defects. *J Am Coll Surg.* 2008;206:694–703.
18. Nawrocki JG, Nonnenmann H, Mooney M, et al. A high-strength, absorbable, antibacterial knotless tissue control device for fascial closure. *Curr Obstet Gynecol Rep.* 2017;6:175–181.
19. Oni G, Brown SA, Kenkel JM. A comparison between barbed and nonbarbed absorbable suture for fascial closure in a porcine model. *Plast Reconstr Surg.* 2012;130:535e–540e.
20. Yasuda S, Tomita K, Kiya K, et al. Stratafix for abdominal wall repair following abdominal flap harvest. *Plast Reconstr Surg Glob Open* 2017;5:e1572.