



A Case of a Highly Obese Covid-19 Patient with Severe Hypoxemia and Subcutaneous Mediastinal Emphysema Who Was Rescued by Early Introduction of ECMO

Takahashi, Shuhei ; Obata, Norihiko ; Makino, Shohei ; Furushima, Nana ; Nishimura, Taichi ; Mizobuchi, Satoshi

(Citation)

The Kobe journal of the medical sciences, 69(2):49-51

(Issue Date)

2023

(Resource Type)

departmental bulletin paper

(Version)

Version of Record

(JaLDOI)

<https://doi.org/10.24546/0100482770>

(URL)

<https://hdl.handle.net/20.500.14094/0100482770>



A Case of a Highly Obese Covid-19 Patient with Severe Hypoxemia and Subcutaneous Mediastinal Emphysema Who Was Rescued by Early Introduction of ECMO

SHUHEI TAKAHASHI¹, NORIHIKO OBATA^{2,*}, SHOHEI MAKINO²,
NANA FURUSHIMA², TAICHI NISHIMURA², and SATOSHI MIZOBUCHI²

¹*Department of Anesthesiology, Pain and Palliative Care Medicine, Chiba University Hospital, Chiba, Japan;*

²*Department of Anesthesiology, Kobe University Hospital, Kobe, Japan*

**Corresponding author*

Received February 20, 2023/Accepted June 19, 2023

Keywords: Covid-19; Obesity; Extracorporeal membrane oxygenation (ECMO); Mediastinal emphysema; Case report

We conducted the treatment of a highly obese patient with severe Covid-19 pneumonia who had a history of asthma. When she arrived at the hospital, she was already intubated and had mediastinal emphysema and severe hypoxemia. Because the patient's condition did not improve with mechanical ventilation, we introduced extracorporeal membrane oxygenation (ECMO) immediately after admission. The patient improved with early induction of ECMO and prone positioning. In the management of patients with severe Covid-19 pneumonia, early introduction of ECMO should be considered if oxygenation does not improve with mechanical ventilation, and prone positioning can also be effective.

INTRODUCTION

Covid-19 can cause severe acute respiratory distress syndrome (ARDS) requiring mechanical ventilation, and for more severe cases, extracorporeal membrane oxygenation (ECMO) may also be required [1]. However, the optimal timing of when to introduce ECMO after mechanical ventilation has not yet been established. We report a case in which early introduction of ECMO led to rescue of a highly obese Covid-19 patient.

CLINICAL CASE

The patient consented to the submission of this case report to the journal. She was a severely obese 50-year-old woman with a height of 154 cm and a weight of 100 kg (body mass index: 42.2 kg/m²). She had a history of hypertension, controlled bronchial asthma, with last attack five years ago, and untreated diabetes mellitus (HbA1c 9.0%).

She presented with fever, respiratory distress and malaise. On examination at a previous hospital, she was found to be positive for SARS-CoV-2 by PCR and was diagnosed with Covid-19 pneumonia.

At the previous hospital, dexamethasone 6 mg was started on the 7th day of illness, followed by remdesivir 200 mg and baricitinib 2 mg on the 9th day. However, on the 10th day of illness, the patient's oxygenation worsened rapidly to SpO₂ 70% under FiO₂ 1.0. High-flow nasal oxygen therapy was then initiated at 40 L/minute, however the patient's condition worsened requiring tracheal intubation and mechanical ventilation. Even after mechanical ventilation, she continued to have severe oxygenation impairment, and subcutaneous emphysema was also observed. Therefore, the patient was transferred to our hospital on the same day and was admitted to the intensive care unit (ICU).

On arrival at our hospital (Day 1), the ventilator settings were FiO₂ 1.0, peak inspiratory pressure 44 cmH₂O and PEEP 20 cmH₂O, but the patient showed severe hypoxemia with SpO₂ 60%. In addition, there was marked subcutaneous emphysema extending from her chest and upper arms to her face, as well as mediastinal emphysema on chest X-ray. After admission to the ICU, the ventilator settings were changed to a peak inspiratory pressure of 37 cmH₂O and PEEP of 15 cmH₂O. However, the emphysema progressed and the patient suffered from severe lung oxygenation deficiency with a PaO₂/FiO₂ ratio (P/F ratio) of 50. Therefore, Veno-venous extracorporeal membrane oxygenation (V-V ECMO) of the right femoral vein to the right internal jugular vein was urgently performed 4 hours after her admission to the ICU. After the start of ECMO, the ventilator settings were FiO₂ 0.4, peak inspiratory pressure 24 cmH₂O, PEEP 12 cmH₂O and respiratory rate 8/minute. Continuous rocuronium infusion was used to prevent exacerbation of emphysema due to cough. We started continuous administration of methylprednisolone 1 mg/kg/day from Day 2 to reinforce the treatment, and the dosage was reduced by half every week.

Although the subcutaneous emphysema had almost disappeared by Day 3 after the start of ECMO, a remarkable atelectasis was seen because the patient was managed by keeping low airway pressure. We performed a bronchoscopy, and observed that most bronchi of the left lung were markedly obstructed by purulent viscous sputum. The chest X-ray after admission to the ICU is shown in Figure 1. We suspected a complication of bacterial pneumonia, so after submitting sputum cultures, Tazobactam/Piperacillin and Vancomycin were started on the same day. In order to prioritize the treatment of bacterial pneumonia and atelectasis, we initiated positional drainage every 4–6 hours and performed daily bronchoscopic sputum aspiration.

In the positional drainage, for the purpose of protecting the right lung from bacteria containing bronchial secretion, the left Sims' position was mainly used until the culture and sensitivity results of sputum were known, and the right lateral supine position was used up to about 10°.

On Day 5, the result of the sputum culture was revealed, and her condition was diagnosed as pneumonia caused by methicillin-sensitive staphylococcus aureus. Therefore, the antibiotic was changed to aminobenzyl penicillin. In addition, continuous rocuronium administration was terminated on the same day, and the peak inspiratory pressure was raised to 30 cmH₂O. Thereafter, no progression of emphysema was observed, and atelectasis and her respiratory status improved, so the patient was weaned from V-V ECMO on Day 7.

After weaning from V-V ECMO, positional drainage was further enhanced and prone therapy was started. Her respiratory condition improved day by day, and she was weaned from mechanical ventilation on Day 15. Immediately after weaning from respirator, the patient required high-flow nasal oxygen therapy. However, after active rehabilitation, the patient was finally discharged from the ICU on Day 21 in a condition that could be managed with nasal cannula oxygen therapy.

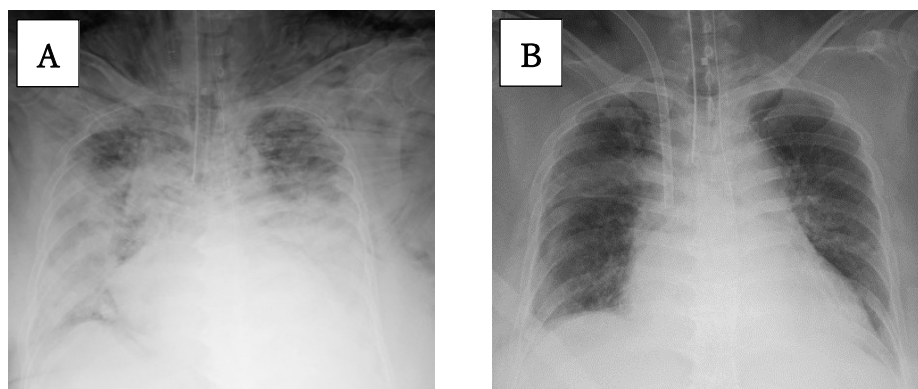


Figure 1. Chest X-ray

(A)Chest X-ray at admission showed decreased permeability in the bilateral lung fields and marked subcutaneous emphysema.

(B)Significant improvement in findings was observed on Day 6.

DISCUSSION

In this case, we treated a highly obese Covid-19 patient with mediastinal emphysema and severe hypoxemia who was successfully rescued by early introduction of ECMO. In general, obese patients require high airway pressure for ventilatory support even under normal conditions due to decreased thoracic compliance. Obesity has also been reported as an important independent risk factor for Covid-19 severity and mortality [2]. The patient in this case was severely obese and had a history of asthma, and had already developed severe mediastinal emphysema when she arrived at the hospital. These factors, in addition to Covid-19 pneumonia, may have contributed to the difficulty of ventilatory management requiring positive airway pressure.

Recent reports suggest that the pathogenesis of severe Covid-19 pneumonia are thrombus formation, angiogenesis [3], and alveolar epithelial cell damage [4]. Although we did not measure sRAGE (soluble form of the receptor for advanced glycation end-products), a marker of alveolar damage, in this patient, we think that severe obesity may have exacerbated the patient's condition rapidly by thrombogenesis. We believe that there are three possible reasons why we were able to rescue this patient. First, ECMO was performed immediately after admission. Second, the patient was relatively young. Third, despite the patient's severe obesity, our staff cooperated well in changing her position.

The fundamental management of critically ill patients with acute respiratory failure consists of artificial ventilation and ECMO, in addition to treatment of the underlying disease. ECMO is a life-sustaining alternative until disease recovery. Respiratory management of ARDS, including severe Covid-19 pneumonia, emphasizes lung protection strategies that avoid excessive ventilation and airway pressure. Ventilator-induced lung injury is associated with a poor prognosis. Regarding the timing of ECMO introduction, the 2018 EOLIA trial and its post

hoc analysis have recently shown that early introduction of ECMO may improve prognosis [5]. The guidelines for ECMO induction are a PEEP of 10 cmH₂O, P/F ratio <150 with Murray score 2–3, or FiO₂ >0.9 with P/F ratio <100. Even in patients with Covid-19, Yang et al. reported that ECMO should be implemented as soon as possible when the P/F ratio is <80 despite being on lung-protective mechanical ventilation and using prone positioning [6]. This case was within these criteria. Furthermore, age has been reported to be an important prognostic factor in non-Covid-19 patients treated with ECMO support for respiratory failure. In particular, the prognosis is reported to be unfavorable in patients aged 65 years or older [7]. The fact that the patient was relatively young may have contributed to the successful outcome of this case.

Some studies have reported that a prone position is effective in severe ARDS [8]. The beneficial effect of prone positioning is likely attributed to better ventilation-perfusion matching, lung recruitment and protection against ventilator-induced lung injury. Adverse events associated with the prone position include facial edema, hemodynamic instability, pressure ulcers and device displacement during repositioning [9]. In mechanical ventilation management of critically ill Covid-19 patients, it has been reported that prone therapy improves oxygenation in 78% of patients and reduces mortality in the group with improved oxygenation [10]. It has also been reported that early prone positioning leads to a higher survival rate [11]. In this case, prone positioning improved oxygenation, so the patient continued to be placed in the prone position during ventilator management. Although the patient weighed 100 kg and it was very labor intensive to place the patient in the prone position, we were able to rescue the patient through team medical care.

We rescued a patient with severe Covid-19 pneumonia who was highly obese. In the management of patients with severe Covid-19 pneumonia, early introduction of ECMO should be considered if oxygenation does not improve with mechanical ventilation, and prone positioning can be effective.

REFERENCES

1. Ramanathan K, Antognini D, Combes A, Paden M, Zakhary B, Ogino M, et al. Planning and provision of ECMO services for severe ARDS during the COVID-19 pandemic and other outbreaks of emerging infectious diseases. *Lancet Respir Med*. 2020;8(5):518–26.
2. Tadayon Najafabadi B, Rayner DG, Shokraee K, Shokraie K, Panahi P, Rastgou P, et al. Obesity as an independent risk factor for COVID-19 severity and mortality. *Cochrane Database Syst Rev*. 2023;5(5):CD015201.
3. Ackermann M, Verleden SE, Kuehnel M, Haverich A, Welte T, Laenger F, et al. Pulmonary Vascular Endothelialitis, Thrombosis, and Angiogenesis in Covid-19. *N Engl J Med*. 2020;383(2):120–8.
4. Kapandji N, Yvin E, Devriese M, de Margerie-Mellon C, Moratelli G, Lemiale V, et al. Importance of Lung Epithelial Injury in COVID-19-associated Acute Respiratory Distress Syndrome: Value of Plasma Soluble Receptor for Advanced Glycation End-Products. *Am J Respir Crit Care Med*. 2021;204(3):359–62.
5. Goligher EC, Tomlinson G, Hajage D, Wijeyesundera DN, Fan E, Jüni P, et al. Extracorporeal Membrane Oxygenation for Severe Acute Respiratory Distress Syndrome and Posterior Probability of Mortality Benefit in a Post Hoc Bayesian Analysis of a Randomized Clinical Trial. *JAMA*. 2018;320(21):2251–9.
6. Yang X, Cai S, Luo Y, Zhu F, Hu M, Zhao Y, et al. Extracorporeal Membrane Oxygenation for Coronavirus Disease 2019-Induced Acute Respiratory Distress Syndrome: A Multicenter Descriptive Study. *Crit Care Med*. 2020;48(9):1289–95.
7. Deatrick KB, Mazzeffi MA, Galvagno SM Jr, Tesoriero RB, Kaczoroswki DJ, Herr DL, et al. Outcomes of venovenous extracorporeal membrane oxygenation when stratified by age: how old is too old? *ASAIO J*. 2020;66(8):946–51.
8. Gattinoni L, Carlesso E, Taccone P, Polli F, Guérin C, Mancebo J. Prone positioning improves survival in severe ARDS: a pathophysiologic review and individual patient meta-analysis. *Minerva Anesthesiol*. 2010;76(6):448–54.
9. Guérin C, Albert RK, Beitler J, Gattinoni L, Jaber S, Marini JJ, et al. Prone position in ARDS patients: why, when, how and for whom. *Intensive Care Med*. 2020;46(12):2385–96.
10. Langer T, Brioni M, Guzzardella A, Carlesso E, Cabrini L, Castelli G, et al. Prone position in intubated, mechanically ventilated patients with COVID-19: a multi-centric study of more than 1000 patients. *Crit Care*. 2021;25(1):128.
11. Mathews KS, Soh H, Shaefi S, Wang W, Bose S, Coca S, et al. Prone Positioning and Survival in Mechanically Ventilated Patients With Coronavirus Disease 2019-Related Respiratory Failure. *Crit Care Med*. 2021;49(7):1026–37.