



Long-term Survival after Treatment of Synchronous Isolated Right External Iliac Lymph Node Metastasis from Ascending Colon Cancer : A Case Report

Okazoe, Yuki ; Omiya, Satoshi ; Nakajima, Takahiro ; Kishi, Atsuhiko ; Kido, Masahiro ; Suzuki, Satoshi ; Fujita, Tsunenori ; Ohno, Masakazu

(Citation)

The Kobe journal of the medical sciences, 69(2):52-56

(Issue Date)

2023

(Resource Type)

departmental bulletin paper

(Version)

Version of Record

(JaLCD0I)

<https://doi.org/10.24546/0100483046>

(URL)

<https://hdl.handle.net/20.500.14094/0100483046>



Long-term Survival after Treatment of Synchronous Isolated Right External Iliac Lymph Node Metastasis from Ascending Colon Cancer: A Case Report

YUKI OKAZOE¹, SATOSHI OMIYA^{2,*}, TAKAHIRO NAKAJIMA¹,
ATSUHIKO KISHI¹, MASAHIRO KIDO², SATOSHI SUZUKI³,
TSUNENORI FUJITA¹, and MASAKAZU OHNO¹

¹*Department of Surgery, Hyogo Prefectural Tamba Medical Center, Tamba, Japan ;*

²*Department of Surgery, Division of Hepato-Biliary-Pancreatic Surgery, Kobe University Graduate School of Medicine, Kobe, Japan;*

³*Department of Gastroenterological Surgery, Hyogo Cancer Center, Akashi, Japan*

**Corresponding author*

Received May 29, 2023/Accepted July 3, 2023

Keywords: Ascending colon cancer, Isolated distant lymph node metastasis, Surgical resection, Case report

BACKGROUND: Synchronous isolated external iliac lymph node metastasis of ascending colon cancer is extremely rare, and its treatment strategy has not been established. In this report, we present a case of long-term survival after surgical resection and adjuvant chemotherapy for ascending colon cancer with synchronous isolated right external iliac lymph node metastasis. **CLINICAL CASE:** A 65-year-old woman with anorexia and anemia was referred to our hospital. Colonoscopy and computed tomography revealed a three-quarter circumferential type 2 tumor from the cecum to the ascending colon, along with regional and right external iliac lymph node swelling. We diagnosed ascending colon cancer with right external iliac artery lymph node metastasis. An open right hemicolectomy with D3 and right external iliac lymph node dissections were performed. Results of histopathological examination showed that both lymph nodes were metastasized from ascending colon cancer. The patient received eight courses of capecitabine and oxaliplatin therapy as adjuvant chemotherapy. At 60 months after surgery, the woman has not had a recurrence. **CONCLUSIONS:** Surgical resection and adjuvant chemotherapy may be an effective treatment strategy for synchronous isolated right external iliac lymph node metastases from ascending colon cancer.

Colorectal cancer (CRC) is one of the leading causes of cancer deaths [1]. Several chemotherapy agents have been successfully applied over the past two decades, with a significantly prolonged median overall survival (OS) of approximately 30 months, including in patients with distant metastases from CRC [2–4]. In CRC, surgical resection has been shown to improve prognosis for liver and lung metastases, with a median OS of up to 65.4 [5] and 69.5 [6] months, respectively, and surgical resection of the primary tumor and metastases is considered standard treatment if resectable. On the other hand, the indication for perioperative chemotherapy for metastatic CRC remains a subject of controversy. Trials such as the EORTC 40983 [7] and JCOG0603 [8], which tested the efficacy of perioperative and adjuvant chemotherapy in liver resection for liver metastases from CRC, demonstrated significant prolongation of progression-free and disease-free survival, respectively, but failed to show an improvement in OS. Nevertheless, perioperative chemotherapy is often administered in clinical practice to treat liver and lung metastases of CRC despite the lack of evidence to support improved OS. Among distant lymph node metastases from CRC, para-aortic lymph node metastases are most common, while external iliac lymph node metastases are extremely rare. Hence, the lack of sufficient cases of external iliac lymph node metastases makes it challenging to establish standard surgical indications and perioperative chemotherapy strategies. In this report, we present a case of long-term survival following surgical resection and adjuvant chemotherapy for ascending colon cancer with synchronous isolated right external iliac lymph node metastasis.

CLINICAL CASE

Informed consent was obtained from the patient for publication of this case report and accompanying images. A 65-year-old woman was referred to our hospital for further examination and treatment due to anorexia, anemia, and a positive fecal occult blood test. Hematobiochemical examination revealed a serum hemoglobin level of 6.5 g/dL. Carcinoembryonic antigen level was elevated to 10.9 ng/mL, and the CA-19-9 level was within the reference range at 6.0 U/mL. Colonoscopy revealed a three-quarter circumferential type 2 tumor extending from the cecum to the ascending colon, histologically defined as a moderately differentiated adenocarcinoma (Figure 1a). Contrast-

enhanced computed tomography revealed circumferential wall thickening from the cecum to the ascending colon and regional lymph node swelling (Figure 1b), and a mass with a diameter of up to 45 mm on the right external iliac artery (Figure 1c).

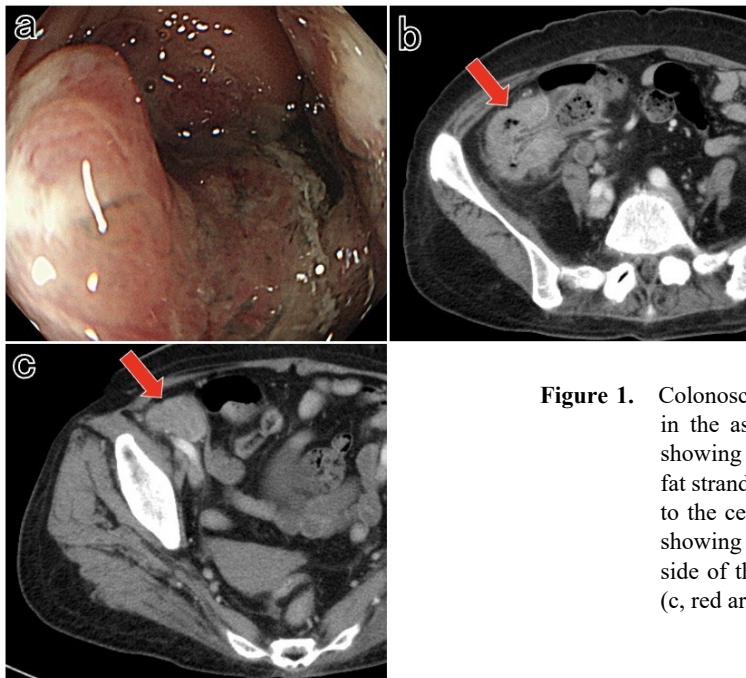


Figure 1. Colonoscopy revealed a type 2 tumor in the ascending colon (a). CT scan showing wall thickening and pericolic fat stranding from the ascending colon to the cecum (b, red arrow). CT scan showing a 4.5 cm mass on the anterior side of the right external iliac vessels (c, red arrow).

Accordingly, we diagnosed ascending colon cancer with right external iliac artery lymph node metastasis. We determined that both the primary tumor and the metastasis to the right external iliac lymph node were resectable [9]. An open right hemicolectomy with D3 and right external iliac lymph node dissections were performed. Intraoperatively, thickening of the lateral parietal peritoneum of the cecum was observed; therefore, the parietal peritoneum and part of the retroperitoneal fat in the affected area were also resected together with the colon. The right external iliac artery was accessed via an extraperitoneal approach through a median abdominal incision and the mass ventral to the artery was removed (Figure 2a). Notably, the mass had not invaded the arteries. The operative time was 261 min, and the blood loss was 135 mL. The surgical specimen showed an almost entirely circumscribed type 2 tumor (95 × 75 mm) extending from the cecum to the ascending colon (Figure 2b). The right external iliac lymph node (45 × 40 mm) was stony hard (Figure 2c).

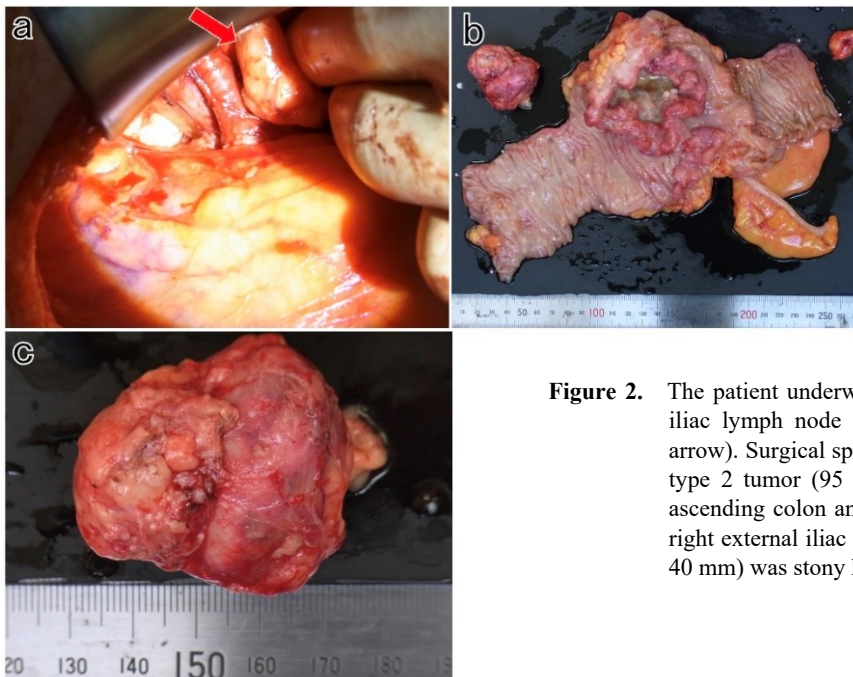


Figure 2. The patient underwent right external iliac lymph node dissection (a, red arrow). Surgical specimen showing a type 2 tumor (95 × 75 mm) in the ascending colon and cecum (b). The right external iliac lymph node (45 × 40 mm) was stony hard (c).

Hematoxylin and eosin staining showed a moderately differentiated adenocarcinoma with subserosa invasion in the ascending colon (Figure 3a). In the four pericolic and two right external iliac lymph nodes, a small amount of lymph node structure was left behind, and a moderately differentiated adenocarcinoma was found, which was subsequently diagnosed as a metastasis from the ascending colon cancer (Figure 3b, c).

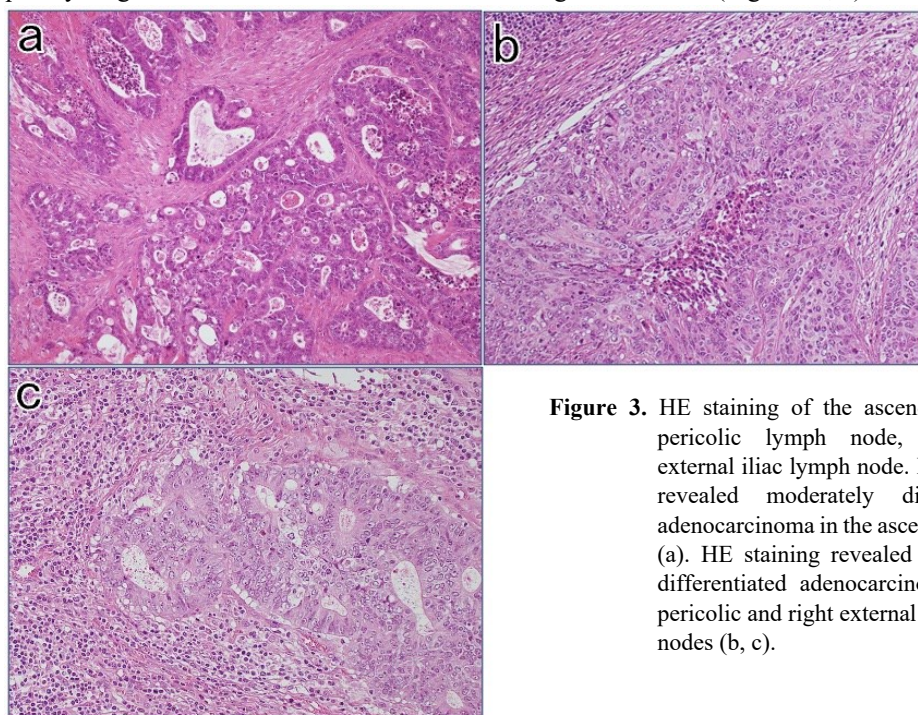


Figure 3. HE staining of the ascending colon, pericolic lymph node, and right external iliac lymph node. HE staining revealed moderately differentiated adenocarcinoma in the ascending colon (a). HE staining revealed moderately differentiated adenocarcinoma in the pericolic and right external iliac lymph nodes (b, c).

The patient was finally diagnosed with stage IV (T3N2aM1a) colon cancer, according to the Union for International Cancer Control 8th edition. The postoperative course was uneventful, and the patient was discharged on postoperative day 16. As adjuvant chemotherapy, the patient received eight courses of capecitabine and oxaliplatin therapy. As of 60 months postoperatively, the patient had not had a recurrence.

DISCUSSION

In right-sided colon cancer, metastasis to the right external iliac lymph nodes is extremely rare. To date, only four cases of right-sided colon cancer and isolated external iliac and/or inguinal lymph node metastasis resection have been described [10–13] (Table I).

Table I. Cases of right external iliac and/or inguinal lymph node metastasis from right-sided colon cancer

No.	Author, Year	Age, Sex	Tumor location	pT, pN	Invasion	Interval	Chemotherapy	Follow-up
1.	Uehara [10], 2007	67, M	C	pT4b, NX	Abdominal wall	Meta, 17 mo	Pre-recurrence	Disease-free, 18 mo
2.	Hara [11], 2013	67, M	C	pT4b, pN1	Abdominal wall	Meta, 36 mo	Pre-recurrence, Adjuvant	Disease-free, 36 mo
3.	Kitano [12], 2017	83, F	A	pT3, pN0	None	Syn	None	Disease-free, 27 mo
4.	Iwata [13], 2020	75, M	A	pT3, pN0	None	Syn	None	Disease-free, 66 mo
5.	Our case, 2023	65, F	A	pT3, pN1	None	Syn	Adjuvant	Disease-free, 60 mo

M, male; F, female; C, cecum; A, ascending colon; Meta, metachronous; Syn, synchronous.

Among these cases, two were attributed to ascending colon cancer and two to cecum cancer. Synchronous metastases were observed in two cases, and metachronous metastases occurred in the other two cases. All four patients were recurrence-free at the time of the report, with survival ranging from 18 to 66 months. Only one patient received adjuvant chemotherapy, which was administered in the case of metachronous metastasis. To our knowledge, this is the first case report of multidisciplinary treatment for synchronous isolated external iliac lymph node metastases from CRC for surgical resection, followed by adjuvant chemotherapy.

The lymphatic pathway responsible for the metastasis of ascending colon to the right external iliac lymph nodes is of particular interest. Abdominal wall lymphatic flow is one possible pathway for metastasis to the external iliac lymph nodes. Uehara et al. proposed that a tumor that invades the abdominal wall may metastasize to the external iliac lymph nodes through the lymphatic pathway adjacent to the right inferior epigastric artery [10]. Although histopathology did not reveal any evidence of tumor invasion to the abdominal wall at the primary site in this case, there was macroscopic suspicion of tumor invasion to the abdominal wall at the time of surgery. It is possible that the tumor was latently invading the abdominal wall or an unknown lymphatic drainage pathway from the right-sided colon to the right external iliac lymph nodes resulted in atypical lymph node metastasis.

The indications for surgery for distant lymph node metastases from CRC remain controversial. Regarding para-aortic lymph node metastases, the most common type of distant lymph node metastasis, Arylward et al. concluded in a systematic review that there are no high-quality data to confidently recommend resection of synchronous para-aortic lymph node metastases in the CRC cohort, but retrospective data suggest a benefit in a very selected cohort [14]. Therefore, in patients with para-aortic lymph node metastases, the current standard of care is a case-by-case evaluation and consideration of whether to resect. Additionally, Mishina et al. reported a 5-year survival rate of 58.6% after resection of extra-hepatopulmonary metastases of colorectal cancer, suggesting that resection may provide benefits [15]. However, it is important to note that the study included only two cases with distant lymph node metastases other than para-aortic lymph node metastases, which cannot be directly applied to this case. The case reports of surgical resection of right-sided colon cancer with right external iliac lymph node metastasis shown in Table I [10–13] all had relatively good prognoses. In this case, the patient has also survived 60 months after resection without recurrence; therefore, surgical resection may be a valid option. However, selection bias in case reports must be considered.

Whether perioperative chemotherapy should be added to surgical resection of distant metastases from CRC is also controversial. Mishina et al. reported that the absence of perioperative chemotherapy was an independent poor prognostic factor following surgical resection in a cohort of CRC patients with extra-hepatopulmonary metastases [15]. The authors suggested that extra-hepatopulmonary metastases may be more systemic than hepatic or pulmonary metastases, as surgery alone was shown to be a predictor of poor OS rates in their study, despite most patients having a low tumor burden [15]. Similarly, Merkel et al. reported that in the case of CRC with distant metastasis to a single organ, patients with distant lymph node metastasis had a worse prognosis than those with liver or lung metastasis [16]. Based on these findings, we think perioperative chemotherapy may be beneficial in cases of isolated external iliac lymph node metastases from CRC, if the patient's general condition allows, as it may have a positive impact on prognosis. Further studies are needed to clarify the efficacy of perioperative chemotherapy in such cases.

CONCLUSIONS

We present a case of long-term survival following surgical resection and adjuvant chemotherapy for ascending colon cancer with synchronous isolated synchronous right external iliac lymph node metastases. Our findings suggest that surgical resection and adjuvant chemotherapy may be effective treatment strategies in similar cases.

REFERENCES

1. Bray F, Ferlay J, Soerjomataram I, Siegel RL, Torre LA, Jemal A. Global cancer statistics 2018: GLOBOCAN estimates of incidence and mortality worldwide for 36 cancers in 185 countries. *CA Cancer J Clin*. 2018;68(6):394–424.
2. Loupakis F, Cremolini C, Masi G, Lonardi S, Zagonel V, Salvatore L, et al. Initial therapy with FOLFOXIRI and bevacizumab for metastatic colorectal cancer. *N Engl J Med*. 2014;371(17):1609–18.
3. Yamada Y, Denda T, Gamoh M, Iwanaga I, Yuki S, Shimodaira H, et al. S-1 and irinotecan plus bevacizumab versus mFOLFOX6 or CapeOX plus bevacizumab as first-line treatment in patients with metastatic colorectal cancer (TRICOLORE): a randomized, open-label, phase III, noninferiority trial. *Ann Oncol*. 2018;29(3):624–31.
4. Yamada Y, Takahari D, Matsumoto H, Baba H, Nakamura M, Yoshida K, et al. Leucovorin, fluorouracil, and oxaliplatin plus bevacizumab versus S-1 and oxaliplatin plus bevacizumab in patients with metastatic

- colorectal cancer (SOFT): an open-label, non-inferiority, randomised phase 3 trial. *Lancet Oncol.* 2013;14(13):1278–86.
5. Viganò L, Capussotti L, Lapointe R, Barroso E, Hubert C, Giuliente F, et al. Early recurrence after liver resection for colorectal metastases: risk factors, prognosis, and treatment. A LiverMetSurvey-based study of 6,025 patients. *Ann Surg Oncol.* 2014;21(4):1276–86.
 6. Iida T, Nomori H, Shiba M, Nakajima J, Okumura S, Horio H, et al. Prognostic factors after pulmonary metastasectomy for colorectal cancer and rationale for determining surgical indications: a retrospective analysis. *Ann Surg.* 2013;257(6):1059–64.
 7. Nordlinger B, Sorbye H, Glimelius B, Poston GJ, Schlag PM, Rougier P, et al. Perioperative FOLFOX4 chemotherapy and surgery versus surgery alone for resectable liver metastases from colorectal cancer (EORTC 40983): long-term results of a randomised, controlled, phase 3 trial. *Lancet Oncol.* 2013;14(12):1208–15.
 8. Kanemitsu Y, Shimizu Y, Mizusawa J, Inaba Y, Hamaguchi T, Shida D, et al. Hepatectomy Followed by mFOLFOX6 Versus Hepatectomy Alone for Liver-Only Metastatic Colorectal Cancer (JCOG0603): A Phase II or III Randomized Controlled Trial. *J Clin Oncol.* 2021;39(34):3789–99.
 9. Watanabe T, Muro K, Ajioka Y, Hashiguchi Y, Ito Y, Saito Y, et al. Japanese Society for Cancer of the Colon and Rectum. Japanese Society for Cancer of the Colon and Rectum (JSCCR) guidelines 2016 for the treatment of colorectal cancer. *Int J Clin Oncol.* 2018;23(1):1–34.
 10. Uehara M, Yamamoto S, Fujita S, Akasu T, Moriya Y, Morisue A. Isolated right external iliac lymph node recurrence from a primary cecum carcinoma: report of a case. *Jpn J Clin Oncol.* 2007;37(3):230–2.
 11. Hara M, Takahashi H, Sato M, Takayama S, Nagasaki T, Takeyama H. Curatively resected isolated inguinal lymph node metastasis from cecum cancer: report of a case. *Surg Today.* 2013;43(1):88–90.
 12. Kitano Y, Kuramoto M, Masuda T, Kuroda D, Yamamoto K, Ikeshima S, et al. Ascending colon cancer with synchronous external iliac and inguinal lymph node metastases but without regional lymph node metastasis: a case report and brief literature review. *Surg Case Rep.* 2017;3(1):32.
 13. Iwata Y, Matsubashi N, Takahashi T, Suetsugu T, Fukada M, Yasufuku I, et al. Ascending colon cancer with synchronous right external iliac lymph node metastasis. *Int Cancer Conf J.* 2020;9(3):162–7.
 14. Aylward C, Noori J, Tyrrell J, O'Sullivan N, Kavanagh DO, Larkin JO, et al. Survival outcomes after synchronous para-aortic lymph node metastasis in colorectal cancer: A systematic review. *J Surg Oncol.* 2023;127(4):645–56.
 15. Mishina T, Uehara K, Ogura A, Murata Y, Aiba T, Mizuno T, et al. Role of resection for extrahepatopulmonary metastases of colon cancer. *Jpn J Clin Oncol.* 2022;52(7):735–41.
 16. Merkel S, Weber K, Croner RS, Golcher H, Göhl J, Agaimy A, et al. Distant metastases in colorectal carcinoma: A proposal for a new M1 subclassification. *Eur J Surg Oncol.* 2016;42(9):1337–42.