Kobe University Repository : Kernel

PDF issue: 2026-11-27

Primary localized cutaneous amyloidosis associated with atopic dermatitis treated successfully with nemolizumab

Fukumoto, Takeshi ; Tanaka, Ryo ; Tanaka, Rio ; Hashimoto, Shinya ; Yoshioka, Ai ; Natsuaki, Satoshi ; Kubo, Akiharu

(Citation)
Journal of the European Academy of Dermatology and Venereology,38(11):e989-e992

(Issue Date)
2024-11

(Resource Type)
journal article

(Version)
Accepted Manuscript

(Rights)
This is the peer reviewed version of the following article: Fukumoto, T., Tanaka, R., Tanaka, R., Hashimoto, S., Yoshioka, A., Natsuaki, S. and Kubo, A. (2024), Primary localized cutaneous amyloidosis associated with atopic dermatitis treated successfully with nemolizumab. J Eur Acad Dermatol Venereol, 38: e989-e992.], which has been…

(URL)
https://hdl.handle.net/20.500.14094/0100489196

Primary localized cutaneous amyloidosis associated with atopic dermatitis treated successfully with nemolizumab

Takeshi Fukumoto[1*], Ryo Tanaka[2], Rio Tanaka[2], Shinya Hashimoto[1], Ai Yoshioka[1], Satoshi Natsuaki[1], Akiharu Kubo[1]

[1]Division of Dermatology, Department of Internal Medicine, Kobe University Graduate School of Medicine, Kobe, Japan

[2] Faculty of Medicine, Kobe University, Kobe, Japan

CORRESPONDING AUTHOR: Takeshi Fukumoto, MD, PhD,

Division of Dermatology, Department of Internal Related, Kobe University Graduate School of Medicine, 7-5-1 Kusunoki-cho, Chuo-ku, Kobe 650-0017, Japan

Tel: +81-78-382-6134; E-mail: fuku@med.kobe-u.ac.jp

RUNNING HEAD: Nemolizumab for PLCA associated with AD

NUMBER OF FIGURES: 2

MANUSCRIPT WORD COUNT: 589 words

KEY WORDS: Atopic dermatitis, primary localized cutaneous amyloidosis, lichen amyloidosis, interleukin-31, nemolizumab

CONSENT FOR PUBLICATION: TF has received payments for lectures from Maruho Co Ltd, AbbVie GK, Eli Lilly Japan KK, Sanofi KK, and Pfizer Japan Inc. AK has received payments for lectures from Maruho Co., Ltd., Sanofi K.K., Torii Pharmaceutical Co., Ltd., UCB Japan Co., Ltd., Janssen Pharmaceutical K.K. AK has received Consulting fees and Payment for expert testimony from Maruho Co., Ltd. Department of Dermatology of Kobe University has received Research grants and contracts from Maruho Co., Ltd., TAIHO PHARMACEUTICAL CO., LTD., UCB Japan Co., Ltd., Otsuka Pharmaceutical Co., Ltd.. The other authors have no disclosures.

DATA AVAILABILITY STATEMENT: The data that support the findings of this study are available from the corresponding author upon reasonable request.

ETHICS STATEMENT : The patients in this manuscript have given written informed consent to the publication of their case details.

Primary localized cutaneous amyloidosis (PLCA) is sometimes associated with atopic dermatitis (AD)[1,2]. Treatment of PLCA associated with AD is challenging, and several treatments have been reported, including dupilumab and upadacitinib[1-3]. However, a gold standard treatment has not been established[1-3]. Nemolizumab, a humanized monoclonal antibody against the IL-31 receptor, was launched on August 8, 2022 in Japan and is used to treat AD[4]; however, it has not been reported whether nemolizumab is effective for PLCA associated with AD. Here, we report a case of PLCA associated with AD that was successfully treated with nemolizumab.

A 67-year-old Japanese man with pediatric-onset AD had a 20-year history of PLCA and severe itch. Physical examination revealed pruritic erythema with lichenification throughout his body and multiple firm hyperpigmented verruciform papules on the extremities (**Fig. 1a-c**). Severe itch disturbed his sleep quality (itch numeric rating scale [NRS] score, 10) (**Fig. 1d**). The itch NRS was used as an indicator of the intensity of the worst itching in the past 24 hours. His total serum IgE was 307 IU/mL (<295 IU/mL), and thymus and activation-regulated chemokine (TARC), a CCR4 ligand that can indicate severity of AD, was 650 pg/mL (<450 pg/mL)[5] (**Fig. 1d**). A biopsy taken from his arm showed hyperkeratosis with acanthosis. Amyloid deposition was observed in the upper dermis by direct fast scarlet (DFS) staining (**Fig. 2a-c**). Systemic

amyloidosis was ruled out because there was no history of familial PLCA and no associated findings on blood, urine, or electrocardiogram tests. The patient was diagnosed with AD with PLCA. Topical treatment with Class II (very strong) or stronger (Class I: strongest) topical corticosteroids and antihistamine medication for several decades had not improved his symptoms[6]. We prescribed nemolizumab (60 mg every 4 weeks) in addition to ongoing topical treatment with Class II topical corticosteroids, not Class I. His severe pruritis markedly improved and Eczema Area and Severity Index (EASI) score decreased (**Fig. 1d**). Papules of PLCA associated with AD started to improve after the first nemolizumab administration (before the second injection). By the fourth month, papules were flattened and reduced in size and number, in parallel with his decreased EASI score (**Fig. 1e-g**); total serum IgE and TARC levels were decreased to 293 IU/mL and 582 pg/mL, respectively (**Fig. 1d**).

Although the pathomechanism of PLCA remains unclear[2,7], amyloid deposition in PLCA is thought to result from scratch-induced apoptotic keratinocyte degeneration. The association between PLCA and AD has been reported[8], and mutations in the *oncostatin M receptor* and *IL-31RA* are linked to familial PLCA[7,8]. Additionally, Dousset *et al.* reported an upregulation of *IL-31* expression in lichen amyloidosis lesions compared to healthy skin[7]. Although an IL-31 signature appears to play a role in pathogenesis in PLCA associated with AD, further studies are required.

Our patient exhibited rapid relief from itching one month after the administration of nemolizumab by inhibiting IL-31 signaling, followed by a gradual improvement in the EASI score, indicating a break in the itch-scratch cycle. Notably, four months post-nemolizumab administration, there was also an improvement in his total serum IgE and TARC levels (**Fig. 1d**). These results showed that nemolizumab worked as a powerful anti-itch agent, improving PLCA appearance as well as AD. Dupilumab and upadacitinib have also been reported to be effective[1-3], suggesting that the effect on this patient may not be due solely to anti-IL-31 action. It remains unclear whether the improvement is due to cessation of scratching behavior after successful anti-itch treatment or specific anti-IL-31 action. More cases are needed to determine which agent is the best to treat PLCA associated with AD.

Figure legends

Fig. 1. Clinical information of primary localized cutaneous amyloidosis in a patient with atopic dermatitis pre- and post-nemolizumab treatment.

(a-c) Multiple, pruritic, hyperpigmented, lichen papules with a cobblestone appearance on the extremities during treatment with topical corticosteroids and antihistamine medication prior to nemolizumab administration. **(d)** Decrease in the Eczema Area and Severity Index and itch numeric rating scale scores following 4 months of nemolizumab administration from baseline (pre-treatment). **(e-g)** Following subcutaneous injections of nemolizumab, the papules appeared to have flattened and reduced in size and number.

Fig. 2. Histopathological information of primary localized cutaneous amyloidosis in a patient with atopic dermatitis pre-nemolizumab treatment.

(a, b) Hematoxylin and eosin staining indicating hyperkeratotic, slightly elevated acanthosis and superficial perivascular lymphoid infiltrates with amorphous eosinophilic material in the papillary dermis [a: low magnification, b: high magnification, scale bar = 100 μm]. **(c)** Positive results of a direct fast scarlet staining in the upper dermis beneath the site of the slightly elevating acantholytic epidermis with amorphous eosinophilic material with hematoxylin and eosin staining [high magnification, scale bar = 100 μm].

References

1. Aoki, K., Ohyama, M., and Mizukawa, Y. (2021). A case of lichen amyloidosis associated with atopic dermatitis successfully treated with dupilumab: A case report and literature review. Dermatol Ther *34*, e15005. 10.1111/dth.15005.
2. Zahid, S., Saussine, A., Calugareanu, A., Jachiet, M., Vignon-Pennamen, M.D., Rybojad, M., Bagot, M., Bouaziz, J.D., and Mahevas, T. (2022). Dramatic response to dupilumab in papular amyloidosis. J Eur Acad Dermatol Venereol *36*, e1071-e1072. 10.1111/jdv.18482.
3. Solimani, F., Dilling, A., Ghoreschi, F.C., Nast, A., Ghoreschi, K., and Meier, K. (2023). Upadacitinib for treatment-resistant Lichen amyloidosis. J Eur Acad Dermatol Venereol *37*, e633-e635. 10.1111/jdv.18756.
4. Kabashima, K., Matsumura, T., Komazaki, H., Kawashima, M., and Nemolizumab, J.P.S.G. (2020). Trial of Nemolizumab and Topical Agents for Atopic Dermatitis with Pruritus. N Engl J Med *383*, 141-150. 10.1056/NEJMoa1917006.
5. Jahnz-Rozyk, K., Targowski, T., Paluchowska, E., Owczarek, W., and Kucharczyk, A. (2005). Serum thymus and activation-regulated chemokine, macrophage-derived chemokine and eotaxin as markers of severity of atopic dermatitis. Allergy *60*, 685-688. 10.1111/j.1398-9995.2005.00774.x.
6. Komura, Y., Kogure, T., Kawahara, K., and Yokozeki, H. (2018). Economic assessment of actual prescription of drugs for treatment of atopic dermatitis: Differences between dermatology and pediatrics in large-scale receipt data. J Dermatol *45*, 165-174. 10.1111/1346-8138.14133.
7. Dousset, L., Seneschal, J., Boniface, K., Charreau, S., Ezzedine, K., Milpied, B., Mossalayi, M.D., McGrath, J.A., Lecron, J.C., and Taieb, A. (2015). A Th2 cytokine interleukin-31 signature in a case of sporadic lichen amyloidosis. Acta Derm Venereol *95*, 223-224. 10.2340/00015555-1829.
8. Chia, B., Tan, A., and Tey, H.L. (2014). Primary localized cutaneous amyloidosis: association with atopic dermatitis. J Eur Acad Dermatol Venereol *28*, 810-813. 10.1111/jdv.12144.

Figure 1, Fukumoto et al.

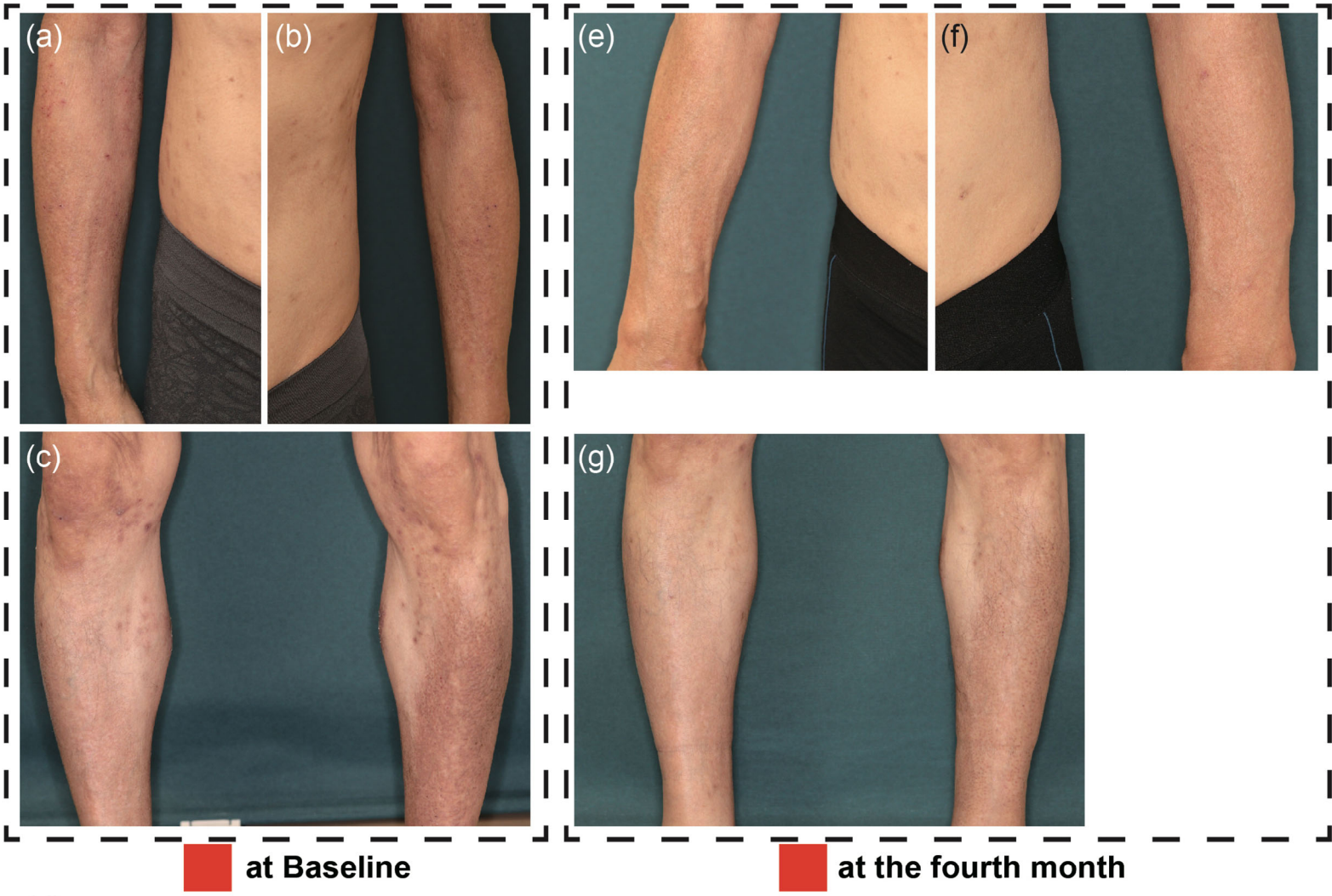

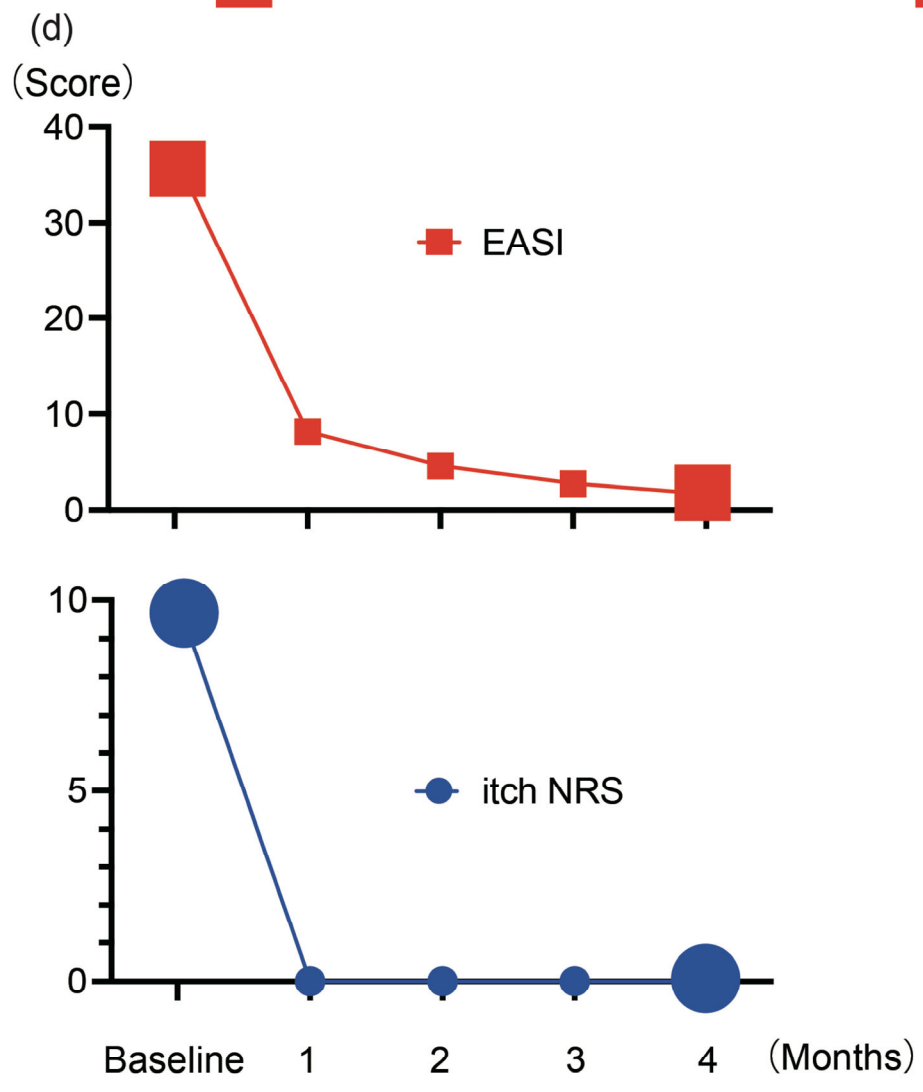

Total serum IgE=307 (IU/mL)

TARC=650 (pg/mL)

at Baseline

Total serum IgE=293 (IU/mL)

TARC=582 (pg/mL)

at the fourth month

Figure 2, Fukumoto et al.

