Kobe University Repository : Kernel

PDF issue: 2026-11-27

Half-time photodynamic therapy for serous pigment epithelium detachment: anatomical and functional outcomes

Kishimoto-Kishi, Maya ; Miki, Akiko ; Oka, Toshiki ; Ikeuchi, Eisuke ; Masuda, Risa ; Yamada, Hiroko ; Imai, Hisanori ; Nakamura, Makoto

(Citation)
Photodiagnosis and Photodynamic Therapy,56:105269

(Issue Date)
2025-12

(Resource Type)
journal article

(Version)
Version of Record

(Rights)
© 2025 The Authors. Published by Elsevier B.V.
This is an open access article under the Creative Commons Attribution 4.0 International license

(URL)
https://hdl.handle.net/20.500.14094/0100499327

Photodiagnosis and Photodynamic Therapy 56 (2025) 105269

Contents lists available at ScienceDirect

Photodiagnosis and Photodynamic Therapy

journal homepage: www.elsevier.com/locate/pdpdt

Half-time photodynamic therapy for serous pigment epithelium detachment: anatomical and functional outcomes

Maya Kishimoto-Kishi [a], Akiko Miki [a,*], Toshiki Oka [a], Eisuke Ikeuchi [a], Risa Masuda [a], Hiroko Yamada [a], Hisanori Imai [b], Makoto Nakamura [a]

[a] Department of Surgery, Division of Ophthalmology, Kobe University Graduate School of Medicine, Kobe, Japan
[b] Department of Ophthalmology, Kansai Medical University, 2-5-1, Shin-machi, Hirakata, 573-1191, Japan

ARTICLE INFO

Keywords:
Central serous chorioretinopathy
Photodynamic therapy
Half-time photodynamic therapy
Pigment epithelium detachment

ABSTRACT

Objective: This study aims to investigate the efficacy of half-time photodynamic therapy (htPDT) in eyes with serous pigment epithelium detachment (PED).
Methods: This retrospective study included 17 eyes from 17 patients who underwent htPDT for serous PED with choroidal vascular hyperpermeability (CVH). Visual acuity (VA), metamorphopsia, and optical coherence tomography (OCT) parameters were assessed before and at 6 months after treatment. Metamorphopsia was quantified using M-CHART.
Results: The study population consisted of 13 males (13 eyes), with a mean age of 55.3 ± 14.9 years. At baseline, VA (logMAR) was 0.05 ± 0.14, the height of PED was 226.5 ± 154.2 μm, and the M-CHARTS score was 0.78 ± 0.64° At the six-month follow-up, VA improved to -0.02 ± 0.15 ($P = 0.026$), the height of PED decreased to 31.1 ± 52.7 μm ($P < 0.001$), and the M-CHARTS score improved to 0.26 ± 0.29° ($P < 0.01$). Additionally, PED resolution was observed in 11 of the 17 eyes. Both VA and M-CHARTS score at 6 months showed significant associations with baseline M-CHARTS score ($P = 0.047$ and 0.04, respectively). Eyes with resolved PED had significantly greater baseline interocular central choroidal thickness (CCT) differences compared to those with persistent PED.
Conclusions: HtPDT is useful for improving retinal morphology and visual function in patients with serous PED. Baseline metamorphopsia serves as a predictor for VA and metamorphopsia following htPDT. Additionally, eyes with greater interocular CCT differences may be more likely to experience resolution of PED following treatment.

1. Introduction

Pigment epithelium detachment (PED) represents a challenging clinical entity characterized by the separation between the basal lamina of the retinal pigment epithelium (RPE) and the underlying inner collagenous Bruch's membrane [1]. The space created by this separation may be occupied by various substances, including blood, serous exudate, drusenoid material, fibrovascular tissue, or a combination of these. Additionally, the presence of subretinal fluid may also be observed. Zayit-Soudry et al. [2] classified PEDs into serous (vascular or nonvascular), fibrovascular, and drusenoid. Serous PEDs are frequently observed in cases of age-related macular degeneration (AMD) and central serous chorioretinopathy (CSC) [3,1]. In cases of CSC, PED has been identified in over 50 % of affected eyes [4–6]. PED may present in isolation or in conjunction with subretinal fluid in CSC [7,6]. PEDs associated with CSC often co-localize with areas exhibiting dilated, large choroidal vessels and thickened choroid on spectral domain optical coherence tomography (SD-OCT), as well as with choroidal vascular hyperpermeability (CVH) on indocyanine green angiography (ICGA) [8,5], thereby supporting the hypothesis that choroidal congestion and hyperpermeability play critical roles in the development of PED.

Although eyes with PED associated with CSC generally demonstrate favorable visual prognoses, the extension of the lesion to the fovea may lead to a decline in visual acuity (VA) due to RPE atrophy [9,10]. Additionally, cases accompanied by metamorphopsia are frequently observed in clinical practice. Consequently, subfoveal PEDs can result in significant visual impairment, including decreased VA and metamorphopsia, which greatly impact patients' quality of life and daily

This research did not receive any specific grant from funding agencies in the public, commercial, or not-for-profit sectors.
* Corresponding author.
E-mail address: acacyey@med.kobe-u.ac.jp (A. Miki).

https://doi.org/10.1016/j.pdpdt.2025.105269
Received 12 September 2025; Received in revised form 9 October 2025; Accepted 5 November 2025
Available online 6 November 2025
1572-1000/© 2025 The Authors. Published by Elsevier B.V. This is an open access article under the CC BY license (http://creativecommons.org/licenses/by/4.0/).

activities [9,11,12].

Current management strategies for serous PED remain limited. The choice of treatment for serous PED largely depends on its underlying etiology. When serous PED arises secondary to CSC, management strategies may include systemic carbonic anhydrase inhibitors. In contrast, when the PED is vascularized and associated with AMD, anti-vascular endothelial growth factor (VEGF) agents or photodynamic therapy (PDT) are typically considered as the main treatment options. Therefore, clarifying the underlying cause of serous PED is essential in determining the most appropriate therapeutic approach. Although spontaneous resolution of PED may occur, it has been reported that the chance of resolution of PED is twice as high with PDT compared to observation without treatment [11]. While anti- VEGF therapy has shown limited efficacy for avascular PED [13], PDT has emerged as a potentially effective treatment by targeting the underlying CVH. Half-dose PDT (hdPDT), a modification of the standard PDT protocol, has demonstrated favorable outcomes in treating serous PED [14,11,15]. An alternative modification—half-time PDT (htPDT), which reduces the duration of laser exposure to 42 s—has shown potential in treating CSC but has yet to be systematically evaluated for serous PED [16,17].

Quantitative assessments of functional outcomes beyond visual acuity (VA) remain underexplored in studies addressing PED treatment. Metamorphopsia, despite being a primary complaint among patients with PED, has rarely been systematically evaluated both prior to and following treatment [18,19]. Understanding both anatomical and functional outcomes, including changes in metamorphopsia, is essential for optimizing treatment strategies. Furthermore, the effectiveness of improving metamorphopsia has only been evaluated based on subjective symptoms, lacking quantitative assessment.

This study aims to investigate the efficacy of htPDT in treating serous PED with CVH, through a comprehensive evaluation of anatomical outcomes, VA, and the degree of metamorphopsia.

2. Materials and methods

All investigations adhered to the tenets of the Declaration of Helsinki. The study protocol was approved by the Institutional Review Board of Kobe University Hospital, and informed consent was obtained through an opt-out process on the website.

We retrospectively reviewed 17 eyes of 17 consecutive patients with serous PED, who were treated with htPDT at Kobe University Hospital between December 2012 and October 2024. The diagnosis of serous PED was made based on multimodal imaging [1]. In brief, serous PEDs were identified as circular elevations of the RPE with sharply demarcated borders and a clear to yellowish-orange coloration. On OCT, they appeared as abrupt elevations of the RPE with an underlying hyporeflective sub-RPE space corresponding to serous fluid accumulation. On fluorescein angiography (FA), serous PEDs demonstrated early, intense hyperfluorescence with pooling of dye within the detachment and persistent late-phase staining. Indocyanine green angiography (ICGA) revealed corresponding hypofluorescent lesions. Our inclusion criteria were as follows: (1) presence of PED involving the fovea on OCT, (2) observation of at least a 6-month follow-up following htPDT, (3) no subretinal fluid or little at the extra fovea, (3) presence of CVH on ICGA, and (4) presence of metamorphopsia and/or visual disturbance. The exclusion criteria were (1) previous history of treatment including laser photocoagulation, photodynamic therapy (PDT) or anti-VEGF treatment, (2) presence of choroidal neovascularization or polypoidal lesion at macula on FA and ICGA, (3) presence of drusen on OCT and fundus color photograph, except for pachydrusen [20]. Although CVH is a characteristic finding frequently observed in eyes with CSC, we analyzed serous PED with CVH as a distinct clinical entity to specifically evaluate the therapeutic effect of PDT in this subgroup. Cases with typical CSC-associated subretinal fluid or leakage on FA were excluded to avoid diagnostic overlap.

All patients received htPDT as previously described [16]. The irradiation area was adjusted to cover the area of PED by adding a diameter of 1000 μm, which corresponds to the area of greatest linear diameter. Best-corrected visual acuity (BCVA) and metamorphopsia were measured, and OCT scans were performed at baseline and 6 months after treatment. BCVA was measured as decimal visual acuity. Metamorphopsia was assessed using the M-CHARTS as previously described [19]. FA and ICGA were performed using the Spectralis OCT System (Heidelberg Spectralis HRA2; Heidelberg Engineering GmbH). Macular 6-line radial scan and 31-line raster scan with enhanced depth imaging (EDI) were performed using the Spectralis OCT system (Heidelberg Spectralis OCT; Heidelberg Engineering GmbH, Heidelberg, Germany). We quantified the following parameters before and after htPDT based on OCT images: central choroidal thickness (CCT), height of PED at the fovea, maximum height of PED, maximum diameter of PED, and area of PED.

We measured OCT parameters according to our previous report [19]. The following clinical data were recorded in this study: vertical, horizontal, and average M-CHARTS score, BCVA, and OCT parameters at baseline and 6 months after htPDT. The definition of eyes with 'resolved eyes' was eyes with flattened PED. Eyes without flattened PED were defined as eyes with 'persistent PED'. Resolved eyes were also defined as demonstrating "treatment success". Recurrence was defined as the re-elevation of PED.

Decimal visual acuity was converted into logMAR units for statistical analyses. The differences in logMAR BCVA, M-CHARTS score, and OCT parameters before and after htPDT were analyzed using the Wilcoxon signed-rank test. Spearman's rank correlation test was used to examine the association between M-CHARTS score or VA at 6 months after htPDT and clinical parameters before or after htPDT. The comparison between eyes with resolved PED and those with persistent PED were analyzed using Mann-Whitney U test. A P value <0.05 was considered statistically significant. Statistical analyses were conducted using SPSS software, version 29.0 (IBM Corp., Armonk, NY, USA).

3. Results

A total of 17 eyes of 17 patients were included in this study. Table 1 shows the clinical characteristics of the patients.

The mean age was 55.3 ± 14.9 years with a male proportion of 13 out of 17 patients (76.4 %). Following htPDT, the BCVA improved significantly at 6 months post-PDT (-0.02 ± 0.15) compared to the baseline (0.05 ± 0.14) (P = 0.026) (Fig. 1 a). At baseline, the vertical, horizontal, and average M-CHARTS scores were 0.77 ± 0.67°, 0.78 ± 0.70°, and 0.78 ± 0.64°, respectively. They significantly improved to 0.26 ± 0.31°, 0.25 ± 0.31°, and 0.26 ± 0.29° at 6 months post-PDT, respectively (all P < 0.01) (Fig. 1 b-d).

All OCT parameters, including the height of PED at the fovea, maximum height of PED, maximum diameter of PED, PED area, and CCT, demonstrated significant reductions at 6 months post-PDT when compared to baseline values (height of PED at the fovea and maximum height of PED: P < 0.001; maximum diameter of PED, PED area, CCT: P < 0.01) (Table 2).

At 6 months post-PDT, PED resolved completely in 11 eyes, decreased in height in 2 eyes, and remained unchanged in 4 eyes. For

Table 1
Patient Characteristics and clinical features at the baseline.

No. of cases	17 eyes of 17 patients
Age (years)	55.3±15.3
Gender (male/female), no.	13/4
Disease duration (months)	34.1±28.3
Initial visual acuity (logMAR)	0.05±0.14
M-CHARTS metamorphopsia score (degrees)	0.78±0.64

logMAR=logarithm of the minimum angle of resolution. Values are presented as mean ± standard deviation.

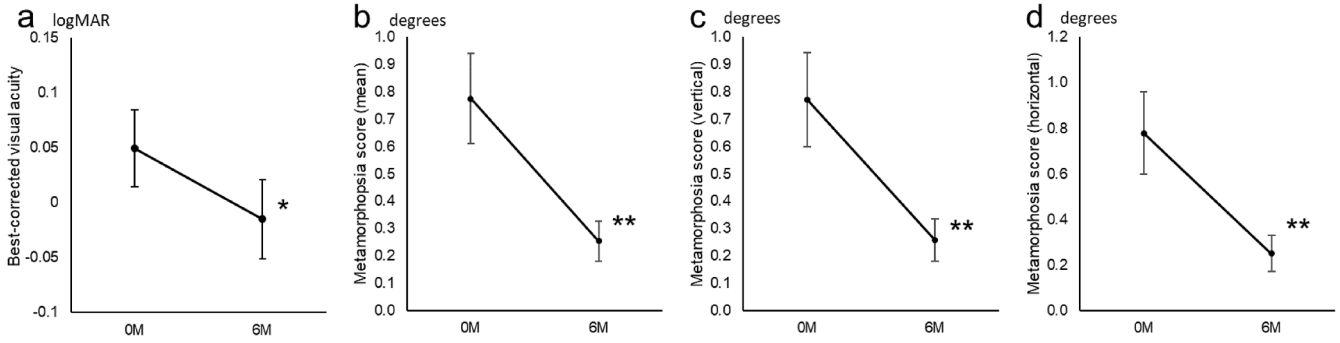

Fig. 1. Changes in BCVA and M-CHARTS score before and after htPDT. (a) Best-corrected visual acuity (logMAR). (b) Mean M-CHARTS score (degree). (c) Vertical M-CHARTS score (degree). (d) Horizontal M-CHARTS score (degree). Vertical bars represent standard errors at each time point. P values were calculated using the Wilcoxon signed-rank test to compare BCVA and M-CHARTS score between baseline and at 6 months after treatment. Visual functions significantly improved after htPDT (*p<0.05; **p<0.01).

Table 2
Changes in morphological parameters pre- and post-htPDT.

	Baseline	6monhts post-PDT
Height of PED at the fovea (μm)	215.5±160.9	29.2±53.2**
Maximum height of PED (μm)	283.5±158.8	56.7±83.3**
Maximum diameter of PED (μm)	1319.4 ±765.5	601.3±1255.0*
PED area (mm^2)	1.6±2.0	1.4±4.7*
Central choroidal thickness (μm)	435.6±104.8	360.2±70.8*
Central choroidal thickness in the fellow eye (μm)	402.7±134.0	-

PED=pigment epithelium detachment. Values are presented as mean ± standard deviation. Significant difference compared with baseline (0 M): *p<0.01, **p<0.001 (Wilcoxon signed-rank test).

adverse events, no eyes exhibited RPE tear or retinal hemorrhage. During the 6-month follow-up, no eyes developed subretinal fluid (SRF) following PDT. A typical case is shown in Fig. 2.

We further analyzed the correlation between the BCVA at 6 months post-PDT and clinical parameters at baseline and at 6 months post-PDT, as well as the correlation between the M-CHARTS scores at 6 months post-PDT and clinical parameters at baseline and at 6 months post-PDT. Our findings indicated that baseline BCVA and M-CHARTS scores correlated significantly with BCVA at 6 months post-PDT ($P < 0.001$ and $P = 0.047$, respectively), whereas only the baseline M-CHARTS score significantly correlated with the M-CHARTS score at 6 months post-PDT ($P = 0.04$) (Table 3). Conversely, both BCVA and M-CHARTS scores at 6 months post-PDT did not correlate significantly with any clinical or morphological parameters at the same time point (Table 4)

Additionally, we evaluated the clinical and OCT parameters between eyes with resolved PED and those with persistent PED, revealing a significant difference in baseline interocular CCT difference between the two groups ($P = 0.034$) (Table 5).

4. Discussion

The present study demonstrates the significant efficacy of htPDT in the management of serous PED with CVH. Complete resolution of the PED was observed in 11 of the 17 eyes (64.7 %) during the 6-month follow-up. Comparable findings were reported in the previous study by Inoda et al. [15] with PED disappearance in 58 % of cases using hdPDT. HtPDT is as effective as hdPDT for serous PED. Reduced fluence PDT, including hdPDT and htPDT, has demonstrated effectiveness in CSC [21,22,16]. Liu et al. [21] compared the efficacy of hd-PDT and ht-PDT in eyes with CSC and concluded that both modalities exhibited comparable effectiveness in improvement of VA and resolution of SRF. However, ht-PDT demonstrated a marginal advantage in terms of the time to SRF resolution and the rate of SRF recurrence.

In the current study, we did not directly assess the treatment efficacy of hd-PDT versus ht-PDT for serous PED; however, ht-PDT may exhibit

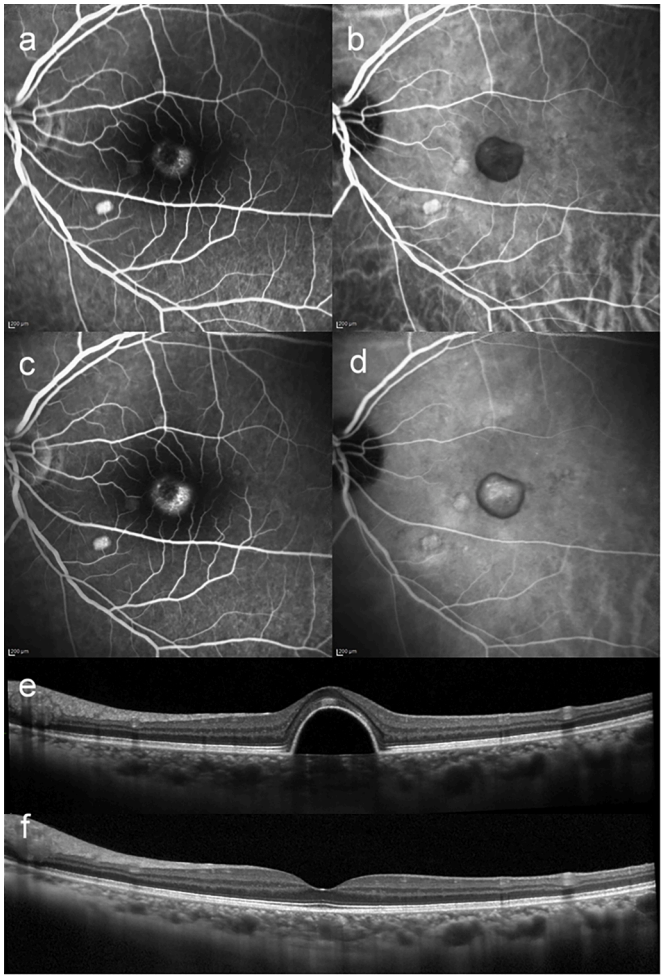

Fig. 2. Representative case images. At baseline, middle-phase fluorescein angiography (a) demonstrates hyperfluorescence, which persists in late-phase fluorescein angiography (c) at the PED. Baseline middle-phase indocyanine green angiography (b) demonstrates hypofluorescence at the PED. Late-phase indocyanine green angiography (d) demonstrates hyperfluorescence due to choroidal vascular hyperpermeability at the PED. Baseline optical coherence tomography (OCT) (e) reveals a serous PED involving the fovea. After 6 months post-PDT, OCT (f) shows resolution of the PED.

Table 3
Associations of Post-htPDT BCVA and M-CHARTS score with baseline clinical and OCT parameters.

	BCVA at 6 months post-PDT		M-CHARTS score at 6 months post-PDT	
	R	p-value	R	p-value
Disease duration (months)	0.228	0.378	-0.214	0.462
BCVA (logMAR)	0.729	**<0.001***	-0.017	0.953
M-CHARTS score, Mean (degrees)	-0.539	**0.047***	0.554	**0.040***
Central choroidal thickness (μm)	0.269	0.297	0.433	0.122
Interocular CCT difference (affected - fellow eye) (μm)	-0.026	0.927	-0.384	0.217
Height of PED at the fovea (μm)	0.134	0.608	0.284	0.325
Maximum height of PED (μm)	-0.264	0.306	-0.023	0.939
Maximum diameter of PED (μm)	0.13	0.619	-0.038	0.897
PED area (mm2)	0.189	0.467	0.255	0.38

BCVA=best-corrected visual acuity; logMAR=logarithm of the minimum angle of resolution; CCT=central choroidal thickness; PED=pigment epithelium detachment. Values are presented as mean ± standard deviation. *Significant correlation between parameters (Spearman rank correlation test).

Table 4
Associations of Post-htPDT BCVA and M-CHARTS score with clinical and PED morphological parameters at 6 months after treatment.

	BCVA at 6 months post-PDT		M-CHARTS score at 6 months post-PDT	
	R	p-value	R	p-value
BCVA (logMAR)	-	-	-0.083	0.779
M-CHARTS score (mean)	-0.083	0.779	-	-
Height of PED at the fovea (μm)	0.112	0.668	0.238	0.412
Maximum height of PED (μm)	0.027	0.919	0.223	0.444
Maximum diameter of PED (μm)	0.155	0.552	0.279	0.334
PED area (mm2)	0.167	0.522	0.223	0.444

BCVA=best-corrected visual acuity; logMAR=logarithm of the minimum angle of resolution; PED=pigment epithelium detachment. Values are presented as mean ± standard deviation.

Table 5
Associations of post-htPDT PED status with clinical and OCT Parameters before treatment.

	PED Resolved (n=11)	PED Persistent (n=6)	p-value
Age	51.3±15.7	62.7±12.5	0.159
Disease duration (months)	30.5±23.9	40.8±36.6	0.615
Baseline BCVA (logMAR)	0.05±0.15	0.04±0.16	0.877
Baseline M-CHARTS score, (degrees)	0.77±0.72	0.78±0.24	0.696
Baseline central choroidal thickness (μm)	433.1±115.7	409.4±71.3	0.841
Baseline choroidal thickness in fellow eye (μm)	344.4±91.9	463.8±157.6	0.126
Baseline interocular CCT difference (affected - fellow eye) (μm)	93.8±143.1	-55.6±103.8	**0.034***
Baseline height of PED at the fovea (μm)	223.5±146.5	200.8±198.4	0.687
Baseline maximum height of PED (μm)	284.3±111.7	282.2±236.1	0.421
Baseline maximum diameter of PED (μm)	1200.2±624.8	1538.0 ±1002.9	0.421
Baseline PED area (mm^2)	1.26±0.89	2.28±3.29	0.615
BCVA at 6 M (logMAR)	-0.02±0.16	-0.00±0.14	0.717
M-CHARTS score at 6 M (degrees)	0.24±0.30	0.33±0.28	0.338

BCVA=best-corrected visual acuity; logMAR=logarithm of the minimum angle of resolution; CCT=central choroidal thickness; PED=pigment epithelium detachment. Values are presented as mean ± standard deviation. *A statistically significant difference was observed between the two groups (Mann–Whitney U test).

superiority over hd-PDT regarding the different rates of PED flattening even in cases with serous PED.

Serous PED with CVH frequently exhibits clinical and angiographic characteristics similar to those observed in CSC. However, the clinical course and therapeutic response to PDT in eyes primarily characterized by serous PED rather than subretinal fluid may differ from the typical presentations of CSC. Therefore, in the present study, we classified serous PED with CVH as a distinct clinical entity. This approach allowed us to focus on the specific response pattern of serous PED to PDT while minimizing the potential confounding effects of concomitant CSC-related manifestations.

Understanding the factors that predict the resolution of PED following htPDT is important for patient selection and the establishment of personalized treatment strategies. A significant finding from this study concerns the role of baseline choroidal thickness in predicting PED resolution. Specifically, eyes in which the PED resolved after treatment exhibited significantly greater baseline interocular CCT differences compared to those with persistent PED. Inoda et al. [15] found that the treatment response factor for hdPDT for non-neovascular PED was a pre-treatment choroidal thickness of >350um in the affected eye or a difference of 100um from the bilateral eye. In cases of CSC, the affected eye had a significantly thicker choroid than both the normal eye and the fellow eye [23,24]. The fellow eye was also reported to have a thicker choroid than the normal eye [23,24]. In cases of CSC, bilateral involvement has been identified as a significant factor contributing to recurrence following hdPDT. Additionally, interstitial choroidal thickening in the fellow eye has been recognized as a determinant of the persistence of SRF during observation [25,26]. Consequently, the condition of the fellow eye emerges as an important prognostic factor in CSC. Conversely, given the variability in choroidal thickness among individuals – affected by factors such as refractive status, diurnal variation, and gender [27]- it would be beneficial to investigate each patient by comparing values in the affected eye to those in the fellow eye.

Following htPDT, VA demonstrated significant improvement, consistent with previous reports regarding serous PED treated with hdPDT [14,15]. This improvement in VA reflects the impact of the PED on the overlying photoreceptors. Furthermore, structural changes, including the flattening of the PED, are essential for preserving long-term retinal integrity and preventing secondary photoreceptor damage.

In addition to standard VA measurements, the M-CHARTS score provides a valuable quantitative assessment of symptoms associated with PED. While there have been reports of improved symptoms following htPDT [14], this has not been quantitatively investigated. In the present study, we quantitatively evaluated metamorphopsia before and after treatment using M-CHARTS score. Regarding the relationship between M-CHARTS and subjective symptoms, it has been reported that approximately 80 % of patients with macular disease do not experience any difficulties in daily life activities when the M-CHARTS score is less than 0. 5° [28]. At baseline, the mean M-CHARTS score was 0.78 ± 0.64°, indicating a notable degree of metamorphopsia experienced by patients. Following htPDT, this score significantly improved to 0.26 ± 0.29° at 6 months. This substantial reduction in M-CHARTS scores directly correlates with an improvement in the quality of vision.

BCVA at 6 months was significantly associated with baseline VA ($P < 0.001$). This finding indicates that patients with better baseline VA are more likely to have better final visual outcomes, highlighting the importance of timely intervention for those exhibiting VA deterioration. Furthermore, BCVA at 6 months was significantly associated with the baseline M-CHARTS score ($P = 0.047$), suggesting that patients with a lesser degree of metamorphopsia may have a greater potential for improvement in VA. Additionally, the M-CHARTS score at 6 months was significantly associated with the baseline M-CHARTS score ($P = 0.04$), suggesting that patients with a greater degree of metamorphopsia prior to treatment are more likely to experience residual metamorphopsia that adversely affects their daily activities.

4.1. Limitations

This investigation has several limitations, including the relatively small sample size, the retrospective nature of the study design, and a short-term follow-up period. Future studies with a larger sample size and a longer follow-up period, comparing hdPDT versus htPDT, as well as htPDT and observation, are required.

4.2. Conclusion

HtPDT was effective in both anatomic and functional improvement for serous PED with CVH. The baseline interocular difference in CCT serves as a predictor for the flattening of PED following htPDT. Furthermore, patients with a lesser degree of metamorphopsia prior to treatment may experience improvements in both metamorphopsia and VA following treatment.

CRediT authorship contribution statement

Maya Kishimoto-Kishi: Writing – original draft, Formal analysis, Data curation. **Akiko Miki:** Writing – review & editing, Methodology, Conceptualization. **Toshiki Oka:** Data curation. **Eisuke Ikeuchi:** Data curation. **Risa Masuda:** Data curation. **Hiroko Yamada:** Data curation. **Hisanori Imai:** Supervision, Methodology. **Makoto Nakamura:** Supervision.

References

[1] S.S.D. Mrejen, S.K. Mukkamala, K.B. Freund, Multimodal imaging of pigment epithelial detachment: a guide to evaluation, Retina 33 (9) (2013) 1735–1762, https://doi.org/10.1097/IAE.0b013e3182993f66.

[2] S. Zayit-Soudry, I. Moroz, A. Loewenstein, Retinal pigment epithelial detachment, Surv. Ophthalmol. 52 (3) (2007) 227–243, https://doi.org/10.1016/j.survophthal.2007.02.008. PMID: 17472800.

[3] F. Gomez-Ulla, J.M. Vazquez, M.J. Rodriguez-Cid, J. Des, F. Gonzalez, Central serous chorioretinopathy following pigment epithelium detachment: fluorescein and indocyanine green angiography follow-up, Acta Ophthalmol. Scand. 78 (2) (2000) 232–234, https://doi.org/10.1034/j.1600-0420.2000.078002232.x. PMID: 10794266.

[4] K. Mitarai, F. Gomi, Y. Tano, Three-dimensional optical coherence tomographic findings in central serous chorioretinopathy, Graefes. Arch. Clin. Exp. Ophthalmol. 244 (11) (2006) 1415–1420, https://doi.org/10.1007/s00417-006-0277-7. PMID: 16596405.

[5] L. Yang, J.B. Jonas, W. Wei, Optical coherence tomography-assisted enhanced depth imaging of central serous chorioretinopathy, Invest. Ophthalmol. Vis. Sci. 54 (7) (2013) 4659–4665, https://doi.org/10.1167/iovs.12-10991. PMID: 23737472.

[6] M.E. van Velthoven, F.D. Verbraak, P.M. Garcia, R.O. Schlingemann, R.B. Rosen, MD. de Smet, Evaluation of central serous retinopathy with en face optical coherence tomography, Br. J. Ophthalmol. 89 (11) (2005) 1483–1488, https://doi.org/10.1136/bjo.2005.073056. PMID: 16234458.

[7] A S-SB Giovannini, E. D'Altobrando, C. Mariotti, T. Rutili, R. Tittarelli, Choroidal findings in the course of idiopathic serous pigment epithelium detachment detected by indocyanine green videoangiography, Retina 17 (4) (1997) 286–293, https://doi.org/10.1097/00006982-199707000-00002.

[8] Y. Hirami, A. Tsujikawa, M. Sasahara, N. Gotoh, H. Tamura, A. Otani, et al., Alterations of retinal pigment epithelium in central serous chorioretinopathy, Clin. Exp. Ophthalmol. 35 (3) (2007) 225–230, https://doi.org/10.1111/j.1442-9071.2006.01447.x. PMID: 17430508.

[9] SS GM Mudvari, A.D. Fu, H.R. McDonald, R.N. Johnson, E. Ai, J.M. Jumper, The natural history of pigment epithelial detachment associated with central serous chorioretinopathy, Retina 27 (9) (2007) 1168–1173, https://doi.org/10.1097/IAE.0b013e318156db8a.

[10] D. Pauleikhoff, D. Loffert, G. Spital, M. Radermacher, J. Dohrmann, A. Lommatzsch, et al., Pigment epithelial detachment in the elderly. Clinical differentiation, natural course and pathogenetic implications, Graefes. Arch. Clin. Exp. Ophthalmol. 240 (7) (2002) 533–538, https://doi.org/10.1007/s00417-002-0505-8. PMID: 12136282.

[11] F. Arif, A. Pryds, M. Larsen, Isolated pigment epithelium detachment: evidence for relation to central serous chorioretinopathy and effect of photodynamic therapy, Acta Ophthalmol. 96 (8) (2018) 821–827, https://doi.org/10.1111/aos.13838. PMID: 30246489.

[12] A. Daruich, A. Matet, A. Dirani, E. Bousquet, M. Zhao, N. Farman, et al., Central serous chorioretinopathy: recent findings and new physiopathology hypothesis, Prog. Retin. Eye Res. 48 (2015) 82–118, https://doi.org/10.1016/j.preteyeres.2015.05.003. PMID: 26026923.

[13] M. Ritter, M. Bolz, S. Sacu, G.G. Deak, C. Kiss, C. Pruente, et al., Effect of intravitreal ranibizumab in avascular pigment epithelial detachment, Eye (Lond) 24 (6) (2010) 962–968, https://doi.org/10.1038/eye.2009.265. PMID: 19911018.

[14] S. Goto, Ueno C GF, K. Nishida, Reduced-fluence photodynamic therapy for subfoveal serous pigment epithelial detachment with choroidal vascular hyperpermeability, Retina 154 (5) (2012) 865–871, https://doi.org/10.1016/j.ajo.2012.05.001.

[15] S. Inoda, H. Takahashi, Y. Inoue, H. Tampo, S. Sakamoto, Y. Arai, et al., Half-dose photodynamic therapy for serous non-neovascular retinal pigment epithelial detachment, Clin. Ophthalmol. 13 (2019) 959–968, https://doi.org/10.2147/OPTH.S196901. PMID: 31289437.

[16] A. Kamimura, A. Miki, M. Kishi, M. Okuda, M. Hayashida-Hirano, M. Sakamoto, et al., Two-year outcome of half-time photodynamic therapy for chronic central serous chorioretinopathy with and without choroidal neovascularization, PLoS. One 18 (5) (2023) e0284979, https://doi.org/10.1371/journal.pone.0284979. PMID: 37130134.

[17] MJ HY Tsai, Half-time photodynamic therapy for central serous chorioretinopathy, Optom. Vis. Sci. 91 (9) (2014) 1140–1145, https://doi.org/10.1097/OPX.0000000000000360.

[18] C. Matsumoto, E. Arimura, S. Okuyama, S. Takada, S. Hashimoto, Y. Shimomura, Quantification of metamorphopsia in patients with epiretinal membranes, Invest. Ophthalmol. Vis. Sci. 44 (9) (2003) 4012–4016, https://doi.org/10.1167/iovs.03-0117. PMID: 12939323.

[19] M. Hayashida, A. Miki, S. Nakai, W. Matsumiya, H. Imai, S. Kusuhara, et al., Predictive factors of metamorphopsia after reduced-fluence photodynamic therapy in patients with central serous chorioretinopathy with good baseline visual acuity, PLoS. One 15 (10) (2020) e0240557, https://doi.org/10.1371/journal.pone.0240557. PMID: 33044997.

[20] S. RF, Disease expression in nonexudative age-related macular degeneration varies with choroidal thickness, Retina 38 (4) (2018) 708–716, https://doi.org/10.1097/IAE.0000000000001689.

[21] H.Y. Liu, C.H. Yang, C.M. Yang, T.C. Ho, C.P. Lin, YT. Hsieh, Half-dose versus Half-time photodynamic therapy for Central serous chorioretinopathy, Am. J. Ophthalmol. 167 (2016) 57–64, https://doi.org/10.1016/j.ajo.2016.04.001. PMID: 27084002.

[22] W.M. Chan, T.Y. Lai, R.Y. Lai, D.T. Liu, DS. Lam, Half-dose verteporfin photodynamic therapy for acute central serous chorioretinopathy: one-year results of a randomized controlled trial, Ophthalmology. 115 (10) (2008) 1756–1765, https://doi.org/10.1016/j.ophtha.2008.04.014. PMID: 18538401.

[23] Y.T. Kim, S.W. Kang, KH. Bai, Choroidal thickness in both eyes of patients with unilaterally active central serous chorioretinopathy, Eye (Lond) 25 (12) (2011) 1635–1640, https://doi.org/10.1038/eye.2011.258. PMID: 22020172.

[24] G. Chen, R. Tzekov, W. Li, F. Jiang, S. Mao, Y. Tong, Subfoveal choroidal thickness in Central serous chorioretinopathy: A meta-analysis, PLoS. One 12 (1) (2017) e0169152, https://doi.org/10.1371/journal.pone.0169152. PMID: 28076442.

[25] F.H. Lai, D.S. Ng, M. Bakthavatsalam, V.C. Chan, A.L. Young, F.O. Luk, et al., A multicenter study on the long-term outcomes of half-dose photodynamic therapy in chronic Central serous chorioretinopathy, Am. J. Ophthalmol. 170 (2016) 91–99, https://doi.org/10.1016/j.ajo.2016.07.026. PMID: 27519561.

[26] T. Suzuki, C. Otaki, H. Tate, Y. Ueta, Association between subretinal fluid duration in central serous chorioretinopathy and chorioretinal structure in unaffected fellow eyes, Sci. Rep. 15 (1) (2025) 10977, https://doi.org/10.1038/s41598-025-95725-0. PMID: 40164826.

[27] R. Chakraborty, S.A. Read, MJ. Collins, Diurnal variations in axial length, choroidal thickness, intraocular pressure, and ocular biometrics, Invest. Ophthalmol. Vis. Sci. 52 (8) (2011) 5121–5129, https://doi.org/10.1167/iovs.11-7364. PMID: 21571673.

[28] E. Arimura, C. Matsumoto, H. Nomoto, S. Hashimoto, S. Takada, S. Okuyama, et al., Correlations between M-CHARTS and PHP findings and subjective perception of metamorphopsia in patients with macular diseases, Invest. Ophthalmol. Vis. Sci. 52 (1) (2011) 128–135, https://doi.org/10.1167/iovs.09-3535. PMID: 20739469.