Kobe University Repository : Kernel

PDF issue: 2026-11-25

Association between herniation pit and intra-articular pathology in patients with symptomatic femoroacetabular impingement syndrome

Kuroda, Yuichi ; Kamenaga, Tomoyuki ; Tsubosaka, Masanori ; Nakano, Naoki ; Matsumoto, Tomoyuki ; Kuroda, Ryosuke ; Hayashi, Shinya

(Citation)
Journal of Joint Surgery and Research,4(2):123-127

(Issue Date)
2026-06

(Resource Type)
journal article

(Version)
Version of Record

(Rights)
© 2026 The Author(s). Published by Elsevier B.V. on behalf of The Japanese Hip Society, The Japanese Society for Replacement Arthroplasty and The Japanese Knee Society.
This is an open access article under the Creative Commons Attribution 4.0…

(URL)
https://hdl.handle.net/20.500.14094/0100503407

Journal of Joint Surgery and Research 4 (2026) 123–127

Contents lists available at ScienceDirect

Journal of Joint Surgery and Research

journal homepage: www.journals.elsevier.com/journal-of-joint-surgery-and-research

Original Article

Association between herniation pit and intra-articular pathology in patients with symptomatic femoroacetabular impingement syndrome

Yuichi Kuroda *, Tomoyuki Kamenaga, Masanori Tsubosaka, Naoki Nakano, Tomoyuki Matsumoto, Ryosuke Kuroda, Shinya Hayashi

Department of Orthopaedic Surgery, Kobe University Graduate School of Medicine, Kobe, 650-0017, Japan

ARTICLE INFO

Keywords:
Hip arthroscopy
Femoroacetabular impingement syndrome
Herniation pit
Cartilage
Labrum

ABSTRACT

Purpose: This study aimed to evaluate whether there was a difference in intra-articular findings between patients who underwent hip arthroscopy for femoroacetabular impingement syndrome (FAIS), with and without a herniation pit (HP). Furthermore, we examined whether HP affected the clinical outcomes of hip arthroscopy.
Methods: We retrospectively analyzed consecutive patients who underwent hip arthroscopy at our institution between March 2016 and October 2022. All patients were followed up for at least two years. Patients were classified into two groups based on the presence or absence of HP using radiography, computed tomography (CT), or magnetic resonance imaging (MRI). Cartilage lesions of the acetabulum or femoral head, the extent of labral damage observed during surgery, and clinical outcomes were compared between the two groups.
Results: A total of 66 patients were included. Based on the imaging analysis, 30 hips were classified as having HP (HP + group) and 36 hips as having none (HP− group). The HP + group had a significantly higher percentage of high grades of Multicenter Arthroscopy of the Hip Outcomes Research Network (MAHORN) classification for cartilage damage to the acetabulum and Beck classification for labral tear relative to the HP− group (HP+: 30%, HP−: 11%, P = 0.027, HP+: 57%, HP−: 25%, P = 0.028). There were no significant differences in the follow-up period between the two groups in terms of clinical outcomes.
Conclusions: Patients with symptomatic FAIS and HP showed significantly more severe damage to the labrum and cartilage on the acetabular side of the joint than those without HP. However, there were no significant differences in clinical outcomes between the two groups with and without HP.

1. Introduction

A herniation pit (HP) in the hip is a small, benign fibrocystic lesion that occurs on the anterior surface of the femoral head-neck junction [1]. Pitt et al. first reported on HP more than 30 years ago. They described that HPs are associated with acquired degenerative changes that occur on the surface of the femoral neck and are subcortical pits or cavities formed by the herniation of soft tissue contents through surface defects [2]. A systematic review concluded that there is a significant association between the incidence of HPs and Femoroacetabular Impingement (FAI)-related bone morphology [1].

The UK full randomized controlled trial of Arthroscopic Surgery for Hip Impingement (UK FASHIoN) and the Femoroacetabular Impingement Trial (FAIT) study showed that hip arthroscopic surgery significantly improved the activities of daily living and quality of life in patients with FAI syndrome (FAIS), when compared with conservative treatment [3,4].

Several factors have been reported to influence the outcome of hip arthroscopy for FAIS [5]. One such factor that influences arthroscopic outcomes is intra-articular arthropathy [6]. Pitt et al. reported that HPs are associated with joint degenerative change [2]. However, although an association between HP and prevalence has been shown in FAIS [1], few studies have reported an association between HP and intra-articular findings in patients with FAIS.

Therefore, the purpose of this study was to examine whether there was a difference in intra-articular findings between patients who underwent hip arthroscopy for FAIS with and without HP. Furthermore, we examined whether HP affected the clinical outcomes of hip arthroscopy. We hypothesized that in patients with FAIS, concomitant HP would lead to significantly more arthropathy than in patients without HP, negatively affecting clinical outcomes.

* Corresponding author. Department of Orthopaedic Surgery Kobe University Graduate School of Medicine 7-5-1 Kusunoki-cho, Chuo-ku, Kobe, 650-0017, Japan.
E-mail address: 0321yuichi0321@gmail.com (Y. Kuroda).

https://doi.org/10.1016/j.jjoisr.2026.03.004
Received 30 January 2026; Received in revised form 1 March 2026; Accepted 9 March 2026

2949-7051/© 2026 The Author(s). Published by Elsevier B.V. on behalf of The Japanese Hip Society, The Japanese Society for Replacement Arthroplasty and The Japanese Knee Society. This is an open access article under the CC BY license (http://creativecommons.org/licenses/by/4.0/).

2. Materials and methods

2.1. Patients

We retrospectively analyzed consecutive patients who underwent hip arthroscopy at our institution between March 2016 and October 2022. All patients were followed up for at least two years. Because this study evaluated the relationship between HP and FAIS, patients without FAIS were excluded. Our inclusion criteria for the FAIS were based on physical examination and radiographic findings. Patients had to experience hip pain lasting more than 3 months and undergo a positive impingement test. Radiographic evidence of cam deformity was identified by an alpha angle >55° on at least one radiographic view, via either computed tomography (CT) or magnetic resonance imaging (MRI) [7,8]. Radiographic evidence of a pincer deformity was determined by the presence of a crossover sign with a lateral center edge angle >25°, Tönnis angle <0°, coxa profunda, or a positive ischial spine sign [7,8].

Patients were classified into two groups according to the presence or absence of HP (Fig. 1). HP was defined as a well-demarcated, round or oval radiolucent lesion located at the anterosuperior aspect of the femoral head–neck junction, with a sclerotic margin, identified on radiography, CT, or MRI. A lesion was considered HP-positive when at least one imaging modality demonstrated these characteristic findings. To avoid misclassification, lesions larger than 1 cm or without a sclerotic margin were not considered HP [1,2]. The study was approved by the Institutional Ethics Committee of Kobe University Graduate School of Medicine (approval number: B250116, approval date: September 16, 2025) and all participants gave informed consent.

2.2. Surgical techniques

We evaluated intra-articular pathological issues, including chondrolabral damage, using two standard portals (anterolateral and mid-anterior), with the patient positioned supine and under traction. An interportal capsular incision was made from the 12- to 2-o'clock position using a beaver blade to enhance visibility. All the patients underwent labral repair using multiple suture anchors. Femoral head–neck osteochondroplasty was performed if cam morphology was present, and the acetabular rim was trimmed to address pincer morphology. Capsular repair was performed using either a side-to-side stitch or the shoelace technique, after establishing a proximal mid-anterior portal. All patients were followed up at our institution.

2.3. Arthroscopic evaluation

During surgery, we visually examined the joint and recorded any chondral lesions on the acetabulum or femoral head, along with the cor[illegible] the

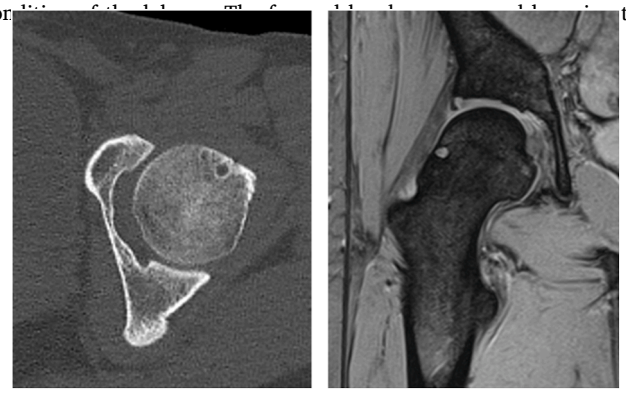

Fig. 1. Herniation Pits on computed tomography and magnetic resonance imaging.

International Cartilage Repair Society (ICRS) classification system [9]. The acetabular rim lesion was evaluated based on Multicenter Arthroscopy of the Hip Outcomes Research Network (MAHORN) classification [10]. Labral tears were evaluated using the Beck classification [11].

2.4. Clinical outcomes

Patient follow ups were conducted for a minimum of 2 years. The study participants completed a comprehensive subjective questionnaire to document outcomes before and after surgery. The questionnaire included the modified Harris Hip Score (mHHS), which assesses pain and function on a scale of 0–100 points. The minimal clinically important difference (MCID) and patient-acceptable symptom state (PASS) were also evaluated. Based on previous studies, the MCID and PASS scores were set to 8 and 74 points, respectively [12,13]. The proportion of patients who converted to total hip arthroplasty during the follow-up period was also assessed. In addition, the proportion of patients who demonstrated radiographic osteoarthritis progression, defined as an increase of at least one Tönnis grade at final follow-up compared with preoperative radiographs, was evaluated.

2.5. Evaluation and statistical analysis

Patient demographic data such as age, sex ratio, body mass index (BMI), follow-up period, and radiographic measurements including alpha angle and lateral center-edge angle (LCEA) were compared between the two groups with and without HP. In terms of the level of cartilage damage on arthroscopic findings, the acetabular rim was divided into low (0–2) and high (3–5) grades based on the MAHORN classification, whereas the femoral head was divided into normal (grade 0) and mild-to-high (grades 1–4) based on the ICRS classification. The degree of labral tear was classified as low (0–1) and high (2–4) grades, according to the Beck classification. The respective subgroup rates were compared between the two groups with and without HP. Clinical outcomes were compared between the two groups: pre- and postoperative mHHS, rate of MCID acquisition in mHHS, and rate of conversion to total hip arthroplasty. Furthermore, binary logistic regression analyses were performed to determine whether HP was independently associated with intra-articular pathology. The dependent variables were high-grade acetabular cartilage damage (MAHORN grade 3–5) and high-grade labral tear (Beck grade 2–4). HP was entered as the primary independent variable and the models were adjusted for age and sex. Odds ratios (ORs) with 95% confidence intervals (CIs) were calculated.

The surgeon who performed the hip arthroscopy (YK) and another orthopaedic surgeon (TK), who was blinded to the clinical outcomes, evaluated the intra-articular findings and the presence of HP. In cases of disagreement, consensus was reached through discussion. To analyze the reproducibility of all measurements including intra-articular findings, radiographic measurements, and the presence of HP, intra- and interobserver reliabilities were examined using an intraclass correlation coefficient (ICC) and Cohen's kappa coefficient test in a subset of 30 cases. To calculate the intraobserver reliability, measurements were taken twice at 4-week intervals by a single surgeon (YK). For interobserver reliability, the measurements were performed by two surgeons (YK and TK). The ICCs and kappa coefficients for intra- and interobserver reliabilities were >0.8 (range, 0.84–1.00) for all measurements (Table 1).

All values are presented as mean ± standard deviation, and the results were analyzed using Bell Curve for Excel (Social Survey Research Information Co., Ltd., Tokyo, Japan). The unpaired *t*-test was used to assess differences in continuous variables, whereas the chi-square test was used for intergroup comparisons of categorical variables. Statistical value (P) of <0.05 was considered to be significant. When comparing the two groups, a power analysis indicated that a minimum of 21 patients per group would be necessary, based on G*Power version 3.121 [14], with an alpha of 0.05, a power (1–β) of 0.80, and an effect size of 0.8, derived from the previous study reporting the significant difference in the prevalence of severe intra-articular lesions [15].

Table 1
Intraclass correlation coefficients and Kappa coefficients for intra- and inter-observer reliabilities of measurements.

Variable	Intra-observer	Inter-observer
High grade of MAHORN classification	0.93	0.85
High grade of Beck classification	0.93	0.86
Mild-to-high grade of ICRS classification	1.00	0.84
Alpha angle	0.92	0.90
LCEA	0.95	0.94
Presence of herniation pit	1.00	1.00

MAHORN, Multicenter Arthroscopy of the Hip Outcomes Research Network; ICRS, International Cartilage Repair Society; LCEA, lateral center-edge angle.

3. Results

A total of 93 consecutive patients who underwent hip arthroscopy at our hospital were included in this study. Excluding patients without FAIS who underwent labral repair alone without osteochondroplasty (n = 25) and those who could not be followed up for >2 years (n = 2), a total of 66 patients were included in the analysis (Fig. 2). Based on the imaging analysis, 30 study participants were classified as having HP (HP + group) and 36 as having none (HP− group). There were no significant differences in the background characteristics of the patients, including age, sex ratio, BMI, LCEA, and alpha angle, between the two groups (Table 2).

With respect to cartilage damage to the acetabulum, the HP + group had a significantly higher percentage of patients with high grades of MAHORN classification relative to those in the group without HP− group (HP+: 30%, HP−: 11%, P = 0.027) (Table 3). However, there was no significant difference between groups in the percentage of patients with mild-to-high grades in the ICRS classification of femoral head cartilage damage (HP+: 10%, HP−: 11%, P = 0.443) (Table 3). For labral tear, the percentage of patients with a high grade of Beck classification was significantly higher in the HP + group relative to the HP− group (HP+: 57%, HP−: 25%, P = 0.028) (Table 3). In multivariable binary logistic regression analyses adjusted for age and sex, HP was independently associated with high-grade pathology in both classification systems. HP was significantly associated with high-grade acetabular cartilage damage (MAHORN grade 3–5; OR 4.81, 95% CI 1.10–21.03, p = 0.037) (Table 4) and high-grade labral tears (Beck grade 2–4; OR 3.25, 95% CI 1.12–9.44, p = 0.030) (Table 5). Male sex was inversely associated with high-grade cartilage damage.

Regarding clinical outcomes, there was no significant difference in follow-up period between the two groups (HP+: 59.7 ± 36.5 months, HP−: 56.3 ± 32.9 months, P = 0.688) (Table 6). With regard to clinical scores, there were no significant differences in the pre- and post-operative mHHS, MCID, and PASS acquisition rates between the two groups (pre mHHS; HP+: 65.1 ± 13.7, HP−: 64.7 ± 16.3, P = 0.917, post mHHS; HP+: 89.1 ± 11.5, HP−: 91.2 ± 11.1, P = 0.443, MCID; HP+: 90.0%, HP−: 94.4%, P = 0.497, PASS; HP+: 86.7%, HP−: 94.4%, P = 0.274) (Table 6). Although there was a trend toward higher converting THA rates in the HP + group when compared to the HP− group, there was no significant difference between groups (HP+: 16.7%, HP−:

Table 2
Comparison of patient background characteristics between the two groups with and without Herniation Pit.

	Herniation Pit (+)	Herniation Pit (−)	*P*-value
Number of patients	30	36	
Age	40.4 ± 12.7	36.2 ± 14.6	0.227
Gender: Male ratio	22/30 (73.3%)	25/36 (69.4%)	0.728
BMI	23.6 ± 2.8	23.6 ± 2.7	0.929
Alpha angle	67.6 ± 6.8	68.7 ± 9.2	0.613
LCEA	32.2 ± 7.0	29.1 ± 7.5	0.096

BMI, body mass index; LCEA, lateral center-edge angle.
The data are expressed as mean ± SD values.

Table 3
Comparison of intra-articular findings between the two groups with and without Herniation Pit.

	Herniation Pit (+) (n = 30)	Herniation Pit (−) (n = 36)	*P*-value
Acetabular cartilage delamination, n (%)			0.027*
MAHORN 0–2	21 (70)	32 (89)	
MAHORN 3–5	9 (30)	4 (11)	
Labral tear, n (%)			0.028*
Beck 0–1	13 (43)	24 (75)	
Beck 2–4	17 (57)	12 (25)	
Cartilage damage of femoral head, n (%)			0.443
ICRS 0	27 (90)	32 (89)	
ICRS 1–4	3 (10)	4 (11)	

MAHORN, Multicenter Arthroscopy of the Hip Outcomes Research Network; ICRS, International Cartilage Repair Society.
*P < 0.05.
The data are expressed as mean ± SD values.

Table 4
Binary logistic regression analysis for high-grade of MAHORN classification.

	Adjusted OR	95% CI	*P*-value
Herniation pit (+)	4.81	1.10–21.03	0.037
Age	1.05	1.00–1.11	0.068
Gender: Male ratio	0.16	0.04–0.69	0.014

MAHORN, Multicenter Arthroscopy of the Hip Outcomes Research Network; OR, Odds Ratio; CI, Confidence Interval.

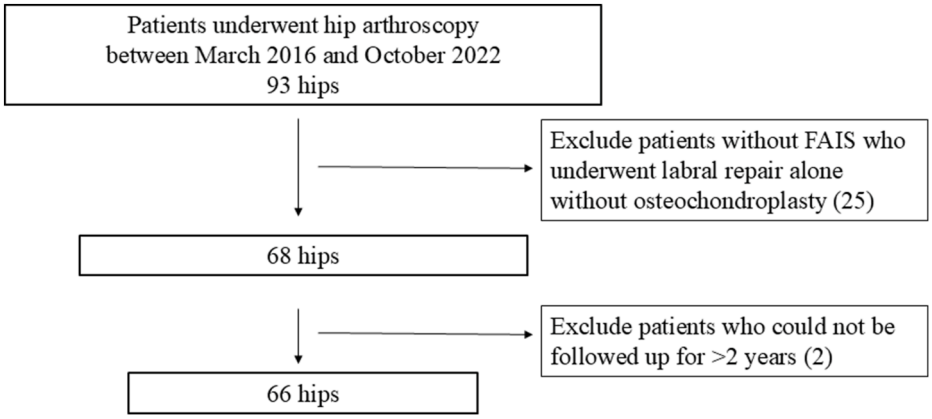

Fig. 2. Flowchart showing the patient selection process.

Table 5
Binary logistic regression analysis for high-grade of Beck classification.

	Adjusted OR	95% CI	*P*-value
Herniation pit (+)	3.25	1.12–9.44	0.030
Age	1.01	0.97–1.05	0.662
Gender: Male ratio	0.53	0.16–1.70	0.284

OR, Odds Ratio; CI, Confidence Interval.

Table 6
Comparison of clinical outcomes between the two groups with and without Herniation Pit.

	Herniation Pit (+) (n = 30)	Herniation Pit (−) (n = 36)	*P*-value
Follow-up period (months)	59.7 ± 36.5	56.3 ± 32.9	0.688
Pre mHHS	65.1 ± 13.7	64.7 ± 16.3	0.917
Post mHHS	89.1 ± 11.5	91.2 ± 11.1	0.443
MCID acquisition rate (%)	90.0	94.4	0.497
PASS acquisition rate (%)	86.7	94.4	0.274
Converting THA rate (%)	16.7	5.6	0.072
Osteoarthritis progression rate (%)	23.3	11.1	0.092

Pre mHHS, preoperative modified Harris Hip Score; Post mHHS, postoperative modified Harris Hip Score; MCID, minimal clinically important difference; PASS, patient-acceptable symptom state; THA, total hip arthroplasty.
*P < 0.05.
The data are expressed as mean ± SD values.

5.6%, P = 0.072). Similarly, the rate of radiographic osteoarthritis progression was higher in the HP + group (HP+: 23.3%, HP−: 11.1%), but the difference was not statistically significant (p = 0.092). (Table 6).

4. Discussion

The most important finding of this study was that the HP + group showed significantly more severe damage to the labrum and cartilage in the joint, especially on the acetabular side, relative to the HP− group. Importantly, binary logistic regression analyses demonstrated that the presence of a HP was independently associated with high-grade intra-articular pathology, even after adjusting for age and sex. Specifically, HP was associated with a 4.81-fold increase in the odds of high-grade acetabular cartilage damage based on the MAHORN classification and a 3.25-fold increase in the odds of high-grade labral tears according to the Beck classification. Pitt et al. reported that HP is associated with degenerative changes in the hip joint, consistent with our findings [2]. There were no significant differences in clinical outcomes. These results suggest that patients with HP may have advanced arthropathy, but can still have good surgical outcomes.

Pitt et al. first provided a detailed analysis of HPs and proposed that they were formed by increased pressure at the superoanterior region of the femoral head-neck junction following repetitive low-degree trauma to the iliofemoral ligament [2]. Later, Ganz et al. stated that the presence of HP was a sign of FAIS [16]. Leunig et al. also demonstrated a strong association between FAIS and HP, suggesting that HP may form in patients with FAIS due to secondary pressure from the ilium or labrum during hip flexion with internal rotation [17]. A previous systematic review showed that the pooled odds ratio for the occurrence of HPs in the presence of an FAI-related morphology was 1.64 [1]. It has been reported to be highly associated with Cam-type FAIS. Interestingly, in a subgroup analysis, asymptomatic hips were more strongly associated with HP prevalence than symptomatic hips. Therefore, while HP is significantly associated with FAIS whether symptomatic or asymptomatic, and arthropathy may be progressive in symptomatic cases.

Mineta et al. reported that the alpha angle was significantly higher in the group with HP relative to the group without HP [18]. However, in the present study, there was no significant difference in the alpha angle between the two groups. The reason for this discrepancy may be that the study by Mineta et al. included all the patients who underwent pelvic CT, whereas the present study included only those who underwent hip arthroscopy. The HP− group in this study consisted of patients who were indicated for hip arthroscopy and had a larger alpha angle than the HP− group in the Muneta et al. study. Although large cam lesions such as pistol grip are known to be a factor in the progression of arthropathy, there was no significant difference in the alpha angle between the two groups in this study, suggesting that HP may affect arthropathy independent of the size of the cam lesion [19].

In a previous study that used a scoping review to analyze the factors leading to poor clinical outcomes after hip arthroscopy, HP was not included as a failure factor [5]. In the present study, there was no significant difference in clinical outcomes between the two groups of patients with and without HP. However, the degeneration of the acetabular cartilage and labrum was significantly more advanced in the HP + group. Osteoarthritis is a poor predictor of clinical outcomes after hip arthroscopy and has become a major scientific rationale [5,20]. The results of this study indicate that HP is useful in diagnosing FAIS, but it may also be an important factor in considering the progression of osteoarthritis in symptomatic patients.

4.1. Limitations

This study had some limitations. First, our sample population consisted solely of Japanese patients. Therefore, further analyses involving populations from regions such as the US and Europe are required to confirm the broader applicability of our findings. Second, the sample size is relatively small. Consequently, this study may be underpowered to detect differences in clinical outcomes, raising the possibility of type II error (false negatives). Third, this was a retrospective study, whereas a randomized controlled trial would have provided more useful information. However, given the research methodology, such trials may be difficult to conduct. Forth, the data were limited to a follow-up period of approximately five years. Further studies with longer follow-up periods are likely to provide a clearer understanding of whether HPs influence intra-articular pathologies and clinical outcomes.

5. Conclusions

Patients with symptomatic FAIS and HP showed significantly more severe damage to the labrum and cartilage on the acetabular side of the joint than those without HP. However, there were no significant differences in clinical outcomes between the two groups with and without HP.

Author contributions

All authors have made substantial contributions to (1) the conception and design of the study, or acquisition of data, or analysis and interpretation of data; (2) drafting the article or revising it critically for important intellectual content; and (3) final approval of the version to be submitted. The specific contributions of the authors are as follows:

(1) Conception and design of the study: YK. Analysis and interpretation of the data: all authors.
(2) Drafting of the article: YK.
(3) Final approval of the version to be submitted: YK and SH.

Funding

No funding was received by any of the authors in support of or in any relationship to the study.

Declaration of competing interest

The authors have no competing interests to declare.

Acknowledgements

We would like to thank Editage (www.editage.jp) for English Language editing.

References

[1] Kim C-H, Han S, Yang C-J, Kim JH. Correlation between the presence of herniation pit and femoroacetabular impingement: a systematic review and meta-analysis. Knee Surg Sports Traumatol Arthrosc 2020;28:3365–73.
[2] Pitt MJ, Graham AR, Shipman JH, Birkby W. Herniation pit of the femoral neck. AJR Am J Roentgenol 1982;138(6):1115–21.
[3] Griffin DR, Dickenson EJ, Wall PDH, et al. Hip arthroscopy versus best conservative care for the treatment of femoroacetabular impingement syndrome (UK FASHIoN): a multicentre randomised controlled trial. Lancet 2018;391:2225–35.
[4] Palmer AJR, Ayyar Gupta V, Fernquest S, et al. Arthroscopic hip surgery compared with physiotherapy and activity modi fi cation for the treatment of symptomatic femoroacetabular impingement: Multicentre randomised controlled trial. BMJ 2019;364:l185.
[5] Kuroda Y, Saito M, Çınar EN, Norrish A, Khanduja V. Patient-related risk factors associated with less favourable outcomes following hip arthroscopy. Bone Joint J 2020;102-B(7):822–31.
[6] Lu V, Andronic O, Zhang JZ, Khanduja V. Outcomes of arthroscopy of the hip for femoroacetabular impingement based on intraoperative assessment using the outerbridge classification. Bone Joint J 2023;105-B(7):751–9.
[7] Griffin DR, Dickenson EJ, O'Donnell J, Agricola R, Awan T, Beck M, Clohisy JC, Dijkstra HP, Falvey E, Gimpel M, Hinman RS, Hölmich P, Kassarjian A, Martin HD, Martin R, Mather RC, Philippon MJ, Reiman MP, Takla A, Thorborg K, Walker S, Weir A, Bennell KL. The warwick agreement on femoroacetabular impingement syndrome (FAI syndrome): an international consensus statement. Br J Sports Med 2016;50(19):1169–76.
[8] Nepple JJ, Riggs CN, Ross JR, Clohisy JC. Clinical presentation and disease characteristics of femoroacetabular impingement are sex-dependent. J Bone Joint Surg Am 2014;96(20):1683–9.
[9] Beck EC, Trasolini NA. Editorial commentary: osteochodral autograft and allograft show favorable outcomes for high-grade hip femoral cartilage lesions, but caution is required for impaction injuries and osteonecrosis. 2024 Apr 25. https://doi.org/10.1016/j.arthro.2024.03.048. S0749063(24)00295-0.
[10] El-Radi MA, Marin-Peña OR, Said HG, Tey-Pons M. Basics in hip chondrolabral lesions and state of the art. SICOT J 2017;3:73.
[11] Mayer SW, Fauser TR, Marx RG, Ranawat AS, Kelly BT, Lyman S, Nawabi DH. Reliability of the classification of cartilage and labral injuries during hip arthroscopy. J Hip Preserv Surg 2021;7(3):448–57.
[12] Kemp JL, Collins NJ, Roos EM, Crossley KM. Psychometric properties of patient-reported outcome measures for hip arthroscopic surgery. Am J Sports Med 2013;41:2065–73.
[13] Chahal J, Van Thiel GS, Mather 3rd RC, Lee S, Song SH, Davis AM, Salata M, Nho SJ. The patient acceptable symptomatic state for the modified harris hip score and hip outcome score among patients undergoing surgical treatment for femoroacetabular impingement. Am J Sports Med 2015;43(8):1844–9.
[14] Faul F, Erdfelder E, Buchner A, Lang A-G. Statistical power analyses using G* Power 3.1: tests for correlation and regression analyses. Behav Res Methods 2009;41(4):1149–60.
[15] Hevesi M, Hartigan DE, Wu IT, Wyles CC, Desai VS, van Wijnen AJ, Saris DBF, Levy BA, Krych AJ. The rapidly assessed predictor of intraoperative damage (RAPID) score: an In-Clinic predictive model for high-grade acetabular chondrolabral disruption. Orthop J Sports Med 2018;6(10):2325967118799068.
[16] Ganz R, Parvizi J, Beck M, Leunig M, Notzli H, Siebenrock KA. Femoroacetabular impingement: a cause for osteoarthritis of the hip. Clin Orthop Relat Res 2003;417:112–20.
[17] Leunig M, Beck M, Kalhor M, Kim Y-J, Werlen S, Ganz R. Fibrocystic changes at anterosuperior femoral neck: prevalence in hips with femoroacetabular impingement. Radiology 2005;236:237–46.
[18] Mineta K, Goto T, Wada K, Tamaki Y, Hamada D, Higashino K, Sairyo K. Comparison of femoroacetabular impingement-related radiographic features in a convenience sample of Japanese patients with and without herniation pits. Skelet Radiol 2016;45(8):1079–88.
[19] Haefeli PC, Albers CE, Steppacher SD, Tannast M, Büchler L. What are the risk factors for revision surgery after hip arthroscopy for femoroacetabular impingement at 7-year followup? Clin Orthop Relat Res 2017;475(4):1169–77.
[20] Uzun E, Ferrer J, Lizano X, Cabello J, Gürsu S, Pons MT. High satisfaction and low conversion rate to total hip arthroplasty after hip arthroscopy for femoroacetabular impingement syndrome and risk factors affecting survival at long-term follow-up. Knee Surg Sports Traumatol Arthrosc 2025. https://doi.org/10.1002/ksa.12563.