



# Stress Fracture of the Fifth Metatarsal Bone as a Late Complication of Total Knee Arthroplasty

Fujioka, Hiroyuki ; Kokubu, Takeshi ; Makino, Takeshi ; Hirata, Hirokaki ; Nagura, Issei ; Inui, Atsuyuki ; Tanaka, Juichi, Yoshiya,...

**(Citation)**

The Kobe journal of the medical sciences, 55(4):93-97

**(Issue Date)**

2009

**(Resource Type)**

departmental bulletin paper

**(Version)**

Version of Record

**(JaLCOI)**

<https://doi.org/10.24546/81001914>

**(URL)**

<https://hdl.handle.net/20.500.14094/81001914>



## Stress Fracture of the Fifth Metatarsal Bone as a Late Complication of Total Knee Arthroplasty

HIROYUKI FUJIOKA<sup>1</sup>, TAKESHI KOKUBU<sup>2</sup>, TAKESHI MAKINO<sup>2</sup>,  
HIROAKI HIRATA<sup>2</sup>, ISSEI NAGURA<sup>2</sup>, ATSUYUKI INUI<sup>2</sup>,  
JUICHI TANAKA<sup>1</sup>, SHINICHI YOSHIYA<sup>1</sup>,  
and MASAHIRO KUROSAKA<sup>2</sup>

<sup>1</sup>*Department of Orthopaedic Surgery, Hyogo College of Medicine  
1-1 Mukogawa-cho, Nishinomiya 663-8501, Japan.*

<sup>2</sup>*Department of Orthopedic Surgery, Kobe University Graduate School of Medicine  
7-5-1 Kusunoki-cho, Chuo-ku, Kobe, 650-0017, Japan.*

Received 27 August 2009/ Accepted 18 November 2009

**Key Words:** stress fracture, fifth metatarsal bone, Jones' fracture, TKA, complication

### ABSTRACT

A 64-year-old man had undergone a right total knee arthroplasty (TKA) as treatment for osteoarthritis of the knee. Six months after the TKA, the patient sustained a stress fracture of the left fifth metatarsal bone, which was a contralateral side of the TKA, without any apparent trauma or cause. The fracture was treated with internal fixation using a screw and low-intensity pulsed ultrasound treatment was added. During two-year followup after internal fixation of the fifth metatarsal fracture, he had no complaints in the knee or foot.

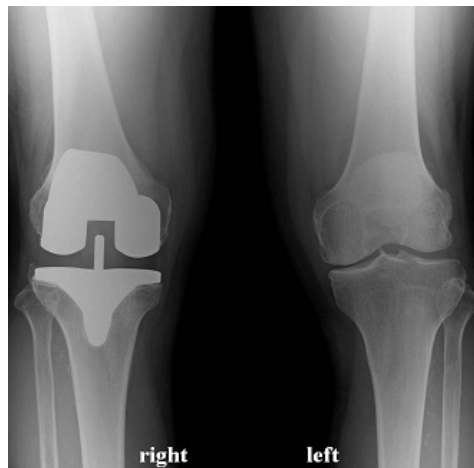
The patient felt anxiety of breakage or loosening of the implant of TKA and the patient had been walking bearing mainly on his left leg and foot which was a contralateral side of the TKA. The cause of the stress fracture of the fifth metatarsal bone was speculated to be excessive stress of weight bearing to the left foot during walking. The physicians should be aware of the risk of stress fracture of the fifth metatarsal bone as one of a rare late complication associated with TKA. It is very important to educate the patients, explaining the risk of breakage or loosening of the implant of TKA and instructing the adequate physical and mental benefits of walking.

### INTRODUCTION

Stress fracture at the base of the fifth metatarsal bone is known as Jones' fracture and most frequently occurs in young adult athletes, such as basketball, football, baseball, and soccer players<sup>10,11</sup>. We present a case of stress fracture of the fifth metatarsal bone in an elderly patient who had undergone total knee arthroplasty (TKA). The fracture was treated with internal fixation and with low-intensity pulsed ultrasound (LIPUS). The patient and his family were informed that the data from his case would be submitted for publication and we received their consent.

### CLINICAL CASE

A 64-year-old man (height 164.5 cm, weight 80 kg, body mass index 29.6) received a right TKA (Sigma RP-F Knee system, DePuy Orthopaedic Inc., U.S.A) as treatment for osteoarthritis of the knee (Figure 1). The post-operative period was uneventful with no incidences of infection or delayed wound healing. Two months after TKA, extension of the right knee was 0 degree and flexion was 110 degree and the patient was able to walk without a stick and returned to his job as manager of his own company. Although he did not play competitive sports, he walked vigorously in the course of his job, taking more than ten thousand steps per day. He did not feel any pain of bilateral knee during walking, however, he had been afraid of possible breakage or loosening of the TKA implant. Therefore, he had been walking bearing mainly on his left leg and foot, which were the contralateral side of the TKA. Six month after TKA, he began to feel left foot pain on walking without any obvious trauma or cause.



**Figure 1.** Radiographs of the knee. TKA was performed on the right knee.

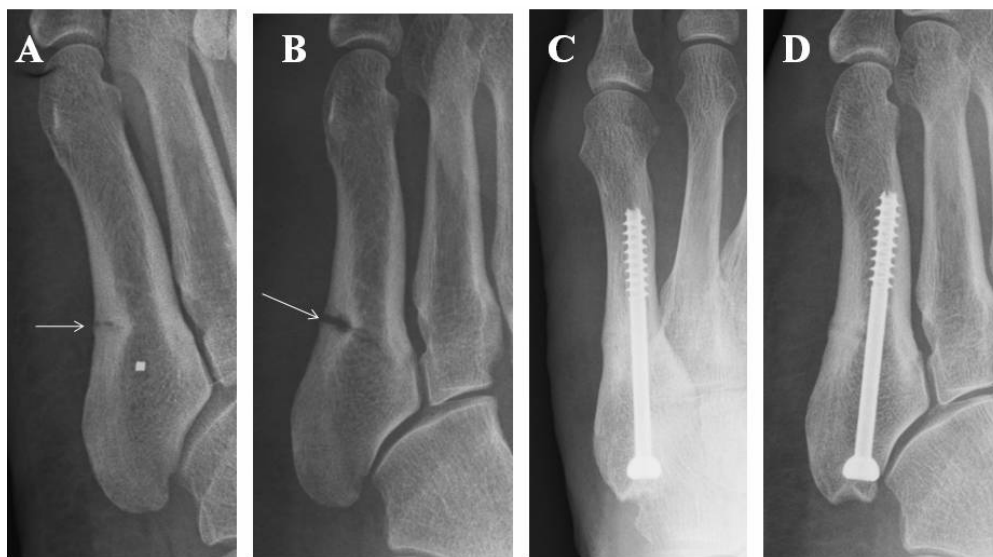On physical examination, although he experienced neither pain on rest nor swelling in his left foot, tenderness was detected at the base of the fifth metatarsal bone. Active range of motion of the ankles and toes was not limited. Although the anteroposterior view of the radiograph of the left foot could not detect fracture, the oblique view demonstrated a fracture line without callus formation at the base of the fifth metatarsal bone (Figure 2A). We diagnosed the patient with ununited stress fracture of the fifth metatarsal bone and instructed the patient to use a foot orthosis and to reduce walking for two months. However, his foot pain was not relieved and the displacement of the fracture of the fifth metatarsal bone increased (Figure 2 B). Therefore, we selected surgical treatment with internal fixation under general anesthesia.

The patient was placed in a nearly complete lateral position. Using fluoroscopy and air tourniquet, a 2 cm-skin incision was made at the proximal portion of the fifth metatarsal bone and a 4.5-mm cannulated screw (Synthes, Tokyo, Japan) was inserted intramedullary from the proximal site of the fifth metatarsal bone using a guide pin. The fracture site was not opened.

Postoperatively, the patient was allowed partial-weight bearing with crutches for three weeks and, thereafter, started to walk with full-weight bearing wearing a foot orthosis for

## FIFTH METATARSAL STRESS FRACTURE AFTER TKA

three months. In addition, treatment with LIPUS to the fracture site of the fifth metatarsal bone using SAFHS (Sonic Accelerated Fracture Healing System, Teijin Pharma Ltd., Tokyo, Japan) was administered for 20 minutes a day for 6 months after surgery. At postoperative one year, the patient could walk without pain in the knee and foot and bone union at the fracture site of the fifth metatarsal bone was confirmed by radiographs (Figure 2 C, D). During the postoperative two-year follow up, he had no complaints in the knee or foot.



**Figure 2.** Radiographs of left foot before surgery (A and B) and after surgery (C and D).

Fracture line (arrow) at the base of the fifth metatarsal bone was detected on the oblique view at the first visit (A). Two months later, the fifth metatarsal fracture was clearly detected and the displacement of the fracture site (arrow) was increased on the oblique view (B). One year after surgery, fracture union at the base of the fifth metatarsal bone was confirmed on anteroposterior (C) and oblique (D) view.

## DISCUSSION

Fractures at the base of the fifth metatarsal have been divided into three types depending on the site: tuberosity avulsion fracture, Jones' fracture, and diaphyseal fracture. Jones' fracture is defined as a stress fracture at the base of the fifth metatarsal, caused by chronic repetitive trauma, frequently occurring in young adult athletes<sup>10,11</sup>. The fifth metatarsal articulates to the cuboid bone and the fourth metatarsal bone. The lateral forefoot is supported with the peroneus brevis tendon, the peroneus tertius tendon, and the lateral band of the plantar fasciia. The interosseous blood supply to the fifth metatarsal tuberosity is derived from many metaphyseal vessels that penetrate the nonarticular surface of the tuberosity<sup>10</sup>. In contrast, the blood supply to the proximal diaphysis is derived from the longitudinal intramedullary branches of the nutrient artery. The blood supply to the distal tuberosity and to the proximal diaphysis is not abundant, which accounts for poor fracture healing of this site. Many techniques for the treatment of stress fracture at the base of the fifth metatarsal have been reported; non-weight bearing with short leg casting, orthotic management, open reduction and internal fixation, and bone grafting<sup>10,11</sup>. Generally, surgical treatment is chosen for athletic patients and conservative treatment for non-athletic or less

demanding patients. In the present case, the patient, who was over sixty years old and had undergone TKA, did not play any sports. Although we treated the patient conservatively with a foot orthosis, the displacement of the fracture of the fifth metatarsal bone increased. Therefore, we selected surgical treatment with internal fixation under general anesthesia.

LIPUS treatment was added because we anticipated a longer healing period might be required for bone union compared with younger patients. A basic investigation of LIPUS in fracture healing shows that LIPUS initiated bone healing in a rat fracture nonunion model<sup>12</sup>. In prospective, randomized, and double-blind clinical studies, LIPUS accelerated the healing of fractures of the distal radius and the tibia<sup>7,8</sup>. Fujioka *et al.* demonstrated successful treatment with LIPUS for nonunion of the hook of the hamate<sup>4</sup>. These prior basic clinical researches suggest that LIPUS accelerates the repair process of nonunion as well as that of acute fractures.

As a late complication after TKA, stress fracture is a rare disorder compared with periprosthetic fractures<sup>1,5,9</sup>. Stress fracture of the femoral neck after TKA is speculated to be caused by the increase in activity after TKA<sup>5,9</sup>. In the present report, stress fracture occurred at the fifth metatarsal bone which was a contralateral side of the TKA. The body mass index of the patient was 29.6 which was ranged in overweight not in obese. He walked vigorously in the course of his job, taking more than ten thousand steps per day. Moreover, he had been afraid of breakage or loosening of the implant of TKA and he had been walking bearing mainly on his left leg and foot which was the contralateral side of the TKA. Six month after TKA, he began to feel left foot pain on walking without any obvious trauma or cause. Therefore, in the present report, the main cause of the stress fracture of the fifth metatarsal bone was considered to be excessive stress of weight bearing to the left foot during walking.

Generally, orthopaedic surgeons recommend patients who have undergone a total knee arthroplasty decrease their participation in athletic and high impact sporting activities, in order to prevent the risk of implant wear, loosening, and periprosthetic fracture<sup>6</sup>. However, low impact activities, such as walking, cycling, golf, and swimming, are usually allowed and often encouraged or incorporated into the physiotherapy program due to their physical and mental health benefits<sup>2,3,6</sup>.

In the present case, the patient was cautioned not to play high impact sports but allowed to exercise by walking after TKA. We could not detect any change in gait pattern after TKA in the clinic, however, the patient admitted that he had been walking bearing weight mainly on his left leg and foot, which was the contralateral side of the TKA, because he was afraid of possible breakage of the TKA implant. Therefore, we considered the stress fracture of the fifth metatarsal was caused by excessive weight bearing during walking. The physicians should be aware of the risk of stress fracture of the fifth metatarsal bone as one of a rare late complication associated with TKA. It is very important to educate the patients, explaining the risk of breakage or loosening of the implant of TKA and instructing the adequate physical and mental benefits of walking as well as reducing high impact activities

## REFERENCES

1. **Bezwada, H.P., Neubauer, P., Baker, J., Israelite, C.L., and Johanson, N.A.** 2004. Periprosthetic supracondylar femur fractures following total knee arthroplasty. *J Arthroplasty* **19**: 453-458.
2. **Chatterji, U., Ashworth, M.J., Lewis, P.L., and Dobson, P.J.** 2005. Effect of total knee arthroplasty on recreational and sporting activity. *ANZ J Surg* **75**: 405-408.
3. **Dahm, D.L., Barnes, S.A., Harrington, J.R., and Berry, D.J.** 2007. Patient reported activity after total knee arthroplasty. *J Arthroplasty* **22 Suppl**: 106-110.

## FIFTH METATARSAL STRESS FRACTURE AFTER TKA

4. **Fujioka, H., Tsunoda, M., Noda, M., Matsui, N., and Mizuno, K.** 2000. Treatment of ununited fracture of the hook of the hamate by low-intensity pulsed ultrasound. -A case report-. *J Hand Surg* **25A**: 77-79.
5. **Hardy, D.C.R., Delince, P.E., Yasik, E., and Lafontaine, M.A.** 1992. Stress fracture of the hip. An usual complication of total knee arthroplasty. *Clin Orthop Rel Res* **281**: 140-144.
6. **Healy, W.L., Sharma, S., Schwartz, B., and Iorio, R.** 2008. Athletic activity after total joint arthroplasty. *J Bone Joint Surg* **90A**: 2245-2252.
7. **Heckman, J.D., Ryaby, J.P., McCabe, J., Frey, J.J., and Kilcoyne, R.F.** 1994. Acceleration of tibial fracture-healing by non-invasive, low-intensity pulsed ultrasound. *J Bone Joint Surg* **76A**: 26-34.
8. **Kristiansen, T.K., Ryaby, J.P., McCabe, J., Frey, J.J., and Roe, L.R.** 1997. Accelerated healing of distal radial fractures with the use of specific, low-intensity ultrasound: a multicenter, prospective, randomized, double-blind, placebo-controlled study. *J Bone Joint Surg* **79A**: 961-973.
9. **Lesniewski, P.J., and Noel Testa, N.** 1982. Stress fracture of the hip as a late complication of total knee replacement. Case Report. *J Bone Joint Surg* **64A**: 304-306.
10. **Nunley JA.** 2001. Fracture of the base of the fifth metatarsal. *Orthop Clin North Am* **32**: 171-180.
11. **Porter, D.A., Duncan, M., and Meyer, S.J.** 2005. Fifth metatarsal Jones fracture fixation with a 4.5-mm cannulated stainless steel screw in the competitive and recreational athlete. A clinical and radiographic evaluation. *Am J Sports Med* **33**: 726-733.
12. **Takikawa, S., Matsui, N., Kokubu, T., Tsunoda, M., Fujioka, H., Mizuno, K., and Azuma Y.** 2001. Low-intensity pulsed ultrasound initiates bone healing in rat nonunion fracture model. *J Ultrasound Med* **20**: 197-205.