



A Case of Congenital Complete Atrioventricular Block Treated with Transdermal Tulobuterol

Ikuta, Toshihiko ; Fujioka, Kazumichi ; Sato, Yumi ; Ashina, Mariko ; Fukushima, Sachiyo ; Ohyama, Shohei ; Okubo, Saki ; Yamana, Keiji ;...

(Citation)

The Kobe journal of the medical sciences, 63(4):109-112

(Issue Date)

2017

(Resource Type)

departmental bulletin paper

(Version)

Version of Record

(JaLCD0I)

<https://doi.org/10.24546/81010261>

(URL)

<https://hdl.handle.net/20.500.14094/81010261>



A Case of Congenital Complete Atrioventricular Block Treated with Transdermal Tulobuterol

TOSHIHIKO IKUTA¹, KAZUMICHI FUJIOKA^{1,*}, YUMI SATO²,
MARIKO ASHINA¹, SACHIYO FUKUSHIMA¹, SHOHEI OHYAMA¹,
SAKI OKUBO¹, KEIJI YAMANA¹, MAYUMI MORIZANE³,
KENJI TANIMURA³, MASASHI DEGUCHI³, KAZUMOTO IJIMA¹,
ICHIRO MORIOKA¹ and HIDETO YAMADA³

¹Department of Pediatrics, Kobe University Graduate School of Medicine, Kobe, Japan;

²Department of Pediatrics, Kakogawa Central City Hospital, Kakogawa, Japan;

³Department of Obstetrics and Gynecology, Kobe University Graduate School of Medicine, Kobe, Japan

*Corresponding author

Received 8 November 2017/ Accepted 27 November 2017

Key words: congenital complete atrioventricular block, SS-A/Ro antibodies, tulobuterol, newborn

Congenital complete atrioventricular block (CCAVB) is a condition in which the atria and ventricles beat independently of each other. CCAVB cases require permanent pacemaker implantation until adulthood. Nevertheless, consensus regarding postnatal medical therapy for bradycardia has not been reached. Here we report the case of a newborn with CCAVB, whose intractable bradycardia was successfully treated with transdermal tulobuterol. Tulobuterol is a selective β_2 -adrenoceptor agonist, widely used safely as bronchodilator in children. It also has positive inotropic and chronotropic effect via β_1 -adrenoceptors. We believe the tulobuterol patch can be used as an optional therapy for CCAVB where pacemaker implantation is not available.

INTRODUCTION

Congenital complete atrioventricular block (CCAVB) is a condition in which the atria and ventricles beat independently of each other. CCAVB is identified *in utero*, at birth, or within the first month of life (1). The prevalence is 1 per 11000 to 22000 births. In cases not complicated by cardiac malformations, the primary cause is immune-mediated injury of the conduction system via transplacental passage of maternal anti-SSA/Ro-SSB/La antibodies (2). CCAVB is generally detected between 16 and 24 weeks of gestation (3), and can be associated with myocarditis (4). These conditions were presumed to be due to transplacental passages of maternal antibodies (5). Thus, as a fetal therapy, we have been conducting a prospective trial to treat CCAVB by weekly intramuscular administration of corticosteroid to mothers, based on our previous successful experiences fetal treatment of CCAVB (5). On the other hands, as a postnatal therapy, it is widely accepted that CCAVB cases require permanent pacemaker implantation until adulthood. Nevertheless, consensus regarding postnatal medical therapy for bradycardia has not been reached (2). Here we report the case of a newborn with CCAVB delivered from a mother with SS-A/Ro antibodies. The newborn was successfully treated with transdermal tulobuterol.

CLINICAL CASE

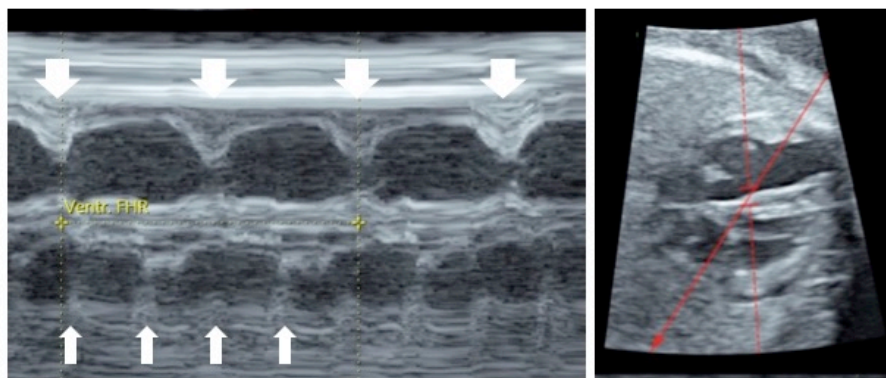
A 33-year-old primigravida woman with an uncomplicated pregnancy underwent routine ultrasound examination at 15 weeks of gestation and was found to be carrying a fetus with bradycardia. The fetus was diagnosed with CCAVB, with independent atrial and ventricular beating (Fig. 1a). Maternal serology revealed elevated anti-SS-A/Ro antibodies (6130.0 U/ml) and SS-B antibodies (50.7 U/ml), respectively. According to fetal therapy protocol, intramuscular betamethasone (12 mg/day) was administered at 21, 22, 23, and 24 weeks of gestation. No symptoms of fetal myocarditis or cardiac failure were detected throughout pregnancy. At 37 weeks and 5 days of gestation, a female infant was delivered via cesarean section. Birthweight was 2584 g. Apgar scores were 8 at one minute and 8 at five minutes.

She showed signs of labored breathing soon after birth and continuous positive airway pressure was initiated. On admission, her heart rate (HR) was approximately 60 beats per minutes (bpm), but her systemic circulatory status was maintained at normal blood pressure (63/38 mmHg). Hepatosplenomegaly was not detected. Initial electrocardiogram (ECG) revealed CCAVB with independent atrial and ventricular beating (Fig. 1b). Chest

X-ray showed reduced lung penetration without cardiomegaly (cardiothoracic ratio; 53%). Blood gas measurement revealed mild respiratory acidosis. Serology revealed increased vertically transmitted maternal antibodies (SS-A/Ro; 6130.0 U/ml, and SS-B; 6.3 U/ml). Echocardiography revealed adequate wall movement without structural defects. Her respiratory distress was diagnosed as transient tachypnea of the newborn, and respiratory support was removed on day of life 2.

To support low cardiac output due to bradycardia, intravenous dobutamine hydrochloride (DOB, 7 $\mu\text{g/kg/min}$) was started after admission. HR increased to 70 bpm. Subsequently, her circulatory status remained stable with continuous urination ($> 2.0 \text{ ml/kg/hr}$); however, her HR gradually decreased to 55 bpm until 48 hours after birth (Fig. 2). Because there was no oral β -adrenergic agonist available in our center, at 57 hour of life we applied half of a 0.5mg tulobuterol patch to her chest after obtaining informed consent of her parents. We anticipated a β_1 -adrenergic effect. A pediatric cardiologist supervised the procedure. Soon after application, her HR has increased to 70 bpm, and did not decline even after discontinuation of DOB. Subsequently, her circulatory status remained stable and she gained weight. On day of life 8, the newborn was transferred to a tertiary care center for further cardiovascular intervention with a tulobuterol patch.

a.



b.

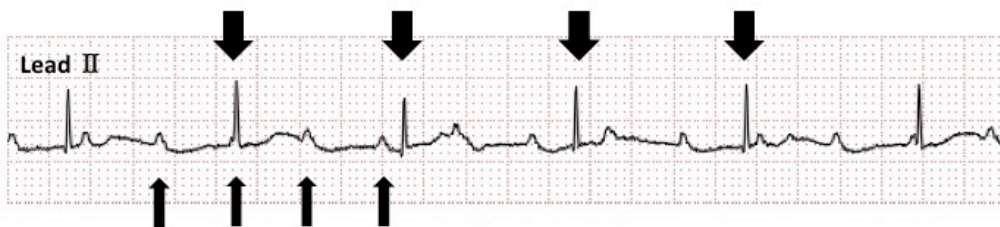


Figure 1. Fetal M-mode echocardiography (**a**) and neonatal electrocardiogram (**b**), revealing complete atrioventricular block. Wide arrows indicate left ventricular contractions and narrow arrows indicate right ventricular contractions.

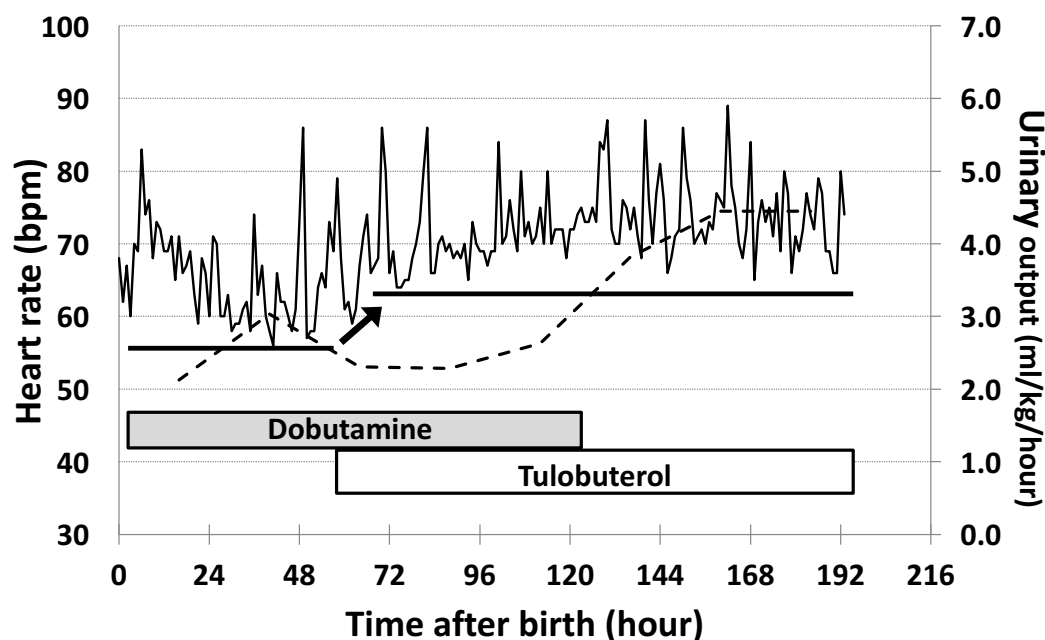


Figure 2. Circulatory status before and after tulobuterol treatment. Heart rate (solid line) and urinary output (dotted line) had gradually increased after transdermal application of tulobuterol patch. The base line levels of heart rate (thick lines) increased almost 10 bpm indicated as narrow arrows.

DISCUSSION

Infants with CCAVB and HR less than 55 bpm have increased mortality (1). These newborns require pacemaker implantation even in asymptomatic cases (6). For the treatment of severe bradycardia, intravenous isoproterenol, atropine, epinephrine, and dopamine are all recommended, but no medication is proven to improve chronic sinus- and AV nodal function beyond the acute management (7). In our case, intravenous DOB therapy could not maintain HR greater than 55 bpm. Thus, to prevent low cardiac output syndrome, we applied a tulobuterol patch as a bridging therapy for pacemaker implantation, with successful HR increase.

For prenatally diagnosed CCAVB like this case, it is desirable to be delivered as scheduled delivery in a specialized pediatric hospital with pediatric cardiology team that can perform emergent pacemaker implantation. However, most children's hospitals in Japan do not provide sufficient maternal care for complicated pregnancy, such as diabetic, nephrotic, or lupus mothers. Thus, we sometimes had to undertake neonatal care of CCAVB cases from mothers with autoimmune diseases whose anti-SSA/Ro-SSB/La antibodies were positive immediately after birth under supervision of specialized pediatric cardiologist, despite unavailability of pacemaker implantation in our institute.

The branded tulobuterol patch (HokunalinTM Tape) is the first transdermal delivery system developed for a selective β_2 -adrenoceptor agonist (8), which is widely used safely as bronchodilator in children. On the other hands, it also has positive inotropic and chronotropic effect via β_1 -adrenoceptors, although the selective affinity of tulobuterol for β_1 -adrenoceptor over the β_2 is approximately 4-fold weaker than isoprenaline or dobutamine (9). In adults, an increase in HR of 10-20 bpm was reported after five repeated transdermal applications of tulobuterol patch (10). The blood drug concentration reaches maximum concentration 9-12h after the transdermal application of the tulobuterol patch, and the effective concentration was maintained for more than 24 h (8).

Regarding the reason why dobutamine administration did not have and tulobuterol had positive effect on bradycardia, we speculated the possible synergistic inotropic effects through β_2 -adrenoceptor stimulation. Intriguingly, Bristow and Ginsburg have reported the presence of substantial β_2 subpopulation in myocardial cells in human ventricular myocardium from their radioligand binding studies (11). In addition, it is reported that selective β_2 [ICI 118,551] antagonists could actively decrease the contraction of human heart (12). Thus, vice versa, β_2 -adrenergic effects of tulobuterol patch might contribute to myocardial contraction in this case, in addition to β_1 -adrenergic effects.

After obtaining informed consent from her parents, we applied 0.25 mg of a tulobuterol patch daily based on the manufacture's instruction (0.5 mg/day for 6 months to 3 years of ages), with subsequent increase in HR and no obvious complications. The reason we chose the tulobuterol patch to this patient is that [1] intravenous

dobutamine infusion was continued, [2] enteral feeding was not established, and [3] no alternative drugs such as isoprenaline was available in our hospital. And the advantage of tulobuterol patch is easy to use and requires only-daily application, and no excessive increase in the blood drug concentration (8). Due to emergent use to rescue the patients, on time IRB approval was unavailable.

In conclusion, we believe the tulobuterol patch can be used as an optional therapy for CCAVB where pacemaker implantation is not available. To elucidate the efficacy and safety of this treatment, well-designed prospective randomized controlled trials are necessary.

ACKNOWLEDGEMENTS

This work was partially supported by grants for Scientific Research from the JSPS KAKENHI (Research Activity start-up grant number: 16H06971, KF and Scientific Research (B) grant number: 17H04341, IM). The authors gratefully acknowledge the staff of our institutions for the patient's care.

REFERENCES

1. **Michaelsson, M., and Engle, M.A.** 1972. Congenital complete heart block: an international study of the natural history. *Cardiovasc Clin* **4**: 85-101.
2. **Baruteau, A.E., Pass, R.H., Thambo, J.B., Behaghel, A., Le Pennec, S., Perdreau, E., et al.** 2016. Congenital and childhood atrioventricular blocks: pathophysiology and contemporary management. *Eur J Pediatr* **175**: 1235-1248.
3. **Buyon, J.P., Waltuck, J., Kleinman, C., and Copel, J.** 1995. In utero identification and therapy of congenital heart block. *Lupus* **4**: 116-121.
4. **Buyon, J.P., Swersky, S.H., Fox, H.E., Bierman, F.Z., and Winchester, R.J.** 1987. Intrauterine therapy for presumptive fetal myocarditis with acquired heart block due to systemic lupus erythematosus. Experience in a mother with a predominance of SS-B (La) antibodies. *Arthritis Rheum* **30**: 44-49.
5. **Yamada, H., Kato, E.H., Ebina, Y., Moriwaki, M., Yamamoto, R., Furuta, I., et al.** 1999. Fetal treatment of congenital heart block ascribed to anti-SSA antibody: case reports with observation of cardiohemodynamics and review of the literature. *Am J Reprod Immunol* **42**: 226-232.
6. **Tracy, C.M., Epstein, A.E., Darbar, D., DiMarco, J.P., Dunbar, S.B., Estes, N.A., 3rd, et al.** 2012. 2012 ACCF/AHA/HRS focused update of the 2008 guidelines for device-based therapy of cardiac rhythm abnormalities: a report of the American College of Cardiology Foundation/American Heart Association Task Force on Practice Guidelines and the Heart Rhythm Society. [corrected]. *Circulation* **126**: 1784-1800.
7. **Kleinman, M.E., de Caen, A.R., Chameides, L., Atkins, D.L., Berg, R.A., Berg, M.D., et al.** 2010. Pediatric basic and advanced life support: 2010 International Consensus on Cardiopulmonary Resuscitation and Emergency Cardiovascular Care Science with Treatment Recommendations. *Pediatrics* **126**: e1261-1318.
8. **Tamura, G., Ichinose, M., Fukuchi, Y., and Miyamoto, T.** 2012. Transdermal tulobuterol patch, a long-acting beta(2)-agonist. *Allergol Int* **61**: 219-229.
9. **Baker, J.G.** 2010. The selectivity of beta-adrenoceptor agonists at human beta1-, beta2- and beta3-adrenoceptors. *Br J Pharmacol* **160**: 1048-1061.
10. **Uematsu, T., Nakano, M., Kosuge, K., Kanamaru, M., and Nakashima, M.** 1993. The pharmacokinetics of the beta 2-adrenoceptor agonist, tulobuterol, given transdermally and by inhalation. *Eur J Clin Pharmacol* **44**: 361-364.
11. **Bristow, M.R., and Ginsburg, R.** 1986. Beta 2 receptors on myocardial cells in human ventricular myocardium. *Am J Cardiol* **57**: 3F-6F.
12. **Gong, H., Sun, H., Koch, W.J., Rau, T., Eschenhagen, T., Ravens, U., et al.** 2002. Specific beta(2)AR blocker ICI 118,551 actively decreases contraction through a G(i)-coupled form of the beta(2)AR in myocytes from failing human heart. *Circulation* **105**: 2497-2503.