Kobe University Repository : Kernel

PDF issue: 2025-12-04

Solitary Fibrous Tumor in the Parapharyngeal Space

Hashimoto, Dai
Inoue, Hiroyuki
Ohbayashi, Chiho
Nibu, Ken-ichi

(Citation)
Otolaryngology - Head and Neck Surgery,134(3):535-536

(Issue Date)
2006-03

(Resource Type)
journal article

(Version)
Accepted Manuscript

(URL)
https://hdl.handle.net/20.500.14094/90000309

Solitary fibrous tumor in the parapharyngeal space: a case report

Dai Hashimoto1), Hiroyuki Inoue1), Chiho Ohbayashi2), Ken-ichi Nibu1) 3).

1) Department of Otolaryngology-Head and Neck Surgery

Kobe University Hospital, Kobe, Japan

2) Department of Pathology, Kobe University Hospital

Kobe, Japan

3) Corresponding Author:

Ken-ichi Nibu, M.D., Ph.D.

Department of Otolaryngology-Head and Neck Surgery

Graduate School of Medicine, Kobe University

Kusunoki-cho 7-5-1, Chuo-Ku, Kobe 650-0017, Japan

TEL 078-382-6020 FAX 078-382-6039

Email nibu@med.kobe-u.ac.jp

Running Title: Solitary fibrous tumor

Key Words: solitary fibrous tumor, parapharyngeal space

Introduction

Solitary fibrous tumor (SFT) is a mesenchymal tumor, which usually arises from pleura (1). Although SFTs recently have been reported in various other regions, SFT in the head and neck is still rare and has often been misdiagnosed due to its rarity (2) (3) (4). In this article, we present a case of SFT arising in the parapharyngeal space. The clinical presentation, surgical management and pathological findings are described.

Case Report

A 19-year-old Japanese man initially visited our hospital with a 3-year history of limited right shoulder abduction and a 6-month history of swelling in the throat. Physical examination detected a large smooth swelling in the right oropharynx. An elastic smooth lump was also palpable in the right upper neck.

No trismus was observed. Computed tomography (CT) scan showed a heterogeneously enhanced large mass in the right pre-styloid par apharyngeal space. Carotid artery and internal jugular vein were displaced laterally by this lesion. Magnetic resonance imaging (MRI) showed this lesion to be clearly circumscribed with lobulated contour, showing homogenous high signal intensity on T1-weighted images and heterogeneous high signal intensity on T2-weighted images.

Considering these findings, we diagnosed this case as paraganglioma involving the spinal accessory nerve and planned the surgical treatment. Salivary gland tumor arising from the deep lobe of parotid gland and schwannoma were considered as differential diagnosis. To minimize the blood loss during resection, the right ascending pharyngeal artery was embolized the day before the surgery. The transcervical approach was used for the resection. Anterior dislocation of the mandible and removal of the mastoid tip provided a sufficient surgical field for the tumor in the parapharyngeal space to be successfully resected. The spinal accessory nerve was sacrificed, since the nerve was involved in the lobulated tumor. No adhesion was observed between the parotid gland and the tumor. Gross examination showed the tumor to be lobulated with smooth surface, measuring 70×50×25 mm. Histopathological examination demonstrated prominent vascularity with "haemangio-pericytomatous pattern". The tumor was mainly composed of spindle cells with varying amount of collagen, which is known as "patternless pattern". Immunohistochemically, the tumor tissues were strongly positive for CD34 but negative for S-100.

On the basis of these findings, the tumor was diagnosed as SFT. The postoperative course was uneventful. Transient facial nerve paralysis was observed but successfully disappeared within 3 months. The patient has been followed up for one year with no evidence of disease.

Discussion

SFT is traditionally known as a tumor arising from pleura (1). Recently, SFTs have been reported in various other regions, including head and neck, but are rarely seen in parapharyngeal spaces. To date, only five cases have been reported in the English literature (2) (3) (4). SFTs in the parapharyngeal space cause symptoms, such as sore throat, difficulty in swallowing, change of voice, trismus, otologic disorder, enlarged tonsil, nasal obstruction and paralysis of the soft palate and tongue (2) (3) (4). As for imaging, SFTs are seen as well-defined, lobulated and homogeneous iso-density lesions on plain CT scans and as heterogeneously enhanced lesions on contrast CT scans. On MRI imaging, SFTs are observed as hypo- to iso-intensity lesions on T1-weighted MRI, as heterogeneous high intensity lesion on T2-weighted MRI and as lesions with varying degrees of contrast enhancement on

gadolinium-enhanced T1-weighted MRI (4). Due to its rarity, uncommon location and various degree of enhancement, in the previously reported cases as well as our case, the diagnosis of SFT was not made until the excised tumor was subjected to histopathology and immunohistochemistry.

Microscopically, SFTs are not encapsulated but clearly circumscribed with fibrous tissues. They are composed of spindle cells with a varying amounts of collagen arranged randomly, which is known as “patternless pattern” (1). In addition, various vascularity and numbers of spindle cells are located in collagenous background, which have been described as “hemangiopericytomatous pattern” (1) as shown in the present case. Immunohistochemically, SFT reveals diffuse and strong positivity for CD34 and negative for S-100 protein, as also seen in the present case.

So far, SFTs arising in the head and neck region are reportedly non-malignant. However, 13-37% of reported SFTs in the other regions were associated with local recurrence or histological malignancy (1). Large tumor size, high cellularity, pleomorphism, numerous mitoses, presence of necrosis and

invasion into surrounding tissue suggest aggressive behavior (1). The recommended treatment is complete resection with a sufficient margin (5). Although postoperative adjuvant treatment with radiotherapy and/or chemotherapy has been performed, its effect remains undetermined (3). Resectability is the single most important indicator of clinical outcome (1). The tumor should be regarded as potentially malignant with recurrence up to 30 years after surgical excision (5). In the present case, the tumor was huge and the paralysis of the spinal accessory nerve due to the tumor involvement was observed. Even though a complete resection was perfromed, long-term and careful follow-up should be performed in the present case.

References

1. England DM, Hochholzer L, McCarthy MJ. Localized benign and malignant fibrous tumors of the pleura. A clinicopathologic review of 223 cases. Am J Surg Pathol 1989;23:640-58.

2. Al-Sinawi A, Johns AN. Parapharyngeal solitary fibrous tumor: an incidental finding at ENT examination. J Laryngol Otol 1994;108:344-7.

3. Gangopadhyay K, Taibah K, Manohar MB, et al. Solitary fibrous tumor of the parapharyngeal space: a case report and review of the literature. Ear Nose Throat J 1996;75:681-4.

4. Jeong AK, Lee HK, Kim SY, et al. Solitary fibrous tumor of the parapharyngeal space. MR imaging findings. Am J Neuroradiol 2002;23:473-5.

5. Goodlad JR, Fletcher CD. Solitary fibrous tumors arising at unusual sites; analysis of a series. Histopathology 1991;19:515-22.

Legends

Fig 1. Imaging and pathological findings of solitary fibrous tumor. A: Enhanced CT scan. The tumor had a well-defined margin and lobulated contour. Carotid artery and internal jugular vein were dislocated laterally. B: Hematoxylin-Eosin stain (×10). A well-circumscribed tumor consisted of spindle cells with a varying amounts of collagen arranged randomly, which is called “patternless pattern”. There were also focal areas showing hemangiopericytoma-like pattern. C: Immunohistochemical staining (×40). The neoplastic cells were positive for CD34.

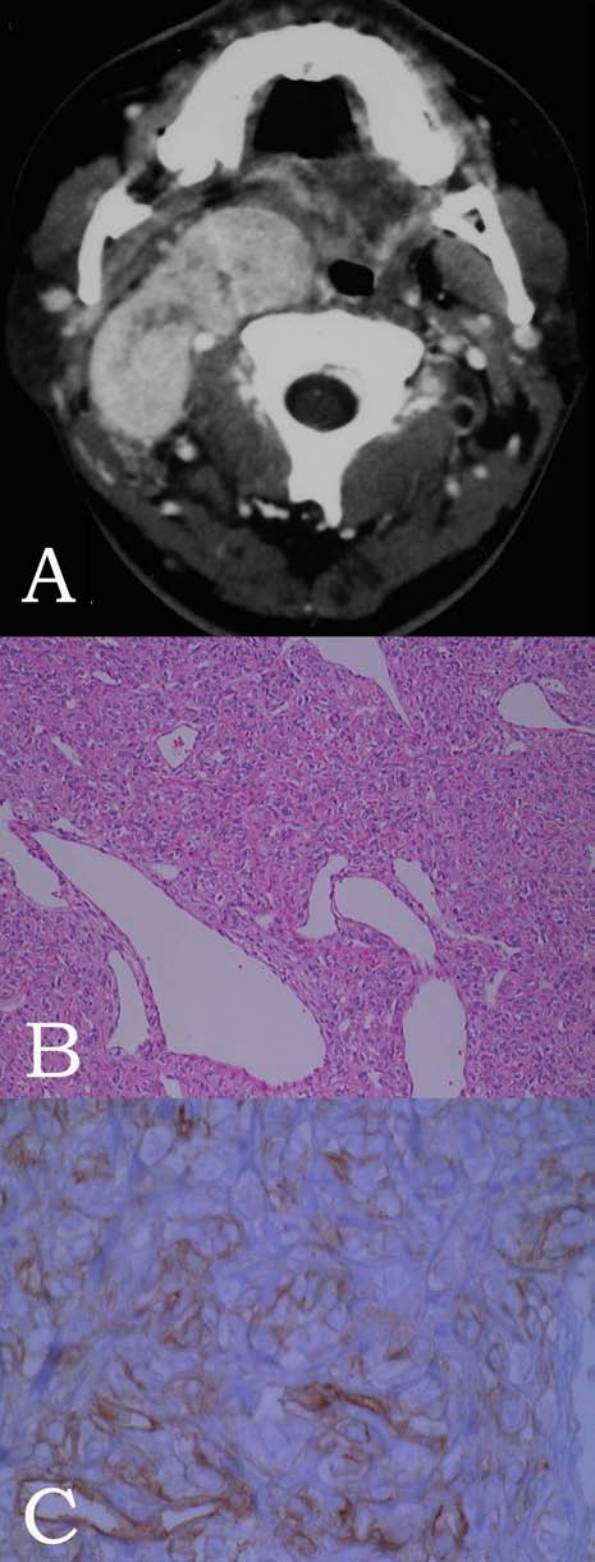
A
B
C