Kobe University Repository : Kernel

PDF issue: 2026-11-27

Radiculopathy due to malignant melanoma in the sacrum with unknown primary site

Kakutani, Kenichiro
Doita, Minoru
Nishida, Kotaro
Miyamoto, Hiroshi
Kurosaka, Masahiro

(Citation)
European Spine Journal,17(Supplement 2):271-274

(Issue Date)
2007-12-13

(Resource Type)
journal article

(Version)
Accepted Manuscript

(URL)
https://hdl.handle.net/20.500.14094/90000867

Radiculopathy due to malignant melanoma in the sacrum with unknown primary site

Kenichiro Kakutani, M.D., Minoru Doita, M.D., Kotaro Nishida, M.D., Hiroshi Miyamoto M.D., Masahiro Kurosaka, M.D.

Dept. of Orthopaedic Surg., Kobe Univ. Graduate School of Med., Kobe, Japan

Address all correspondence and reprint requests to:

Minoru Doita M.D.,Ph.D.

7-5-1 Kusunoki-cho, chuo-ku, Kobe 650-0017, JAPAN

Tel: 81-78-382-5985, Fax: 81-78-351-6944

e-mail: doita@med.kobe-u.ac.jp

Radiculopathy due to malignant melanoma in the sacrum with unknown primary site

Structured abstract

Study design: a case report

Background: Melanoma is an interesting tumor, showing the appearance of metastasis without any trace of its primary lesion.

Objective: To report a very rare case of malignant melanoma in the sacrum with unknown primary origin.

Method: The authors present a case of a 52-year-old man who was admitted with increasing lower back, left buttock, and left lower extremity pain, and dysuria.

Results: Plain radiograph, computed tomography (CT) scan, and magnetic resonance imaging (MRI) revealed a destructive lesion in the sacrum and left ilium, which infiltrated the spinal canal and sacroiliac joint. The tumor cells were immunoreactive for HMB-45. The pathological diagnosis was malignant melanoma. No obvious primary malignant melanoma was detected on the skin surface, on the oral or anal mucosa, or in the fundus oculi. Following radiotherapy and chemotherapy, the severe buttock pain disappeared and the patient was able to walk without impediment. However the patient died nine months after initial diagnosis.

Conclusion: Malignant melanoma in the sacrum with an unknown primary site, showing S1 radiculopathy is reported for the first time. The melanoma could have been a metastatic tumor of the sacrum, although the primary site was not detected. The

incidence of primary melanoma is increasing faster than any other cancer. Thus treatment of patients with spinal metastasis of melanoma is an important challenge for orthopedic surgeons.

Key words: malignant melanoma, metastasis, sacrum, chemotherapy, spontaneous regression.

Introduction

Malignant melanoma is the most common form of fatal skin neoplasm. The melanoma arises from the skin, mucous membranes, and central nervous system, when the melanocytes undergo a malignant transformation leading to metastasis. This metastasis has been documented in most tissues of the body, including skin, lymph nodes, lung, liver, brain, kidney, thyroid and bone. However, metastasis of the bone in malignant melanoma is relatively rare and accounts for only 4 % of all cases reported [6, 8, 11, 12, 14]. Furthermore, the prevalence of clinically evident spinal metastasis from malignant melanoma is 2.4% [13]. The majority of spinal metastasis occurs in the lung, breast and prostate, and in renal cancer. Although spinal metastasis from malignant melanoma is very rare, the incidence of primary melanoma is increasing faster than any other cancer [3]. Therefore, orthopedic surgeons will increasingly need recommendations for a treatment and clinical course of patients with melanoma metastatic to the spine.

In addition, melanoma is an interesting tumor, showing the appearance of metastasis without any trace of its primary lesion. Only one case has been reported of a primary unknown malignant melanoma of the sacrum showing radiculopathy.

We report a very rare case of malignant melanoma of the sacrum whose primary lesion could not be detected, and an accompanying review of the literature.

The patient and their families were informed that data from the case would be submitted for publication, and gave their consent.

Case report

A 52-year-old man was admitted to our institution at August 2005 complaining of increasing lower back pain and radiating pain in the left buttock and left lower extremity accompanied by dysuria since May 2005.

Physical examination revealed a hard mass over the sacrum and left buttock which impeded him from standing. Neurologic examination revealed a left S1 motor deficit with paresis of the flexor hallucis longus and absence of the Achilles tendon reflex. The patient had developed paresthesia in the left thigh, and calf. Laboratory analysis showed levels of 5-S-cystein dopa were significantly elevated in the plasma (61.7 ng/ml (normal: below 12)).

A plain radiograph clearly showed the distribution of the sacrum. A computed tomography (CT) scan revealed a destructive lesion of the sacrum and left ilium, which infiltrated the spinal canal and sacroiliac joint. On magnetic resonance imaging (MRI) the lesion showed a slightly increase in signal intensity on T1 and T2-weighted images and extended dorsally and ventrally, obstructing the spinal canal.

A bone and ^{201}Tl scintigraphy showed a large uptake only in the left sacrum, and no

uptake in the thorax or abdomen. A CT scan and MRI of the thorax and abdomen revealed no abnormalities. No obvious primary lesion of malignant melanoma was detected anywhere on the skin surface, the upper and lower endoscopic examination did not reveal any abnormal lesion on the oral or anal mucosa. The patient has not removed any moles. History and findings suggested a possible diagnosis of metastatic bone tumor of the sacrum.

An open biopsy was performed and a dark tumor was detected in the left sacrum. Biopsy material was stained with hematoxylin-eosin, and with HMB-45 antibody immunohistochemically. The tumor cells had abundant eosinophilic cytoplasm and a large macro-nuclei, of which some contained melanin pigments in their cytoplasm. The tumor cells were immunoreactive for HMB-45. The pathological diagnosis was malignant melanoma. No obvious primary lesion was detected anywhere on the skin surface, on the oral or anal mucosa, or in the fundus oculi. Radiotherapy was given with 27 Gy to the sacrum and chemotherapy (DAC-Tam) was performed.

Three months after the patient's first visit, MRI showed the tumor size had slightly decreased. Although there were no remarkable changes in neurological deficits, the patient's severe buttock pain had disappeared after the treatment and he could walk with a cane. Nevertheless the patient died of the respiratory failure from lung metastasis nine months later from the initial diagnosis.**Discussion**

Primary unknown malignant melanoma is rare. Giuliano reported that the primary lesion could not be detected in 5.6% of 980 malignant melanoma patients [4]. The predominant sites of metastasis are the subcutaneous tissue, lymph node, skin or visceral sites [15]. Metastasis of the spine is also relatively rare and the prevalence of clinically evident spinal metastasis from melanoma is 2.4% [13]. Generally spinal metastasis shows paraplegia, so a primary unknown malignant melanoma of the sacrum showing radiculopathy is even rarer with only one case of spinal involvement having been reported in the English literature [7].

Milton et al [9, 10] proposed several possible etiologies for melanoma of unknown primary origin. In the present case, an antecedent, unrecognized primary melanoma might have undergone spontaneous regression for immunological reasons, and a skeletal metastasis of malignant melanoma is supposed to be the most frequent cause, since malignant melanoma of bone is an extremely rare neoplasm. However there is some possibility that the lesion could also have been in an internal organ and eluded clinical detection.

Anbari et al. demonstrated that patients with unknown primary site melanoma survived significantly longer than patients diagnosed with lymph node metastasis concurrent with a known cutaneous primary melanoma [1]. The overall five-year survival rate for primary unknown malignant melanoma was 28 % and the median survival was

seventeen months [15]. Several investigators have reported the prognosis of spinal metastasis with known primary sites [1, 13]. For overall survival, Spiegel investigated metastatic melanoma to the spine in 114 patients and reported a median survival time of 86 days, and for patients with neurological deficits, only 54 days [13]. In present case, the patient died nine months after initial diagnosis. Compared with previous report [5, 7], the prognosis of this patient was reasonable, since this patient had neurological deficits at initial diagnosis.

Treatment for spinal metastasis remains controversial partly due to poor prognosis. Spiegel suggested that surgical therapy should be considered for patients in reasonably good general health who have symptomatic spinal metastases and surgically resectable visceral disease limited to one other organ system [13]. On the other hand, the goal of management of metastatic bone tumor disease is to maintain function and relieve pain. Spinal pain and the neurological deficits associated with spine instability are always indications for bracing and sometimes require stabilization with surgery [2]. The treatment of skeletal pain arising from tumor that has not caused significant structural bone damage is aimed at arresting tumor growth. The treatment includes radiation therapy and chemotherapy. Ku et al [7] emphasized that radiation, in and itself, may ameliorate pain. In the present case, the chief complaint was increasing lower back pain with S1 radiculopathy that was pronounced at night. Thus we performed radiation

therapy and chemotherapy. Although the treatment for this case was ineffective in managing the tumor, the chief complaint was improved. As the incidences of primary melanoma are increasing faster than any other cancer [3], effective management and treatment of patients with spinal melanoma metastasis remains an important challenge for orthopedic surgeons.

Reference

1. Anbari KK, Schuchter LM, Bucky LP, et al (1997) Melanoma of unknown primary site: presentation, treatment, and prognosis-A single study. *Cancer* 79:1816-21.
2. Boland PJ, Lane JM, Sundaresan N (1982) Metastatic disease of the spine. *Clin Orthop Relat Res* 169:95-102.
3. Friedman RJ, Rigel DS, Silverman MK, et al (1991) Malignant melanoma in the 1990s: the continued importance of early detection and the role of physician examination and self-examinationof the skin. *CA Cancer J Clin* 41:201-226.
4. Giuliano AE, Moseley HS, Morton DL (1980) Clinical aspects of unknown primary melanoma. *Ann Surg* 191:98-104.
5. Gokaslan ZL, Aladag MA, Ellerhorst JA (2000) Melanoma metastatic to the spine: a review of 133 cases. *Melanoma Res* 10:78-80.
6. Holmes FF, Fouts TL (1970) Metastatic cancer of unknown primary site. *Cancer* 26:816-820.
7. Ku A, Henry A, Tunkel R, et al (1996) Lumbosacral Radiculopathy Secondary to L5 Metastatic Melanoma of Unknown Primary. *Arch Phys Med Rehabli* 77:307-309.
8. Lleander VC, Goldstein G., Horsley JS (1972) Chemotherapy in the management of metastatic cancer of unknown primary site. *Oncology* 26:265-270.
9. Milton CW, Lane-Brown MM, Gilder M (1967) Malignant melanoma with an occult

primary lesion. *Br J Surg* 54:651-658.

10. Milton G.W, Shaw HM, McCarthy WH (1977) Occult primary malignant melanoma: factors influencing survival. *Br J Surg* 64:805-808.

11. Moertel CG., Reitemeier RJ, Schutt AJ, et al (1972) Treatment of the patient with adenocarcinoma of unknown origin. *Cancer* 30:1469-1472.

12. Nystrom JS, Weiner JM, Wolf RM, et al (1979) Identifying the primary site in metastatic cancer of unknown origin. Inadequancy of roetgenographic procedures. *JAMA* 241:381-383.

13. Spiegel DA, Sampson JH, Richardson WJ, et al (1995) Metastatic melanoma to the spine. Demographics, Risk, Factors, and Prognosis in 114 patients. *Spine* 20:2141-2146.

14. Stewart JF, Tattersall MH, Woods RL, et al (1979) Unknown primary adenocarcinoma : incidence of overinvestigation and natural history. *Br Med J* 1:1530-1533.

15. Velez A, Walsh D, Karakousis CP (1991) Treatment of unknown primary melanoma. *Cancer* 68:2579-81.

Figure legend

Figure 1. Radiograph shows destructive osteolytic changes at the sacrum.

Figure 2. CT scan shows the poorly osteolytic lesion in the sacrum. The mass is invading subcutaneous tissue and pelvic cavity.

Figure 3. a,c: MRI on T1-weighted image. **b,d:** on T2-weighted image. MRI shows the lesion has a heterogeneous increase in signal intensity on T1 and T2 weighted images. The mass extends dorsally and ventrally, obstructing the spinal canal.

Figure 4. ^{201}Tl scintigraphy showing a large uptake only in the left sacrum in the early and late phase, and no uptake in the thorax or abdomen.

Figure 5. Biopsy material is stained with HE, histochemically (a) and immunohistochemically with HMB-45 antibody (b). The tumor cells have abundant eosinophilic cytoplasm and large macro-nuclei. Some of them contain melanin pigments in their cytoplasm. The tumor cells are immunoreactive for HMB-45. Original magnifications (a) ×100, (b) ×40.



Fig. 1 Radiograph shows destructive osteolytic changes at the sacrum



Fig. 2 CT scan shows the poorly osteolytic lesion in the sacrum. The mass is invading subcutaneous tissue and pelvic cavity

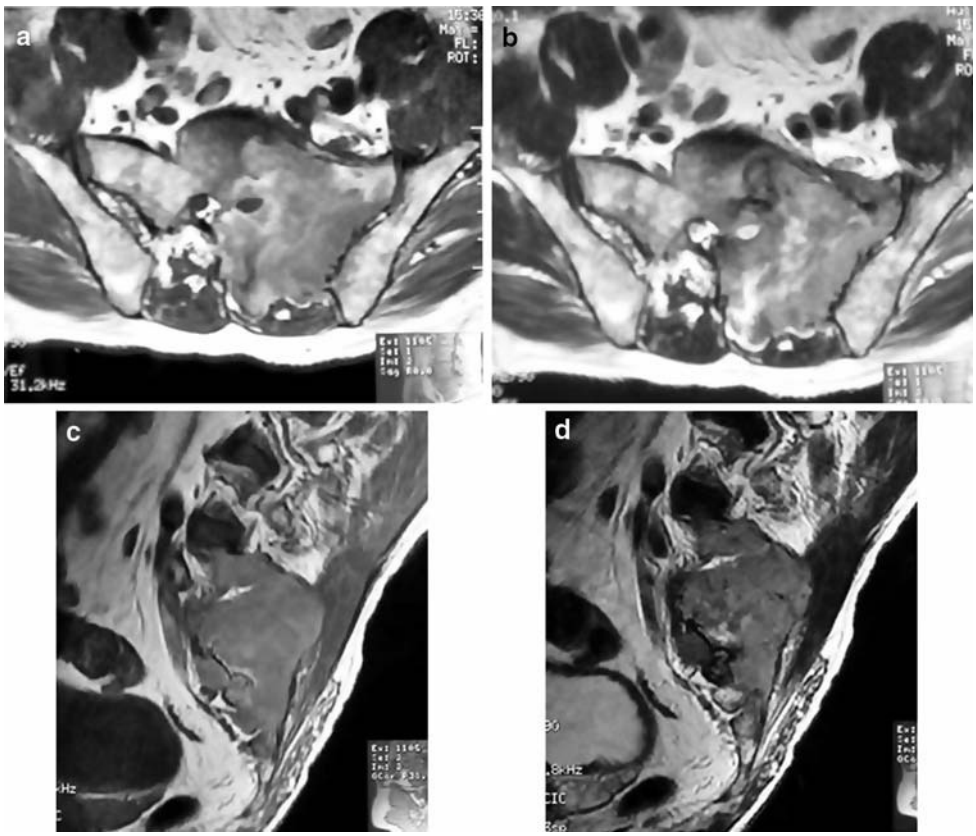

Fig. 3 **a**, **c** MRI on T1-weighted image. **b**, **d** On T2-weighted image. MRI shows the lesion has a heterogeneous increase in signal intensity on T1 and T2 weighted images. The mass extends dorsally and ventrally, obstructing the spinal canal

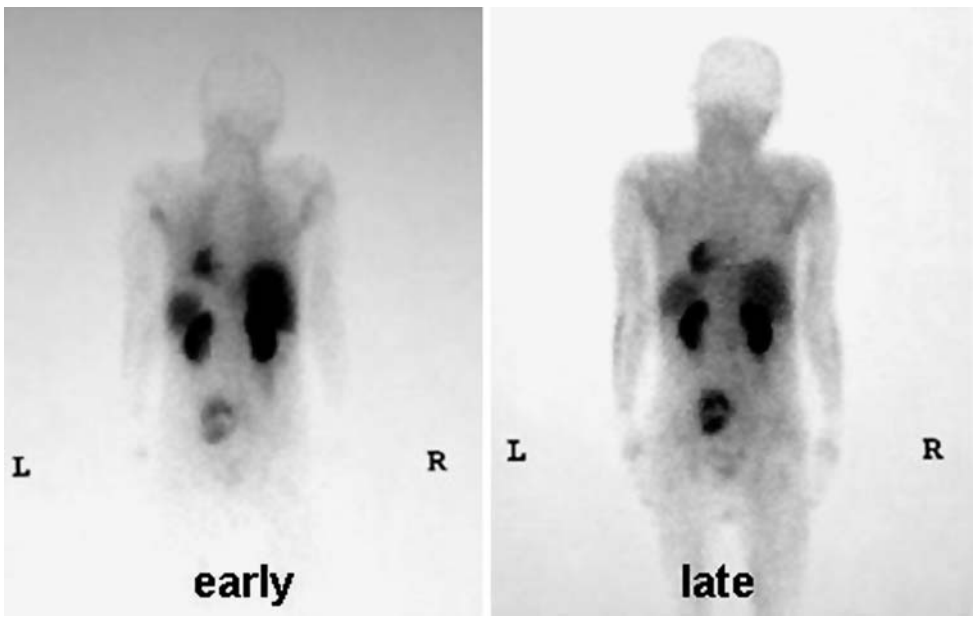

Fig. 4 ^{201}Tl scintigraphy showing a large uptake only in the left sacrum in the early and late phase, and no uptake in the thorax or abdomen

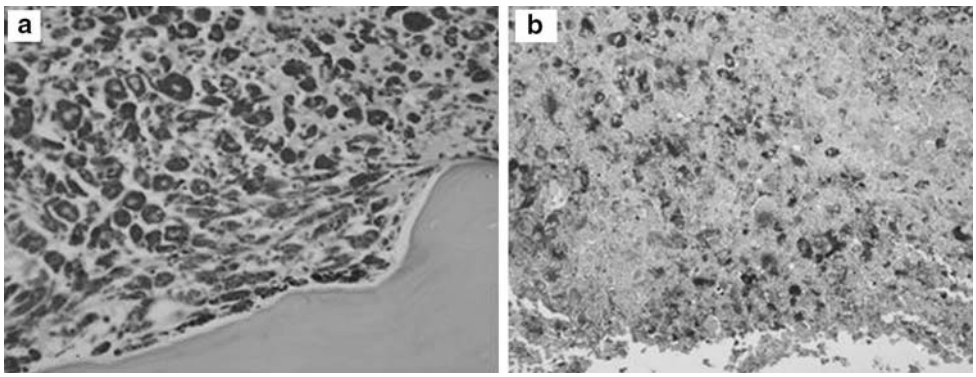

Fig. 5 Biopsy material is stained with HE, histochemically (**a**) and immunohistochemically with HMB-45 antibody (**b**). The tumor cells have abundant eosinophilic cytoplasm and large macro-nuclei. Some of them contain melanin pigments in their cytoplasm. The tumor cells are immunoreactive for HMB-45. Original magnifications **a** $\times 100$, **b** $\times 40$