Kobe University Repository : Kernel

PDF issue: 2025-12-05

Empyema necessitatis due to Pseudomonas aeruginosa in a child with cerebral palsy

Nishimura, Akihiro ; Yamaguchi, Hiroshi ; Ito, Yusuke ; Tokumoto, Shoichi ; Toyoshima, Daisaku ; Kasai, Masashi ; Maruyama, Azusa

(Citation)
Journal of Infection and Public Health,13(1):140-142

(Issue Date)
2020-01

(Resource Type)
journal article

(Version)
Version of Record

(Rights)
© 2019 The Authors. Published by Elsevier Limited on behalf of King Saud Bin Abdulaziz University for Health Sciences.
This is an open access article under the CC BY-NC-ND license (http://creativecommons.org/licenses/BY-NC-ND/4.0/).

(URL)
https://hdl.handle.net/20.500.14094/90007087

Journal of Infection and Public Health 13 (2020) 140–142

Contents lists available at ScienceDirect

Journal of Infection and Public Health

journal homepage: http://www.elsevier.com/locate/jiph

Short Report

Empyema necessitatis due to *Pseudomonas aeruginosa* in a child with cerebral palsy

Akihiro Nishimura[a], Hiroshi Yamaguchi[a,b,*], Yusuke Ito[c], Shoichi Tokumoto[a,b], Daisaku Toyoshima[a], Masashi Kasai[c], Azusa Maruyama[a]

[a] Department of Neurology, Hyogo Prefectural Kobe Children's Hospital, Hyogo, Japan
[b] Department of Pediatrics, Kobe University Graduate School of Medicine, Hyogo, Japan
[c] Division of Infectious Disease, Department of Pediatrics, Hyogo Prefectural Kobe Children's Hospital, Hyogo, Japan

ARTICLE INFO

Article history:
Received 5 February 2019
Received in revised form 25 March 2019
Accepted 19 May 2019

Keywords:
Debridement
Drainage
Pneumonia
Soft tissue infection

ABSTRACT

Empyema necessitatis (EN) is a rare complication of empyema in which the pleural infection spreads outside the pleural space. Lower airway infections are common among children with cerebral palsy (CP). Although harmless to healthy individuals, *Pseudomonas aeruginosa* can cause invasive infections, including CP, in immunocompromised hosts. *Mycobacterium tuberculosis* and *Actinomyces* spp. have been reported as common causative organisms of EN. However, EN caused by *P. aeruginosa* has never been reported. We report the case of an 8-year-old girl with CP without tracheotomy who was admitted to our hospital with complaints of fever and increased epileptic seizures. First, she was diagnosed with pneumonia and treated with antibiotics. However, seven days after admission, a palpable mobile mass overlying the lower part of the shoulder blade was noticed. Enhanced magnetic resonance imaging revealed broad high signal area on T2-weighted and diffusion-weighted images, indicating empyema of the left lower lung that had penetrated the pleural wall and spread to the subcutaneous area of the left back. Thus, she was diagnosed with EN. Twelve days after admission, *P. aeruginosa* was detected from the pus culture. Patients with CP who have chronic lung diseases, such as pneumonia, atelectasis, or empyema, may need careful follow up.

© 2019 The Authors. Published by Elsevier Limited on behalf of King Saud Bin Abdulaziz University for Health Sciences. This is an open access article under the CC BY-NC-ND license (http://creativecommons.org/licenses/by-nc-nd/4.0/).

Introduction

Empyema necessitatis (EN) is a rare complication of empyema in which the pleural infection spreads outside the pleural space [1]. Lower airway infections such as pneumonia, atelectasis, or empyema are common among children with cerebral palsy (CP). Although harmless to healthy individuals, *Pseudomonas aeruginosa*, commonly residing in the airways of CP patients, can cause invasive infections [2,3].

Mycobacterium tuberculosis and *Actinomyces* spp. are the most common causative organisms of EN [4]. However, EN caused by *P. aeruginosa* has never been reported. In this article, we present a rare case of EN caused by *P. aeruginosa* in a child with CP.

Case report

An 8-year-old girl with CP without tracheotomy was admitted to our hospital with fever and increased epileptic seizures. She had a medical history of CP with severe mental and physical disability due to hypoxic ischemic encephalopathy during birth. Her medical history also included epilepsy requiring multiple anti-epileptic drugs and pneumonia or bronchitis resulting in hospitalization a few times each year. In the prior two years, she had been administered oral clarithromycin and clavulanate-amoxicillin and intravenous ampicillin-sulbactam, tazobactam-piperacillin, metronidazole, and vancomycin. She had received all routine vaccinations and had no exposure to animals or sick people.

Examination revealed fever, tachycardia, tachypnea, peripheral circulatory disturbance, and decreased breath sounds in the left lower lung. Laboratory data were unremarkable except for leukocytosis and elevated C-reactive protein. Chest X-ray revealed infiltration at the lower left lung without pleural effusion. She was diagnosed with pneumonia and started intravenous ampicillin-sulbactam. Two days after admission, her fever continued. The

* Corresponding author at: Department of Neurology, Hyogo Prefectural Kobe Children's Hospital, 1-6-7 Minatojimaminamimachi, Chuo-Ku, Kobe, Hyogo 650-0047 Japan.
E-mail address: hiyamagu@med.kobe-u.ac.jp (H. Yamaguchi).

https://doi.org/10.1016/j.jiph.2019.05.013
1876-0341/© 2019 The Authors. Published by Elsevier Limited on behalf of King Saud Bin Abdulaziz University for Health Sciences. This is an open access article under the CC BY-NC-ND license (http://creativecommons.org/licenses/by-nc-nd/4.0/).

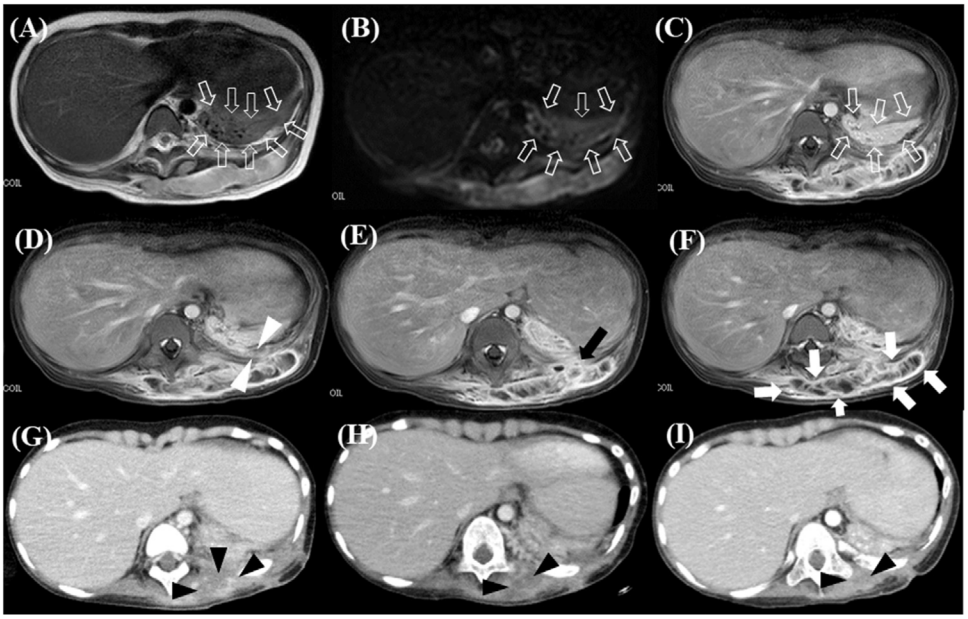

Fig. 1. Magnetic resonance imaging (MRI) seven days after admission ((A)–(F)) and computed tomography (CT) 13 days (G) and 24 days (H) after admission and a month after discharge (I). T2-weighted image (T2WI) (A) and diffusion-weighted image (DWI) (B) of MRI revealed high intensity area, indicating empyema in the left lower lobe of the lung (open white arrow). Enhanced MRI (craniocaudal direction (C)–(F)) showed that the caudal part of empyema of the left lung had penetrated the pleural wall (white arrow head; (D)) and spread to the subcutaneous area (black arrow; (E) of extrathoracic tissue of the left back (white arrow; (F)), consistent with empyema necessitatis. CT after 13 days (G) showed decreased subcutaneous abscess. However, enhanced lesions were still present (black arrow head). CT after 24 days (H) and a month after discharge (I) showed no enhanced area and new subcutaneous abscess (black arrow head).

antibiotics were changed to intravenous cefotaxime. However, her fever could not be resolved. Seven days after admission, a palpable, soft, mobile mass (15 cm × 15 cm) overlying the lower part of the shoulder blade was noticed with no associated erythema, warmth, or crepitus. Magnetic resonance imaging (MRI) on the same day revealed high signal area on the T2-weighted image (Fig. 1(A)) and diffusion-weighted image (Fig. 1(B)), indicating empyema of the left lung that had penetrated the pleural wall and spread to the subcutaneous area of the left back (enhanced MRI (Fig. 1(C)–(F)). Thus, she was diagnosed with EN. Since sputum culture for the latest hospitalization was positive for *P. aeruginosa*, antibiotics were changed to intravenous piperacillin-tazobactam. The next day (eight days after admission), a small surgical incision was made, and a large amount of pus and necrotic tissue were removed, and then a drain tube was inserted. Twelve days after admission, *P. aeruginosa* was solely detected from pus culture (anaerobic culture and polymerase chain reaction for *Mycobacterium* complex were negative). Susceptibility testing showed a multi-susceptibility pattern. Therefore, we changed intravenous piperacillin-tazobactam to piperacillin. As fever continued and a small amount of enhanced subcutaneous abscess lesion was still shown by enhanced computed tomography (CT) 13 days after admission (Fig. 1(G)), open drainage and debridement of the subcutaneous abscess were performed (Fig. 2), and a drain tube connected to a vacuum chamber was inserted. Then, a large amount of subcutaneous pus and necrotic tissue were removed. Twenty-two days after admission, the drain tube was removed as effusion had stopped and her fever had finally resolved. CT revealed disappearance of subcutaneous abscess 24 days after admission (Fig. 1(H)). As there was no recurrent fever and her respiratory condition was stable, we changed the antibiotics to oral ciprofloxacin 55 days after admission. She was finally discharged from our hospital 59 days after admission. She was followed up on an outpatient basis with oral ciprofloxacin and was in good condition in the latest follow-up a month after discharge with oral ciprofloxacin. CT on the same day revealed no new abscess. However, empyema of the left lung remained (Fig. 1(I)). We decided to continue the oral antibiotic therapy.

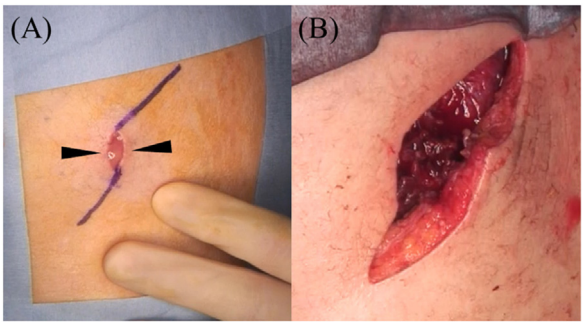

Fig. 2. Photographs of pus at the incision site (A) and the subcutaneous abscess after open drainage and debridement (B). Black arrow heads show cream-colored pus.

Discussion

We present a rare case of EN caused by *P. aeruginosa* in a child with CP. *Mycobacterium tuberculosis* is the most common etiologic organism of EN. Other bacteria have also been reported as causative organisms [1,4–9]. However, no case of *P. aeruginosa*-induced EN has been reported.

Chronic neurologic impairments, such as CP, can alter the bacterial flora in the upper and lower respiratory tracts [3,10]. Thorburn et al. reported that eighty-nine percent of children with CP carry abnormal bacterial flora and potential pathogens, most frequently *Pseudomonas* and *Klebsiella* species, and that lower airways and blood were the two most common infection sites of *P. aeruginosa* [10]. In general practice, children with CP are at an increased risk of aspiration and subsequent pneumonia, a common cause of hospitalization. The relationships between colonization of *P. aeruginosa* in children with CP and increased morbidity, prolonged hospitalization, and severity of pneumonia have been reported [3]. Therefore, *P. aeruginosa* can be responsible for severe invasive infections. Our case and previous studies suggest that children with CP who develop chronic lung diseases such as pneumonia, atelectasis, or

empyema should be carefully followed up. Host responses to *P. aeruginosa* infection are considered complex and dynamic, ranging from activation of the host immune response to suppression of host immunity [11]. As a result, the outcome of infection is based on complex interactions between the pathogen and host, including the genetic background and immune response of the host. Unfortunately, we did not evaluate the genetic background or immune status of the patient. Therefore, we could not determine the cause of EN in our patient. However, the patient experienced many previous episodes of pneumonia due to aspiration and continuous infiltration in the lower lungs. Thus, it was presumed that the difficulty in sputum expectoration and aspiration led to pneumonia, which may have been related to the residual *P. aeruginosa*, resulting in subsequent spread of empyema to the back wall, finally leading to EN. In addition, we could not ascertain why cases with EN due to *P. aeruginosa* have not been reported. We speculate that the occurrence of EN due to *P. aeruginosa* is very rare because EN itself is very rare, as is invasive *P. aeruginosa* infection through suppression of host immunity.

Clinical and radiological examination is essential for EN diagnosis. EN can be suspected in patients with pulmonary symptoms presenting with a chest wall mass, and enhanced CT and MRI are useful tools for confirming the diagnosis. Treatment for EN includes antibiotics and/or surgical drainage with thoracotomy or decortication [1]. Broad-spectrum antibiotics for possible pathogens should be commenced immediately after diagnosis, and the therapy can subsequently be altered according to the susceptibility patterns of the cultured pathogens. Surgical management should be considered when EN is poorly controlled, despite the appropriate medical treatment. As demonstrated in this case, surgical management is critical for some EN patients. Tube drainage, open drainage, and decortication should be considered according to the patient's physical condition, age, duration of symptoms, and other relevant clinical characteristics [1]. In our case, we performed debridement and tube drainage and prescribed antimicrobial therapy. Although thoracotomy might have been a better option, we did not perform it as our patient had severe physical disability with CP and would not endure the thoracotomy operation.

Conclusion

We present a rare case of EN due to *P. aeruginosa* in a child with CP. Physicians often find that patients with CP have indigenous *P. aeruginosa* in their airway. In cases in which such patients have chronic lower airway infections, the patients should be carefully followed up.

Authors contribution

Akihiro Nishimura: acquisition of data, drafting the article, final approval of the version.

Hiroshi Yamaguchi: acquisition of data, drafting the article, final approval of the version.

Yusuke Ito: interpretation of data, revising critically for important intellectual content, final approval of the version.

Shoichi Tokumoto: interpretation of data, revising critically for important intellectual content, final approval of the version.

Daisaku Toyoshima: interpretation of data, revising critically for important intellectual content, final approval of the version.

Masashi Kasai: interpretation of data, revising critically for important intellectual content, final approval of the version.

Azusa Maruyama: interpretation of data, revising critically for important intellectual content, final approval of the version.

Funding

No funding Sources.

Competing interests

None declared.

Ethical approval

Not required.

References

[1] Akgül AG, Örki A, Örki T, Yüksel M, Arman B. Approach to empyema necessitatis. World J Surg 2011;35:981–4.
[2] Emmanuel F, Kelly K, Dao N. *Pseudomonas aeruginosa* in chronic lung infections: how to adapt within the host? Front Immunol 2018;9:2416.
[3] Gerdung CA, Tsang A, Yasseen III AS, Armstrong K, McMillan HJ, Kovesi T. Association between chronic aspiration and chronic airway infection with *Pseudomonas aeruginosa* and other gram-negative bacteria in children with cerebral palsy. Lung 2016;194:307–14.
[4] Madeo J, Patel R, Gebre W, Ahmed S. Tuberculous empyema presenting as a persistent chest wall mass: case report. Germ 2013;3:21–5.
[5] Severo CB, Matter LB, Oliveira FD, Vargas AP, Schio SM, Camargo JD, et al. *Nocardia nova* causing empyema necessitatis after lung re-transplantation: a case report. Rev Soc Bras Med Trop 2016;49:523–6.
[6] Molina V, Arlandis M, Chiner E. Empyema necessitatis caused by *Corynebacterium jeikeium*:19th century questions, 21st century answers. Arch Bronconeumol 2018;54:53–4.
[7] Yauba MS, Ahmed H, Imoudu IA, Yusuf MO, Makarfi HU. Empyema necessitans complicating pleural effusion associated with proteus species infection: a diagnostic dilemma. Case Rep Pediatr 2015;2015:108174.
[8] Stein R, Manson DJ. Magnetic resonance imaging findings of empyema necessitates in a child with a group A *streptococcus* infection. Thorac Imaging 2012;27:W13–4.
[9] Noyes BE, Michaels MG, Kurland G, Armitage JM, Orenstein DM. *Pseudomonas cepacia* empyema necessitatis after lung transplantation in two patients with cystic fibrosis. Chest 1994;105:1888–91.
[10] Thorburn K, Jardine M, Taylor N, Reilly N, Sarginson RE, van Saene HK. Antibiotic resistant bacteria and infection in children with cerebral palsy requiring mechanical ventilation. Pediatr Crit Care Med 2009;10:222–6.
[11] Faure E, Kwong K, Nguyen D. *Pseudomonas aeruginosa* in chronic lung infections: how to adapt within the host? Front Immunol 2018;9:2416.