Kobe University Repository : Kernel

PDF issue: 2025-12-05

Effects of balloon pulmonary angioplasty for chronic thromboembolic pulmonary hypertension on remodeling in right-sided heart

Sumimoto, Keiko ; Tanaka, Hidekazu ; Mukai, Jun ; Yamashita, Kentaro ; Tanaka, Yusuke ; Shono, Ayu ; Suzuki, Makiko ; Yokota, Shun ; Suto,…

(Citation)
International Journal of Cardiovascular Imaging,36(6):1053-1060

(Issue Date)
2020-06

(Resource Type)
journal article

(Version)
Accepted Manuscript

(Rights)
© Springer Nature B.V. 2020. This is a post-peer-review, pre-copyedit version of an article published in International Journal of Cardiovascular Imaging. The final authenticated version is available online at: https://doi.org/10.1007/s10554-020-01798-5

(URL)
https://hdl.handle.net/20.500.14094/90007149

Effects of balloon pulmonary angioplasty for chronic thromboembolic pulmonary hypertension on remodeling in right-sided heart

Keiko Sumimoto, Hidekazu Tanaka*, Jun Mukai, Kentaro Yamashita, Yusuke Tanaka
Ayu Shono, Makiko Suzuki, Shun Yokota, Makiko Suto, Hiroki Takada
Kensuke Matsumoto, Yu Taniguchi, Noriaki Emoto, Ken-ichi Hirata

Division of Cardiovascular Medicine, Department of Internal Medicine,
Kobe University Graduate School of Medicine, Kobe, Japan

***Corresponding Author**
Hidekazu Tanaka, MD, PhD, FAHA, FACC, FASE
Division of Cardiovascular Medicine, Department of Internal Medicine,
Kobe University Graduate School of Medicine, Kobe, Japan
7-5-2, Kusunoki-cho, Chuo-ku, Kobe, 650-0017, Japan
Tel; +81-78-382-5846
Fax; +81-78-382-5859
E-mail; tanakah@med.kobe-u.ac.jp

Abstract

Purpose: Remodeling in the right-sided heart plays an important role in the management of pulmonary hypertension (PH) patients. However, the effect of balloon pulmonary angioplasty (BPA) on right ventricular (RV) and right atrial (RA) morphology of patients with chronic thromboembolic pulmonary hypertension (CTEPH) remains uncertain.

Methods: This study involved 45 CTEPH patients who underwent BPA with mean pulmonary artery pressure (mPAP) of 37.0mmHg (all≥25mmHg). All patients underwent echocardiography and right-heart catheterization at baseline and 3 months after BPA. RV and RA remodeling was assessed as RV and the RA area, and RV systolic function was calculated by averaging peak speckle-tracking longitudinal strain of the RV free-wall (RV free-wall strain).

Results: Significant reverse remodeling in the right-sided heart was observed after BPA, resulting in improvement of mPAP and pulmonary vascular resistance (RV area: from 15.0±5.3 cm^2 to 9.6±3.0 cm^2, $p<0.0001$; RA area: from 17.3±6.6 cm^2 to 13.4±3.8 cm^2, $p=0.0002$; RV free-wall strain: from 15.9±5.6% to 21.2±4.9%, $p<0.0001$). Furthermore, multiple regression analysis showed that the baseline RV area was an independent predictor of post-BPA normalization of RV systolic function defined as RV free-wall strain ≥20% (odds ratio=1.16, $p=0.0305$). Interestingly, significant RV reverse remodeling was also observed after additional BPA even in 18 CTEPH patients with residual pulmonary arterial stenosis, whose mPAP was normalized after BPA (RV area: from 11.5±3.8 cm^2 to 9.2±3.8 cm^2, $p=0.0045$; RV free-wall strain: from 17.2±4.8% to 22.8±7.4%, $p=0.0216$).

Conclusion: Significant reverse remodeling in the right-sided heart, as well as hemodynamic improvement, was observed in CTEPH patients after BPA.

Key words; Echocardiography, Chronic thromboembolic pulmonary hypertension, Balloon pulmonary angioplasty

INTRODUCTION

Although the factors influencing prognosis for pulmonary hypertension (PH) patients are thought to vary widely, right ventricular (RV) systolic function is one of the most important determinants of outcome for PH patients [1-6], especially RV free-wall longitudinal strain determined by means of two-dimensional speckle-tracking can be more sensitive and accurate for the diagnosis of RV systolic dysfunction in patients with PH, as well as with left-sided heart failure (HF), myocardial infarction, cardiomyopathies, and valvular heart diseases [7]. In addition, chronic increases in pulmonary artery pressure (PAP) and pulmonary vascular resistance (PVR) in PH patients lead to RV remodeling, resulting in RV dysfunction and subsequent right-sided HF and death [8]. Also, right atrial (RA) remodeling is thought to be an indicator of RA pressure, thus also reportedly making this an important prognostic marker for PH patients [9-11]. Therefore, remodeling in the right-sided heart, including its RV systolic function, can play an important role in the management of PH patients.

Chronic thromboembolic pulmonary hypertension (CTEPH) is classified within Group 4 PH [12], which is characterized pathologically by organized thromboembolic material and by altered vascular remodeling initiated or potentiated by a combination of defective angiogenesis, impaired fibrinolysis and endothelial dysfunction [13] [14]. While pulmonary endarterectomy (PEA) is the main therapy after optimal medication~~s~~ for eligible CTEPH patients, for inoperable patients, balloon pulmonary angioplasty (BPA) is an alternative therapy choice [11, 15-17]. However, the association of BPA with RV and RA morphologic changes in the right-sided heart of CTEPH patients remains uncertain. Our aim was thus to investigate the effect of BPA on right-sided heart remodeling in CTEPH patients.

Materials and Methods

Study population

We prospectively recruited 45 CTEPH patients who underwent BPA at Kobe University Hospital between August 2011 and July 2019. The diagnosis of CTEPH was based on the two following findings obtained after at least 3 months of effective anticoagulation: 1) mean PAP (mPAP) ≥25 mmHg with pulmonary artery wedge pressure ≤15 mmHg as measured by right-heart catheterization (RHC); 2) chronic thromboembolic obstruction of the pulmonary artery identified with lung scan, multidetector computed tomography angiography, or pulmonary angiography [18]. Patients who had undergone PEA or who had very severe valvular diseases were excluded from this study. This study was approved by the local ethics committee of our institution (No. B190262).

BPA candidates and procedure

All CTEPH patients were considered to have inoperable diseases if they had distal, surgically inaccessible thrombi after at least 3 months of anticoagulation therapy. Selection of BPA or PEA was confirmed by the PH team at our institute, including cardiac surgeons with expertise in performing PEA and cardiologists with expertise in performing BPA. The BPA procedure was described in previous reports of ours [17, 19, 20]. The intervention during one session was limited to one to two segments in one lobe to prevent severe reperfusion pulmonary edema after BPA.

Hemodynamic measurements

All patients underwent RHC for hemodynamic measurements. mPAP, PVR, RA pressure and cardiac output were calculated using the Fick principle. Investigators

blinded to the echocardiographic data acquired the pressure measurements. Follow-up RHC was performed 3 months after final BPA.

Echocardiographic examination

All echocardiographic studies were performed with commercially available echocardiography systems equipped with a 3.5-MHz transducer (Vivid E9; GE Vingmed Ultrasound AS, Horten, Norway). Routine digital grayscale 2-D cine loops and tissue Doppler cine loops were obtained from three consecutive beats with end-expiratory apnea and from standard apical and parasternal views. Sector width was optimized to allow for complete myocardial visualization while frame rate was maximized regardless of heart rate. Standard echocardiographic measurements were obtained according to the current guidelines of the American Society of Echocardiography (ASE) / European Association of Cardiovascular Imaging (EACVI)[21]. Digital data were transferred to dedicated offline software (EchoPAC version BTO8; GE Vingmed Ultrasound AS) for subsequent offline speckle-tracking analysis. After at least 3 months of effective anticoagulation, baseline echocardiography was performed 2.9±2.1 months before first BPA in this study. Follow-up echocardiography was performed within 0.9±2.1 day of follow-up RHC.

Assessment of remodeling in right-sided heart

Remodeling in the right-sided heart was assessed in terms of, respectively, the RV and RA area, and of RV systolic function. The RV area was obtained using planimetric tracing at end-systole from the annulus along the free-wall to the apex, and then back to the annulus along the interventricular septum from RV-focused apical 4-chamber views [22]. Similarly, the RA area was obtained using planimetric tracing at the end of the ventricular systole from the lateral aspect of the tricuspid annulus to the

septal aspect, excluding the RA endocardium, and excluding the inferior and superior vena cava and RA appendage from the RV focused apical 4-chamber view [22]. RV systolic function was assessed as RV free-wall strain by means of two-dimensional longitudinal speckle-tracking strain, which in turn was calculated by averaging each of the three regional peak systolic strains along the entire RV free-wall, and expressed as an absolute value [21]. In accordance with the current ASE/EACVI guideline, the predefined cutoff for RV systolic dysfunction was set at an RV free-wall strain of ≤ 20% [21].

Statistical analysis

Continuous variables were expressed as mean values and standard deviation for normally distributed data, and as the median and interquartile range for non-normally distributed data. Categorical variables were expressed as frequencies and percentages. The parameters of subgroups were compared by means of the Student *t* test or Mann-Whitney U test as appropriate. Multiple regression analysis based on stepwise selection was performed to identify independent determinants of normalized RV systolic function. The entry criterion for an individual item into the multiple regression model was $p<0.05$, and candidate parameters were RV area, and RA area,. The intraclass correlation coefficient was used to determine inter- and intra-observer reproducibilities for RV free-wall strain from 20 randomly selected patients using an identical cine-loop for each view. For all tests, a p value <0.05 was considered statistically significant. All the analyses were performed with commercially available software (MedCalc software version 18.1.1.; MedCalc Software, Mariakerke, Belgium).

RESULTS

Patient characteristics

The baseline clinical and echocardiographic characteristics of the 45 CTEPH patients are summarized in Table 1. Their mean age was 69.3 ± 11.3 years and 35 patients (78%) were female. mPAP and PVR were 37.0 ± 8.4 mmHg and 679.3 ± 391.4 dyne·sec·cm^{-5}, respectively. The intraclass correlation coefficient for inter-observer reproducibility of RV free-wall strain was 0.962 (95% confidence interval: 0.906-0.985), and the intraclass correlation coefficient for intra-observer reproducibility of RV free-wall strain was 0.989 (95% confidence interval: 0.970-0.996).

Clinical and hemodynamic measurements after BPA

The clinical and hemodynamic measurements between before and after BPA are summarized in Table 2. Patients underwent 4.0±1.2 BPA sessions, and all procedures were successfully performed without any deaths or major complications, such as severe reperfusion pulmonary edema requiring invasive mechanical ventilation. mPAP and PVR significantly decreased from 37.0±8.4 mmHg to 20.8±7.0 mmHg ($p<0.0001$), and from 679.3±391.4 dyne·sec·cm^{-5} to 300.4±292.3 dyne·sec·cm^{-5} ($p<0.0001$), respectively. Moreover, BNP level decreased, while 6-minute walk distance increased after BPA.

Remodeling in right-sided heart before and after BPA

Figure 1 shows the effect of BPA on remodeling in the right-sided heart. The RV area significantly decreased from 15.0±5.3 cm^2 to 9.6±3.0 cm^2 ($p<0.0001$), and RV free-wall strain increased from 15.9±5.6% to 21.2±4.9% ($p<0.0001$). In addition, the RA area significantly decreased from 17.3±6.6 cm^2 to 13.4±3.8 cm^2 ($p=0.0002$).

Fourteen patients (31%) had significant tricuspid regurgitation (TR), which was defined as more than moderate TR at baseline, and only 3 patients still had significant

TR at 3 months after BPA. Moreover, an improvement in severity of TR by a grade of 1 or more was observed in 24 patients among entire patients.

Association of normalized RV function with baseline parameters after BPA

Normalized RV systolic function after BPA, determined as RV free-wall strain≥20%, was observed in 26 patients (65%). Table 3 shows the results of the multiple regression analysis for the association of normalized RV function with baseline clinical and echocardiographic parameters. An important finding of the multiple regression analysis was that the RV area at baseline was an independent predictor of normalized RV systolic function after BPA (odds ratio: 1.16, 95% confidence interval: 1.01-1.34, p=0.0305).

Additional BPA for patients with residual pulmonary arterial stenosis and mPAP normalized after BPA

There were 18 patients whose mPAP was normalized after several BPA sessions but who still had residual pulmonary arterial stenosis. These patients subsequently underwent additional BPA sessions after at least 3 months to ameliorate symptoms and exercise capacity, and improve further hemodynamic parameters [20]. When compared the hemodynamic and echocardiographic measurements between before and after additional BPA in these patients, mPAP significantly decreased from 21.3±4.7 mmHg to 10.8±8.9 mmHg (p<0.0001), while PVR was somewhat reduced from 339.2±167.2 dyne·sec·cm^{-5} to 257.7±76.4 dyne·sec·cm^{-5} (p=0.0833) after additional BPA. In addition, the RV area showed a significant decrease-from 11.5±3.8 cm^2 to 9.2±3.8 cm^2 (p=0.0045), and RV systolic function a further increase from 17.2±4.8% to 22.8±7.4% (p=0.0216) (Figure 2). However, no significant change was

observed in the RA area after additional BPA from 13.5±2.8 cm^2 to 12.9±4.8 cm^2 (p=0.5256).

Figure 3 shows a representative case of RV-focused apical 4-chamber view at end-systole, and of the parameters of remodeling in the right-sided heart and hemodynamic parameters at baseline, after BPA and after additional BPA.

DISCUSSION

Key findings of our study are: 1) significant reverse remodeling in the right-sided heart as well as hemodynamic improvement was observed after BPA for CTEPH patients; 2) The RV area at baseline proved to be an independent predictor of normalized RV systolic function after BPA, and 3) RV reverse remodeling was also observed after additional BPA even in CTEPH patients whose mPAP was normalized after hemodynamic normalization.

Remodeling in right-sided heart of CTEPH patients

Chronic increases in PAP and PVR lead to the remodeling of the right-sided heart in PH patients. Specifically, the resultant morphological changes including progressive RV remodeling lead to RV dysfunction and subsequent right-sided HF and death [8]. Although there are many prognostic predictors for PH patients, not all of them can be used for individual patients [11]. The development of one of these predictors, RV systolic dysfunction in PH patients, has been associated with adverse outcomes regardless of the underlying clinical entity, so that the assessment of RV systolic function has become increasingly important in the management of such patients [3-6]. In addition, RV remodeling was also found to be associated with unfavorable outcome as well as RV systolic dysfunction in PH patients [23, 24]. On the other hand, RA

remodeling is reportedly an independent predictor of outcome for PH patients [9-11]. We previously reported that the RA area correlated with mean RA pressure as well as with tricuspid E/e' in PH patients, and that patients with RA remodeling, defined as RA area>18cm^2, suffered unfavorable outcomes compared to those without RA remodeling [9]. Moreover, RV systolic dysfunction and RA remodeling (RV free-wall strain≤19.4% and RA area >18cm^2) in PH patients were associated with worse long-term survival than that of other sub-groups. We also previously reported that reverse remodeling of the right-sided heart, such as demonstrated by RV and RA reverse remodeling mid-term (5.7 months) after administration of PH-specific drugs, was associated with favorable long-term outcome for PH patients [25]. Furthermore, preserved baseline RV systolic function, defined as RV free-wall strain>19%, and significant mid-term RV and RA reverse remodeling were associated with more favorable long-term outcomes. Therefore, not only RV remodeling but also overall remodeling in the right-sided heart can play a critical role in the management of PH patients.

Apart from its utility, however, the of remodeling in the right-sided heart on CTEPH patients or that of BPA on reverse remodeling in the right-sided heart in such patients have not been fully investigated. CTEPH is a life-threatening condition that leads to progressive right-sided HF and a poor prognosis [26, 27]. Although PEA is an established treatment for CTEPH with an acceptable mortality [28, 29], a limited post-operative reduction in PVR occurs in some patients with distal, surgically inaccessible thrombosis or significant but small vessel arteriopathy [26]. BPA has been reported to significantly decrease mPAP and PVR and, subsequently, improve the functional status and exercise capacity of patients who are not candidates for PEA due to distal-type CTEPH, severe concomitant comorbidity, or residual PH after PEA [11,

15-17]. Fukui et al found, by means of cardiac magnetic resonance imaging after BPA, a marked improvement in RV end-diastolic and end-systolic volume index, with concomitant improvements in the RV ejection fraction of 20 CTEPH patients [30]. They also showed that changes in RV volumes strongly correlated with changes in cardiac index and PVR after BPA. Kanar et al showed, by means of two-dimensional speckle-tracking strain, that BPA had a significant impact on the improvement of RV systolic function and RV mechanical dispersion of 20 CTEPH patients[31].

Impact of additional BPA on remodeling in right-sided heart

Significant RV reverse remodeling was observed in our study after additional BPA even in a subset of 18 patients whose mPAP was normalized after several BPA sessions. Shinkura, a colleague of ours, and his coworkers demonstrated the utility of additional BPA for targeting residual pulmonary arterial stenosis in CTEPH patients whose mPAP was normalized after several BPA sessions [20]. They showed that additional BPA can safely ameliorate symptoms and exercise capacity as a result of additional improvement in hemodynamics. Although it remains uncertain if additional BPA can lead to reverse remodeling in the right-sided heart even for CTEPH patients whose mPAP has been normalized, we observed that RV reverse remodeling as well as hemodynamic improvement occurred in such patients after additional BPA.

Clinical implications

Significant reverse remodeling in the right-sided heart was observed by us in CTEPH patients after BPA as well as in PAH patients after administration of PH-specific drugs, and RV remodeling before BPA was shown to be an independent predictor associated with normalized RV systolic function after BPA. As has been described above, remodeling in the right-sided heart before treatment and reverse

remodeling in the right-sided heart after treatment had a favorable impact on long-term outcome for PH patients. In addition, we showed that further RV reverse remodeling occurred even in CTEPH patients whose mPAP was normalized after several BPA sessions following additional BPA. Thus, the echocardiographic assessment of overall right-sided heart remodeling may constitute a promising non-invasive parameter for better management of CTEPH patients undergoing BPA. In addition, RV area at baseline was an independent predictor of normalized RV systolic function after BPA in this study. The early intervention for CTEPH patients may thus be considered at the time of the presence of RV remodeling to obtain favorable outcome.

Study limitations

This study comprised a small number of patients in a single-center retrospective study, so that future prospective studies with larger patient populations will be needed to validate our findings. In addition, remodeling of the right-sided heart was assessed in terms of the RV and RA areas, as well as RV free-wall strain, which were obtained from a 2-dimensional single echocardiographic image. Because RV and RA performance is in fact a 3-dimensional phenomenon, cardiac magnetic resonance imaging or novel 3-dimensional echocardiography would be a more accurate modality for assessment of remodeling of the right-sided heart. Finally, the period between baseline echocardiography and first BPA was not close in this study so that the effect of anticoagulation therapy on hemodynamic parameters may be suspected. However, all patients received at least 3 months of effective anticoagulation therapy, and tricuspid regurgitation pressure gradient by means of quick echocardiography just before first BPA remained unchanged. Thus, the improvement of hemodynamic parameters was thought to be due to BPA rather than anticoagulation therapy.

Conclusion

Significant reverse remodeling in the right-sided heart was observed in CTEPH patients after BPA. Our findings may well have clinical implications for better management of CTEPH patients referred for BPA.

Compliance with Ethical Standards

Conflict of interest:

Keiko Sumimoto declares that he has no conflict of interest. Hidekazu Tanaka declares that he has no conflict of interest. Jun Mukai declares that he has no conflict of interest. Kentaro Yamashita declares that he has no conflict of interest. Yusuke Tanaka declares that he has no conflict of interest. Ayu Shono declares that he has no conflict of interest. Makiko Suzuki declares that he has no conflict of interest. Shun Yokota declares that he has no conflict of interest. Makiko Suto declares that he has no conflict of interest. Hiroki Takada declares that he has no conflict of interest. Kensuke Matsumoto declares that he has no conflict of interest. Yu Taniguchi declares that he has no conflict of interest. Noriaki Emoto declares that he has no conflict of interest. Ken-ichi Hirata declares that he has no conflict of interest.

Ethical approval: This article does not contain any studies with human participants or animals performed by any of the authors.

Figure Legends

Figure 1: Box-whisker plots showing the parameters of remodeling in the right-sided heart including the RV area, RV free-wall strain and the RA area at baseline and after BPA in CTEPH patients, demonstrating that the RV area significantly decreased, RV free-wall strain significantly increased, and the RA area significantly decreased.

Figure 2: Box-whisker plots of the parameters of remodeling in the right-sided heart including the RV area, RV free-wall strain and the RA area at baseline and after additional BPA in a subset of 18 patients whose mPAP was normalized after several BPA sessions but who still had residual pulmonary arterial stenosis. The graphs show that the RV area significantly decreased and RV free-wall strain significantly increased, but no significant change occurred in the RA area.

Figure 3: Representative case of RV-focused apical 4-chamber view at end-systole, and of the parameters of the right-sided heart remodeling and hemodynamic parameters for a 72-year-old female CTEPH patients at baseline, after BPA, and after additional BPA.

References

[1] Farber HW, Loscalzo J (2004) Pulmonary arterial hypertension. N Engl J Med 351:1655-1665

[2] Simonneau G, Gatzoulis MA, Adatia I, Celermajer D, Denton C, Ghofrani A, Gomez Sanchez MA, Krishna Kumar R, Landzberg M, Machado RF, Olschewski H, Robbins IM, Souza R (2013) Updated clinical classification of pulmonary hypertension. J Am Coll Cardiol 62:D34-41

[3] Moskwa P, Lorentzen D, Excoffon KJ, Zabner J, McCray PB, Jr., Nauseef WM, Dupuy C, Banfi B (2007) A novel host defense system of airways is defective in cystic fibrosis. Am J Respir Crit Care Med 175:174-183

[4] Fine NM, Chen L, Bastiansen PM, Frantz RP, Pellikka PA, Oh JK, Kane GC (2013) Outcome prediction by quantitative right ventricular function assessment in 575 subjects evaluated for pulmonary hypertension. Circ Cardiovasc Imaging 6:711-721

[5] Haeck ML, Scherptong RW, Marsan NA, Holman ER, Schalij MJ, Bax JJ, Vliegen HW, Delgado V (2012) Prognostic value of right ventricular longitudinal peak systolic strain in patients with pulmonary hypertension. Circ Cardiovasc Imaging 5:628-636

[6] Motoji Y, Tanaka H, Fukuda Y, Ryo K, Emoto N, Kawai H, Hirata K (2013) Efficacy

of right ventricular free-wall longitudinal speckle-tracking strain for predicting long-term outcome in patients with pulmonary hypertension. Circ J 77:756-763

[7] Longobardo L, Suma V, Jain R, Carerj S, Zito C, Zwicke DL, Khandheria BK (2017) Role of Two-Dimensional Speckle-Tracking Echocardiography Strain in the Assessment of Right Ventricular Systolic Function and Comparison with Conventional Parameters. J Am Soc Echocardiogr 30:937-946 e936

[8] Chin KM, Kim NH, Rubin LJ (2005) The right ventricle in pulmonary hypertension. Coron Artery Dis 16:13-18

[9] Fukuda Y, Tanaka H, Motoji Y, Ryo K, Sawa T, Imanishi J, Miyoshi T, Mochizuki Y, Tatsumi K, Matsumoto K, Shinke T, Emoto N, Hirata K (2014) Utility of combining assessment of right ventricular function and right atrial remodeling as a prognostic factor for patients with pulmonary hypertension. Int J Cardiovasc Imaging 30:1269-1277

[10] Bustamante-Labarta M, Perrone S, De La Fuente RL, Stutzbach P, De La Hoz RP, Torino A, Favaloro R (2002) Right atrial size and tricuspid regurgitation severity predict mortality or transplantation in primary pulmonary hypertension. J Am Soc Echocardiogr 15:1160-1164

[11] Galie N, Humbert M, Vachiery JL, Gibbs S, Lang I, Torbicki A, Simonneau G,

Peacock A, Vonk Noordegraaf A, Beghetti M, Ghofrani A, Gomez Sanchez MA, Hansmann G, Klepetko W, Lancellotti P, Matucci M, McDonagh T, Pierard LA, Trindade PT, Zompatori M, Hoeper M, Group ESCSD (2016) 2015 ESC/ERS Guidelines for the diagnosis and treatment of pulmonary hypertension: The Joint Task Force for the Diagnosis and Treatment of Pulmonary Hypertension of the European Society of Cardiology (ESC) and the European Respiratory Society (ERS): Endorsed by: Association for European Paediatric and Congenital Cardiology (AEPC), International Society for Heart and Lung Transplantation (ISHLT). Eur Heart J 37:67-119

[12] Simonneau G, Montani D, Celermajer DS, Denton CP, Gatzoulis MA, Krowka M, Williams PG, Souza R (2019) Haemodynamic definitions and updated clinical classification of pulmonary hypertension. Eur Respir J 53

[13] Lang IM, Pesavento R, Bonderman D, Yuan JX (2013) Risk factors and basic mechanisms of chronic thromboembolic pulmonary hypertension: a current understanding. Eur Respir J 41:462-468

[14] Kim NH, Delcroix M, Jais X, Madani MM, Matsubara H, Mayer E, Ogo T, Tapson VF, Ghofrani HA, Jenkins DP (2019) Chronic thromboembolic pulmonary hypertension. Eur Respir J 53

[15] Feinstein JA, Goldhaber SZ, Lock JE, Ferndandes SM, Landzberg MJ (2001) Balloon pulmonary angioplasty for treatment of chronic thromboembolic pulmonary hypertension. Circulation 103:10-13

[16] Mizoguchi H, Ogawa A, Munemasa M, Mikouchi H, Ito H, Matsubara H (2012) Refined balloon pulmonary angioplasty for inoperable patients with chronic thromboembolic pulmonary hypertension. Circ Cardiovasc Interv 5:748-755

[17] Taniguchi Y, Miyagawa K, Nakayama K, Kinutani H, Shinke T, Okada K, Okita Y, Hirata KI, Emoto N (2014) Balloon pulmonary angioplasty: an additional treatment option to improve the prognosis of patients with chronic thromboembolic pulmonary hypertension. EuroIntervention 10:518-525

[18] Lau EM, Tamura Y, McGoon MD, Sitbon O (2015) The 2015 ESC/ERS Guidelines for the diagnosis and treatment of pulmonary hypertension: a practical chronicle of progress. Eur Respir J 46:879-882

[19] Kinutani H, Shinke T, Nakayama K, Taniguchi Y, Otake H, Takaya T, Osue T, Konishi A, Emoto N, Hirata KI (2016) High perfusion pressure as a predictor of reperfusion pulmonary injury after balloon pulmonary angioplasty for chronic thromboembolic pulmonary hypertension. Int J Cardiol Heart Vasc 11:1-6

[20] Shinkura Y, Nakayama K, Yanaka K, Kinutani H, Tamada N, Tsuboi Y,

Satomi-Kobayashi S, Otake H, Shinke T, Emoto N, Hirata KI (2018) Extensive revascularisation by balloon pulmonary angioplasty for chronic thromboembolic pulmonary hypertension beyond haemodynamic normalisation. EuroIntervention 13:2060-2068

[21] Lang RM, Badano LP, Mor-Avi V, Afilalo J, Armstrong A, Ernande L, Flachskampf FA, Foster E, Goldstein SA, Kuznetsova T, Lancellotti P, Muraru D, Picard MH, Rietzschel ER, Rudski L, Spencer KT, Tsang W, Voigt JU (2015) Recommendations for cardiac chamber quantification by echocardiography in adults: an update from the american society of echocardiography and the European association of cardiovascular imaging. J Am Soc Echocardiogr 28:1-39 e14

[22] Rudski LG, Lai WW, Afilalo J, Hua L, Handschumacher MD, Chandrasekaran K, Solomon SD, Louie EK, Schiller NB (2010) Guidelines for the Echocardiographic Assessment of the Right Heart in Adults: A Report from the American Society of Echocardiography. Journal of the American Society of Echocardiography 23:685-713

[23] van Wolferen SA, Marcus JT, Boonstra A, Marques KM, Bronzwaer JG, Spreeuwenberg MD, Postmus PE, Vonk-Noordegraaf A (2007) Prognostic value of right ventricular mass, volume, and function in idiopathic pulmonary arterial hypertension. Eur Heart J 28:1250-1257

[24] Brewis MJ, Bellofiore A, Vanderpool RR, Chesler NC, Johnson MK, Naeije R, Peacock AJ (2016) Imaging right ventricular function to predict outcome in pulmonary arterial hypertension. Int J Cardiol 218:206-211

[25] Sano H, Tanaka H, Motoji Y, Fukuda Y, Sawa T, Mochizuki Y, Ryo K, Matsumoto K, Emoto N, Hirata K (2015) Right ventricular function and right-heart echocardiographic response to therapy predict long-term outcome in patients with pulmonary hypertension. Can J Cardiol 31:529-536

[26] Piazza G, Goldhaber SZ (2011) Chronic thromboembolic pulmonary hypertension. N Engl J Med 364:351-360

[27] Hoeper MM, Mayer E, Simonneau G, Rubin LJ (2006) Chronic thromboembolic pulmonary hypertension. Circulation 113:2011-2020

[28] Jamieson SW, Kapelanski DP, Sakakibara N, Manecke GR, Thistlethwaite PA, Kerr KM, Channick RN, Fedullo PF, Auger WR (2003) Pulmonary endarterectomy: experience and lessons learned in 1,500 cases. Ann Thorac Surg 76:1457-1462; discussion 1462-1454

[29] Archibald CJ, Auger WR, Fedullo PF, Channick RN, Kerr KM, Jamieson SW, Kapelanski DP, Watt CN, Moser KM (1999) Long-term outcome after pulmonary thromboendarterectomy. Am J Respir Crit Care Med 160:523-528

[30] Fukui S, Ogo T, Morita Y, Tsuji A, Tateishi E, Ozaki K, Sanda Y, Fukuda T, Yasuda S, Ogawa H, Nakanishi N (2014) Right ventricular reverse remodelling after balloon pulmonary angioplasty. Eur Respir J 43:1394-1402

[31] Kanar BG, Mutlu B, Atas H, Akaslan D, Yildizeli B (2019) Improvements of right ventricular function and hemodynamics after balloon pulmonary angioplasty in patients with chronic thromboembolic pulmonary hypertension. Echocardiography

Table 1
Baseline characteristics of patients

	CTEPH Patients (n=45)
Age, years	69.3±11.3
Gender (Female), n (%)	35 (77.8)
Brain natriuretic peptide, pg/mL	71.2 [26.2-211.5]
6-minute walk distance, m	316.9±100.6
Hemodynamic parameters	
mPAP, mmHg	37.0±8.4
PVR, dyne· s^{-1}· cm^{-5}	679.3±391.4
Heart rate, bpm	74.0±9.5
Stroke volume, mL	53.9±19.3
Stroke volume index, mL/min/m^2	33.9±10.6
Cardiac output, L/min	3.9±1.9
Cardiac index, L/min/m^2	2.5±0.8
Mean RA pressure, mmHg	5.6±2.8
Echocardiographic parameters	
LV end-diastolic volume, mL	55.7±17.9
LV end-systolic volume, mL	18.9±9.3
LVEF, %	66.2±11.4
Left atrial volume index, mL/m^2	30.1±10.3
More than moderate TR, n (%)	14 (31)
TR-PG, mmHg	55.8±16.9
RV area, cm^2	20.7±5.0
RV mid dimeter, mm	31.2±7.7
RV basal dimeter, mm	35.4±6.8
RA area, cm^2	15.0±5.3
RA volume, mL	56.2±35.0
RV free-wall strain, %	15.9±5.6
RVFAC, %	28.2±13.1
TAPSE, mm	17.3±4.5

Data are mean ± SD for normally distributed data and median and interquartile range for non-normally distributed data, or n (%).
mPAP= mean pulmonary artery pressure; PVR= pulmonary vascular resistance; RA=

right atrial; bpm= beats per minute; LVEF= left ventricular ejection fraction; TR=tricuspid regurgitation, RV= right ventricular; RVFAC=right ventricular fractional area change; TAPSE=tricuspid annular plane systolic excursion

Table 2

Hemodynamic measurements baseline and 3 months after BPA

	Baseline	3 months after BPA	P value
Brain natriuretic peptide, pg/mL	71.2 [26.2-211.5]	22.7 [11.7-50.6]	0.0006
6-minute walk distance, m	316.9±100.6	374.0±101.2	0.0032
Hemodynamic parameters			
mPAP, mmHg	37.0±8.4	20.8±7.0	<0.0001
PVR, dyne· s^{-1}· cm^{-5}	679.3±391.4	300.4±292.3	<0.0001
Heart rate, bpm	74±9.5	66.0±18.7	<0.0001
Stroke volume, mL	53.9±19.3	60.5±18.7	0.0458
Stroke volume index, mL/min/m^2	33.9±10.6	38.8±10.4	0.0287
Cardiac output, L/min	3.9±1.9	3.9±1.3	0.9628
Cardiac index, L/min/m^2	2.5±0.8	2.5±0.6	0.9035
Mean RA pressure, mmHg	5.6±2.8	4.2±3.6	0.0748

Data are mean ± SD for normally distributed data and median and interquartile range for non-normally distributed data, or n (%).

All abbreviations as in Table 1.

Table 3
Multiple regression analysis for the association of normalized RV systolic function after BPA

	Univariate			Multivariate		
Covariate	OR	95%CI	p value	OR	95%CI	p value
Age	0.99	0.91-1.07	0.7539			
Gender	2.01	0.28-14.2	0.4834			
mPAP	0.97	0.80-1.17	0.7772			
PVR	1.00	0.99-1.01	0.2060			
Cardiac output	3.89	0.98-15.41	0.0529			
RV area	1.38	1.06-1.79	0.0171	1.16	1.01-1.34	0.0305
RA area	0.91	0.76-1.09	0.3033			

All abbreviations as in Table 1.

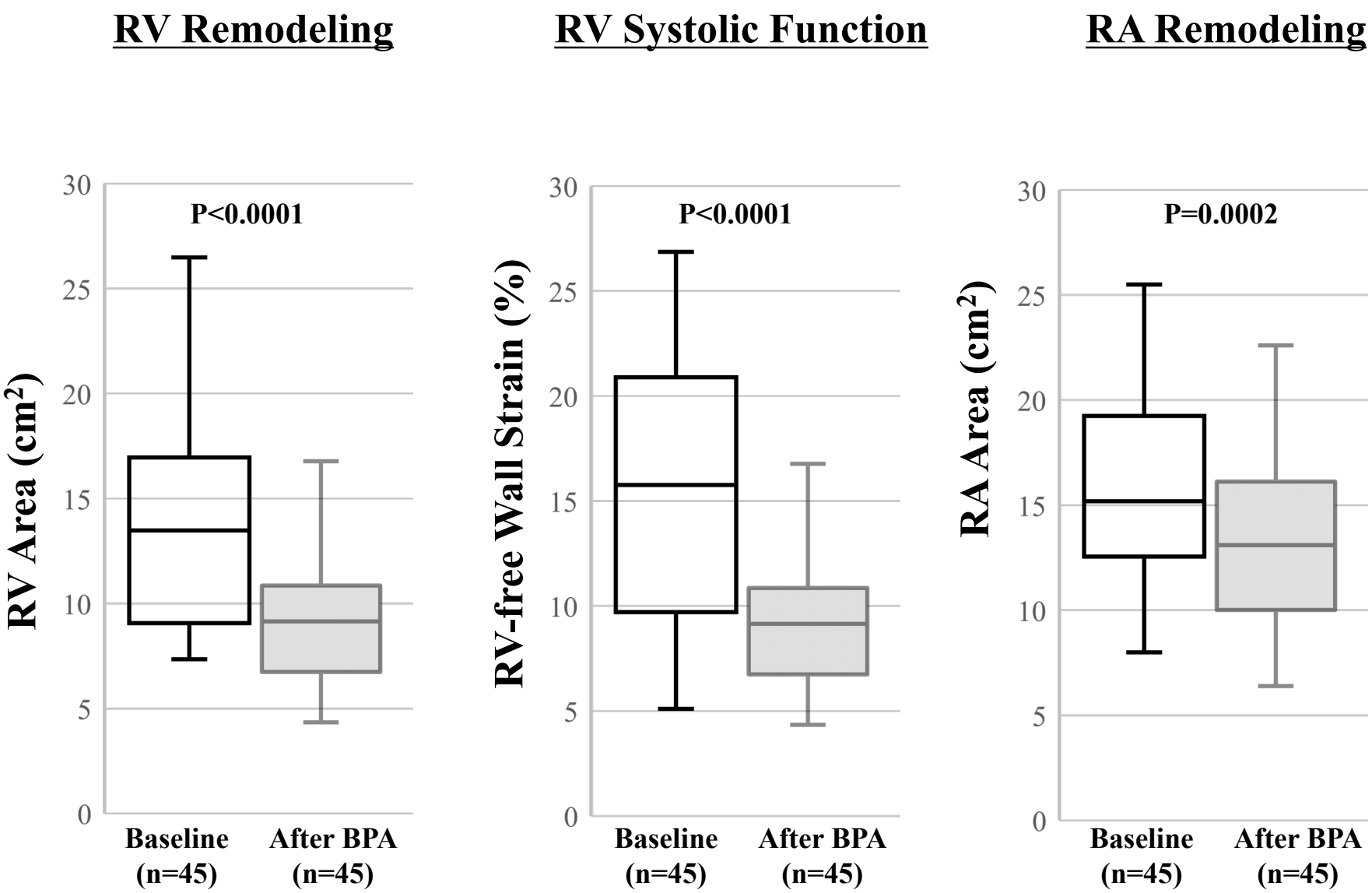
RV Remodeling
RV Systolic Function
RA Remodeling
RV Area (cm²)
RV-free Wall Strain (%)
RA Area (cm²)
P<0.0001
P<0.0001
P=0.0002
30
25
20
15
10
5
0
Baseline (n=45)
After BPA (n=45)

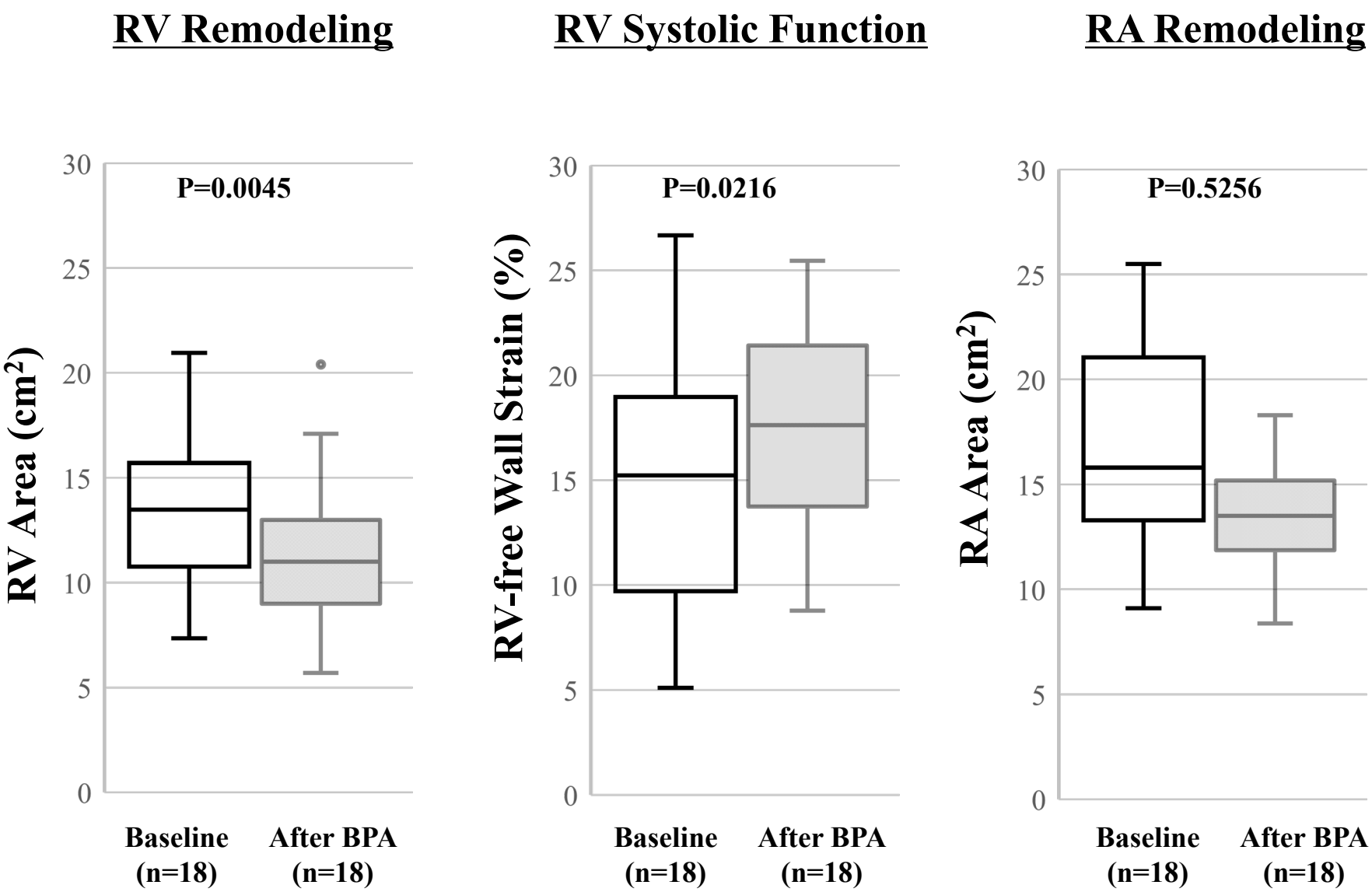
RV Remodeling
RV Systolic Function
RA Remodeling
P=0.0045
P=0.0216
P=0.5256
RV Area (cm2)
RV-free Wall Strain (%)
RA Area (cm2)
30
25
20
15
10
5
0
Baseline (n=18)
After BPA (n=18)

77-year-old female

Baseline		After BPA		After Additional BPA	
RV area	13.4cm^2	RV area	10.9cm^2	RV area	6.6cm^2
RV free-wall strain	9.9%	RV free-wall strain	16.1%	RV free-wall strain	21.9%
RA area	13.8cm^2	RA area	13.5cm^2	RA area	7.2cm^2
mPAP	38mmHg	mPAP	17mmHg	mPAP	16mmHg
PVR	1481dyne·sec·cm^{-5}	PVR	491dyne·sec·cm^{-5}	PVR	273dyne·sec·cm^{-5}