Kobe University Repository : Kernel

PDF issue: 2025-12-05

Solitary pancreatic lesion as the initial metastasis from osteosarcoma: Report of a rare case

Ikuta, Kemmei ; Kawamoto, Teruya ; Hara, Hitomi ; Fukase, Naomasa ; Morishita, Masayuki ; Kuroda, Ryosuke ; Akisue, Toshihiro

(Citation)
Journal of Orthopaedic Science,25(4):724-728

(Issue Date)
2020-07

(Resource Type)
journal article

(Version)
Accepted Manuscript

(Rights)
© 2017 The Japanese Orthopaedic Association. Published by Elsevier B.V.
This manuscript version is made available under the CC-BY-NC-ND 4.0 license
http://creativecommons.org/licenses/by-nc-nd/4.0/

(URL)
https://hdl.handle.net/20.500.14094/90007578

Solitary pancreatic lesion as the initial metastasis from osteosarcoma: report of a rare case.

Introduction

Osteosarcoma is the most common malignant bone tumor in childhood and adolescence, and its treatment consists of a combination of chemotherapy and surgical resection. The disease has a high metastatic potential, and common locations of metastasis are the lungs, pleurae, and bones; metastasis to the pancreas is extremely rare [1, 2]. We present a 42-year-old woman with an osteosarcoma in the proximal fibula who was found to have a pancreatic lesion as the initial metastasis on ^{18}F-fluorodeoxyglucose-positron emission tomography/computed tomography (FDG-PET)/CT 2 years after surgical treatment of the primary lesion. Pancreatic metastasis from osteosarcoma is extremely unusual; however, because surgical resection of metastatic lesions may have a survival benefit for the patient, surgeons treating patients with osteosarcoma must be aware of the pancreas as a potential metastatic site of osteosarcoma.

The patient was informed that data from the case would be submitted for publication, and gave us consent for possible academic use of the clinical information.

Case report

A 42-year-old woman was admitted to our hospital with pain and swelling in the lateral aspect of the right knee that had progressively worsened over 2 years. A physical examination on admission revealed slight swelling and tenderness around the proximal right fibula and the patient had pain on weight-bearing. The range of motion of the right knee was not limited, and weakness of muscles including the tibialis anterior was not observed.

Laboratory findings including white blood cell count, C-reactive protein, alkaline phosphatase, and lactate dehydrogenase levels were unremarkable. A plain radiograph (Fig. 1) and magnetic resonance imaging (MRI) scans (Fig. 2) of the right knee demonstrated an osteolytic destruction with irregular periosteal reaction and a diffuse abnormal signal in the marrow of the right fibular head. An open biopsy was performed, and histological examination showed that neoplastic osteoid production was present within fascicles of atypical spindle cells with hyperchromatic nuclei and mitotic figures. The diagnosis of osteosarcoma was confirmed histologically.

The patient received neoadjuvant chemotherapy with two cycles of high dose methotrexate 10,000 mg/m^2 alternating with doxorubicin 30 mg/m^2 on days 1 and 2, and

37 cisplatin 100 mg/m^2 on day 1 (MAP), and then she underwent wide resection of the
38 right proximal fibula followed by reconstruction of the lateral collateral ligament of the
39 right knee (Fig. 3). The histology of the resected specimen confirmed the diagnosis of
40 osteosarcoma with 40-50% necrosis rates (Fig. 4). After the surgery, the patient
41 underwent adjuvant chemotherapy with two cycles of MAP with addition of ifosfamide
42 15,000 mg/m^2, and follow-up images of radiography, computed tomography (CT), MRI,
43 and whole body ^{18}F-fluorodeoxyglucose-positron emission tomography (FDG-PET)/CT
44 indicated no evidence of local recurrence or distant metastasis.
45 However, 2 years after the surgical treatment, FDG-PET/CT showed abnormal uptake
46 in the tail of the pancreas with a standardized uptake value (SUV) of 6.9 without other
47 abnormalities (Fig. 5). The patient was asymptomatic and laboratory examination
48 results were within normal values. Dynamic CT revealed an enhancement of the lesion
49 in the pancreatic tail at the late phase (Fig. 6). Endoscopic ultrasound-guided fine needle
50 aspiration from the mass was performed (Fig. 7), and the section showed tumor
51 composed of polygonal and spindle-shaped cells with hyperchromatic nuclei. The
52 features were compatible with metastatic osteosarcoma. Laparoscopic distal
53 pancreatectomy was then performed, and histopathological examination of the resected
54 tissue showed atypical spindle cells; this finding was similar to the histology of the

55 primary lesion in the right proximal fibula, and the diagnosis of metastatic osteosarcoma
56 was confirmed (Fig. 8).
57 One year after surgical treatment for the pancreatic metastasis, metastases occurred in
58 both lungs and the patient underwent chemotherapy with three cycles of gemcitabine-
59 docetaxel combination (gemcitabine 900 mg/m^2 on days 1 and 8, and docetaxel 70
60 mg/m^2 on day 8 given after gemcitabine), then surgical resection of the metastatic
61 lesions in the lungs was performed. The patient remains well without local recurrence or
62 other metastases over 1 year following surgical treatment for the lung metastases.
63
64 **Discussion**
65 Osteosarcoma is the most common malignant bone tumor of childhood and
66 adolescence, and has a high metastatic potential. The most common sites of metastasis
67 are the lungs, pleurae, and bones. Less commonly, the liver, brain, and regional lymph
68 nodes are sites of metastasis, but metastases to the gastrointestinal system are rare [1-3].
69 Metastases to the pancreas are extremely rare, and only 2% of all pancreatic tumors are
70 metastatic lesions [4-7]. The primary sites of pancreatic metastasis are epithelial tissues
71 including the kidney, stomach, lungs, liver, breasts, ovaries, and thyroid; and non-
72 epithelial tissues such as the hematopoietic system, retroperitoneum, and bone and soft

73 tissues [4-7]. Among these, pancreatic metastasis from osteosarcoma is especially
74 unusual; moreover, pulmonary metastases usually occur before pancreatic involvement
75 [8], and a solitary pancreatic lesion as the initial metastasis from osteosarcoma has
76 never been reported, to the best of our knowledge.

77 Most patients with pancreatic metastasis do not have signs or symptoms [4-7] and our
78 patient was also asymptomatic. In the present case, the metastatic lesion in the pancreas
79 was detected by FDG-PET/CT but not by plain abdominal CT. FDG-PET/CT can be
80 helpful for systemic screening in the management of patients with cancer; however, its
81 sensitivity for pulmonary metastases may be lower than that of dedicated chest CT.
82 Moreover, the combined metabolic and morphological information from FDG-PET/CT
83 allows high diagnostic accuracy for the detection and staging of musculoskeletal tumors
84 compared with MRI [9-10], and several studies reported that FDG-PET/CT had a
85 sensitivity of 90% (86–93%) and a specificity of 85% (81–87%) to detect distant
86 metastatic lesions of bone sarcoma [11]. And, for evaluation of osseous metastases in
87 osteosarcoma, Hurley *et al*. reported that FDG–PET/CT demonstrated superior
88 sensitivity over bone scintigraphy [12].

89 However, the ability of FDG-PET/CT to differentiate between malignant and benign
90 tumors has been controversial because of false-positive and false-negative lesions [13].

91 Known false-positive lesions include some aggressive benign tumors, such as giant cell
92 tumor of the bone and osteoid osteoma. And, desmoid fibromatosis, inflammatory
93 lesions, and low grade malignant tumors, such as liposarcoma and chondrosarcoma, can
94 be false-negative lesions. In addition, lung metastases consisting of small nodules have
95 been reported to have little to no FDG uptake [11, 13, 14]. Therefore, for the depiction
96 of small lesions, other imaging modalities including CT and/or MRI, should be
97 considered [14]. Controversy still exists about the application of FDG-PET/CT in the
98 management of sarcoma patients, mainly because of its high cost. FDG-PET/CT is
99 usually much more expensive than other examinations [15]. The cost of FDG-PET/CT
100 is about US $850 (=100,000 Yen), while that of plain chest CT is $150, of enhanced
101 MRI is $250, and of bone scintigraphy is $400 under the current medical environment
102 in Japan [15], however cost-effectiveness of FDG-PET/CT was reported for staging,
103 management of metastases and/or treatment evaluation in several cancers [16, 17].
104 Although there are few data about its cost-effectiveness in the management of sarcoma
105 patients, FDG-PET/CT can be useful to detect unknown distant metastasis, especially
106 uncommon sites of metastasis, since blood or serum tests are often not effective in the
107 detection of local recurrence or disease dissemination [18].
108 Survival of patients with metastatic osteosarcoma is reported to be significantly

109 correlated with patient age, site of the primary tumor, histological response of the
110 primary tumor to preoperative chemotherapy, numbers and locations of metastases, and
111 completeness of surgical resection of all of the tumor sites, including metastatic lesions
112 [19]. The surgical approach to gastrointestinal system metastases is less well established
113 compared to that for the resection of pulmonary metastases; however, it has been
114 reported that long-term survival can be achieved by resection of isolated pancreatic
115 metastases [20, 21]. Treatment of primary or secondary pancreatic tumor is often
116 considered by the clinical stage of the patient and the resectability of the lesion, which is
117 determined by the size and the anatomic location [21, 22]. In primary pancreatic ductal
118 adenocarcinoma, only 20% are resectable, because 80% of patients present with
119 metastatic disease and/or with a locally advanced tumor at the initial diagnosis [23]. In
120 resectable cases, clinical outcome shows superior survival rate and less complication in
121 the patients with the lesion located in the pancreatic body/tail, compared to patients with
122 the lesion in the pancreatic head [23]. However, in some cases in the pancreatic
123 body/tail lesion, poorer survival appears to be due to delayed diagnosis with advanced
124 stage, caused by the lack of specific symptoms [23]. In the present case, the small
125 metastatic lesion in the tail of the pancreas was detected in the early stage by FDG-
126 PET/CT, and laparoscopic distal pancreatectomy could be performed with no

127 complication, and resulting in favorable clinical outcome.

128 In conclusion, we present a rare case of a solitary pancreatic lesion as the initial

129 metastasis from osteosarcoma in the proximal fibula. Although pancreatic metastasis

130 from osteosarcoma is extremely unusual, the surgeon responsible for patients with

131 osteosarcoma must be aware of its possibility because pancreatic resection may have a

132 survival benefit for patients. For systemic screening in the management of osteosarcoma

133 patients, FDG-PET/CT should be considered as an additional examination in regular

134 radiographic follow-up of patients with osteosarcoma, especially for early detection of

135 unusual metastases.

136

137 **Figure Legends**

138 Fig. 1: A preoperative radiograph of the right knee.

139 Fig. 2: Preoperative magnetic resonance imaging scans of the right knee.

140 Fig. 3: A postoperative radiograph of the right knee.

141 Fig. 4: Histopathological images of the resected right fibula. Hematoxylin-eosin

142 staining, ×200.

143 Fig. 5: Whole body fluorodeoxyglucose-positron emission tomography with computed

144 tomography showing abnormal uptake in the tail of the pancreas (*white arrow*).

Fig. 6: A late-phase image of abdominal dynamic computed tomography showing a mass with enhancement in the tail of the pancreas (*white arrow*).

Fig. 7: An image from endoscopic ultrasound.

Fig. 8: Histopathological images of the resected pancreas. Hematoxylin-eosin staining, ×200.

151 **References**

152 1. Avcu S, Akdeniz H, Arslan H, Toprak N, Unal O. A case of primary vertebral
153 osteosarcoma metastasizing to pancreas. JOP. 2009 Jul 6;10(4):438-40.
154 2. Aarvold A, Bann S, Giblin V, Wotherspoon A, Mudan SS. Osteosarcoma metastasising
155 to the duodenum and pancreas. J Bone Joint Surg Br. 2007 Apr;89(4):542-4.
156 3. Ogose A, Morita T, Hotta T, Otsuka H, Imaizumi S, Kobayashi H, Hirata Y. Intra-
157 abdominal metastases in musculoskeletal sarcomas. J Orthop Sci. 2000 Sep;5(5):463-9.
158 4. Z'graggen K, Fernández-del Castillo C, Rattner DW, Sigala H, Warshaw AL.
159 Metastases to the pancreas and their surgical extirpation. Arch Surg. 1998
160 Apr;133(4):413-7; discussion 418-9.
161 5. Stankard CE, Karl RC. The treatment of isolated pancreatic metastases from renal cell
162 carcinoma: a surgical review. Am J Gastroenterol. 1992 Nov;87(11):1658-60.
163 6. Zerbi A, Ortolano E, Balzano G, Borri A, Beneduce AA, Di Carlo V. Pancreatic
164 metastasis from renal cell carcinoma: which patients benefit from surgical resection? Ann
165 Surg Oncol. 2008 Apr;15(4):1161-8
166 7. Nakamura E, Shimizu M, Itoh T, Manabe T. Secondary tumors of the pancreas:
167 clinicopathological study of 103 autopsy cases of Japanese patients. Pathol Int. 2001
168 Sep;51(9):686-90.

169 8. Jin P. Wang W, Su H, Sheng JQ. Osteosarcoma metastasizing to pancreas confirmed by
170 endoscopic ultrasound-guided fine-needle aspiration. Endoscopy. 2014;46 Suppl 1
171 UCTN:E109-10.
172 9. Quartuccio N, Fox J, Kuk D, Wexler LH, Baldari S, Cistaro A, Schöder H. Pediatric
173 bone sarcoma: diagnostic performance of ^{18}F-FDG PET/CT versus conventional imaging
174 for initial staging and follow-up. AJR Am J Roentgenol. 2015 Jan;204(1):153-60.
175 10. Quartuccio N, Treglia G, Salsano M, Mattoli MV, Muoio B, Piccardo A, Lopci E,
176 Cistaro A. The role of Fluorine-18-Fluorodeoxyglucose positron emission tomography in
177 staging and restaging of patients with osteosarcoma. Radiol Oncol. 2013 May
178 21;47(2):97-102.
179 11. Liu F, Zhang Q, Zhu D, Li Z, Li J, Wang B, Zhou D, Dong J. Performance of Positron
180 Emission Tomography and Positron Emission Tomography/Computed Tomography
181 Using Fluorine-18-Fluorodeoxyglucose for the Diagnosis, Staging, and Recurrence
182 Assessment of Bone Sarcoma: A Systematic Review and Meta-Analysis. Medicine
183 (Baltimore). 2015 Sep;94(36):e1462.
184 12. Hurley C, McCarville MB, Shulkin BL, Mao S, Wu J, Navid F, Daw NC, Pappo AS,
185 Bishop MW. Comparison of (18) F-FDG-PET-CT and Bone Scintigraphy for Evaluation
186 of Osseous Metastases in Newly Diagnosed and Recurrent Osteosarcoma. Pediatr Blood

187 Cancer. 2016 Aug;63(8):1381-6.

188 13. Shin DS, Shon OJ, Han DS, Choi JH, Chun KA, Cho IH. The clinical efficacy of

189 (18)F-FDG-PET/CT in benign and malignant musculoskeletal tumors. Ann Nucl Med.

190 2008 Aug;22(7):603-9.

191 14. Györke T, Zajic T, Lange A, Schäfer O, Moser E, Makó E, Brink I. Impact of FDG

192 PET for staging of Ewing sarcomas and primitive neuroectodermal tumours. Nucl Med

193 Commun. 2006 Jan;27(1):17-24.

194 15. Sawada S, Suehisa H, Ueno T, Sugimoto R, Yamashita M. Monitoring and

195 management of lung cancer patients following curative-intent treatment: clinical utility

196 of 2-deoxy-2-[fluorine-18]fluoro-d-glucose positron emission tomography/computed

197 tomography. Lung Cancer (Auckl). 2016 Apr 27;7:45-51.

198 16. Krug B, Crott R, Roch I, Lonneux M, Beguin C, Baurain JF, Pirson AS, Vander Borght

199 T. Cost-effectiveness analysis of FDG PET-CT in the management of pulmonary

200 metastases from malignant melanoma. Acta Oncol. 2010;49(2):192-200.

201 17. Annunziata S, Caldarella C, Treglia G. Cost-effectiveness of Fluorine-18-

202 Fluorodeoxyglucose positron emission tomography in tumours other than lung cancer: A

203 systematic review. World J Radiol. 2014 Mar 28;6(3):48-55.

204 18. Rutkowski P, Lugowska I. Follow-up in soft tissue sarcomas. Memo. 2014

205 Jun;7(2):92-6.

206 19. Kager L, Zoubek A, Pötschger U, Kastner U, Flege S, Kempf-Bielack B, Branscheid
207 D, Kotz R, Salzer-Kuntschik M, Winkelmann W, Jundt G, Kabisch H, Reichardt P,
208 Jürgens H, Gadner H, Bielack SS; Cooperative German-Austrian-Swiss Osteosarcoma
209 Study Group. Primary metastatic osteosarcoma: presentation and outcome of patients
210 treated on neoadjuvant Cooperative Osteosarcoma Study Group protocols. J Clin Oncol.
211 2003 May 15;21(10):2011-8.

212 20. Reddy S, Edil BH, Cameron JL, Pawlik TM, Herman JM, Gilson MM, Campbell KA,
213 Schulick RD, Ahuja N, Wolfgang CL. Pancreatic resection of isolated metastases from
214 nonpancreatic primary cancers. Ann Surg Oncol. 2008 Nov;15(11):3199-206.

215 21. Hung JH, Wang SE, Shyr YM, Su CH, Chen TH, Wu CW. Resection for secondary
216 malignancy of the pancreas. Pancreas. 2012 Jan;41(1):121-9.

217 22. Ling Q, Xu X, Ye P, Xie H, Gao F, Hu Q, Liu Z, Wei X, Röder C, Trauzold A, Kalthoff
218 H, Zheng S. The prognostic relevance of primary tumor location in patients undergoing
219 resection for pancreatic ductal adenocarcinoma. Oncotarget. 2017 Feb 28;8(9):15159-
220 15167.

221 23. Ruess DA, Makowiec F, Chikhladze S, Sick O, Riediger H, Hopt UT, Wittel UA. The
222 prognostic influence of intrapancreatic tumor location on survival after resection of

223 pancreatic ductal adenocarcinoma. BMC Surg. 2015 Nov 28;15:123.

Fig. 1

Fig. 2

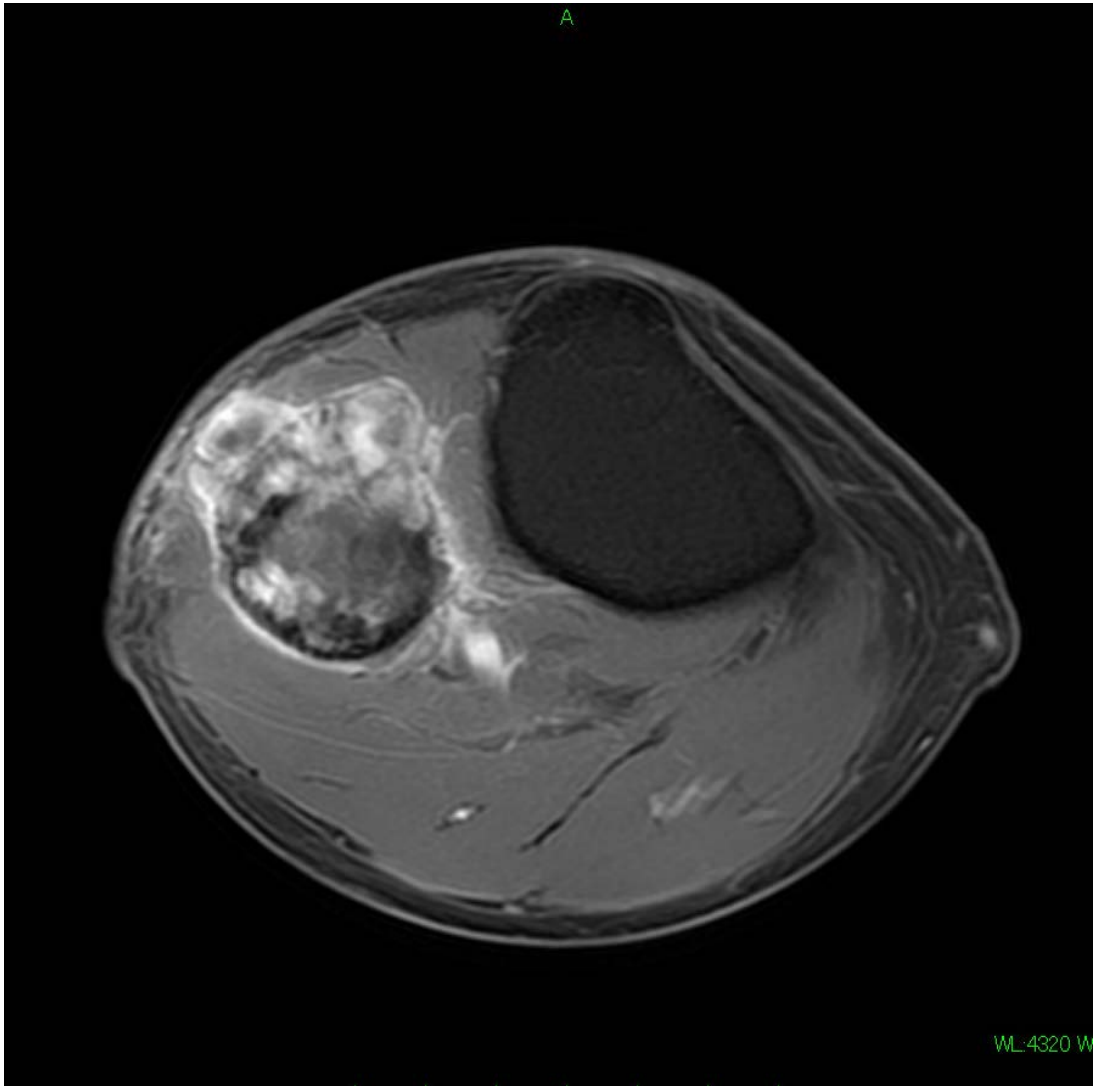

Fig. 3

Fig. 4

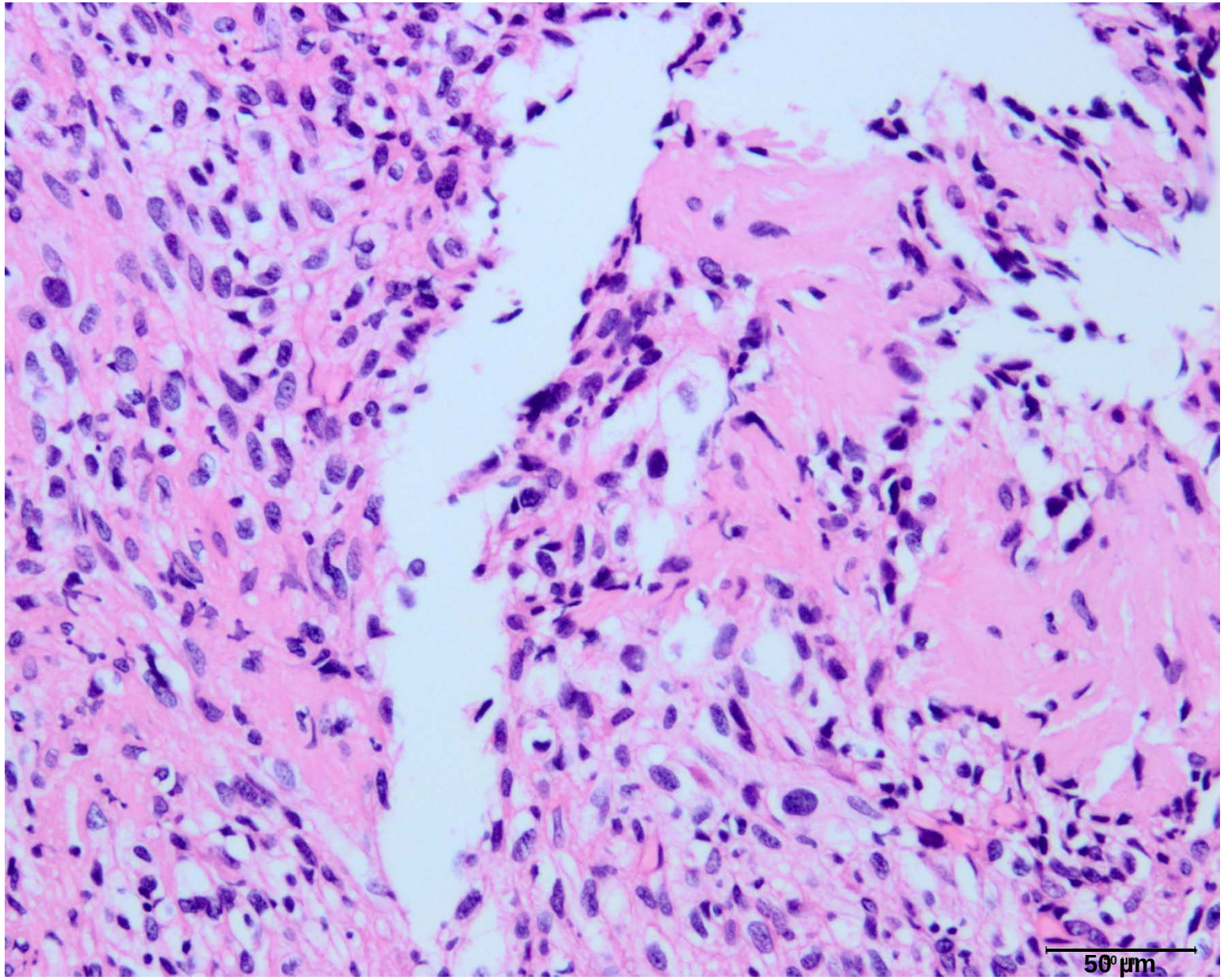

Fig. 5

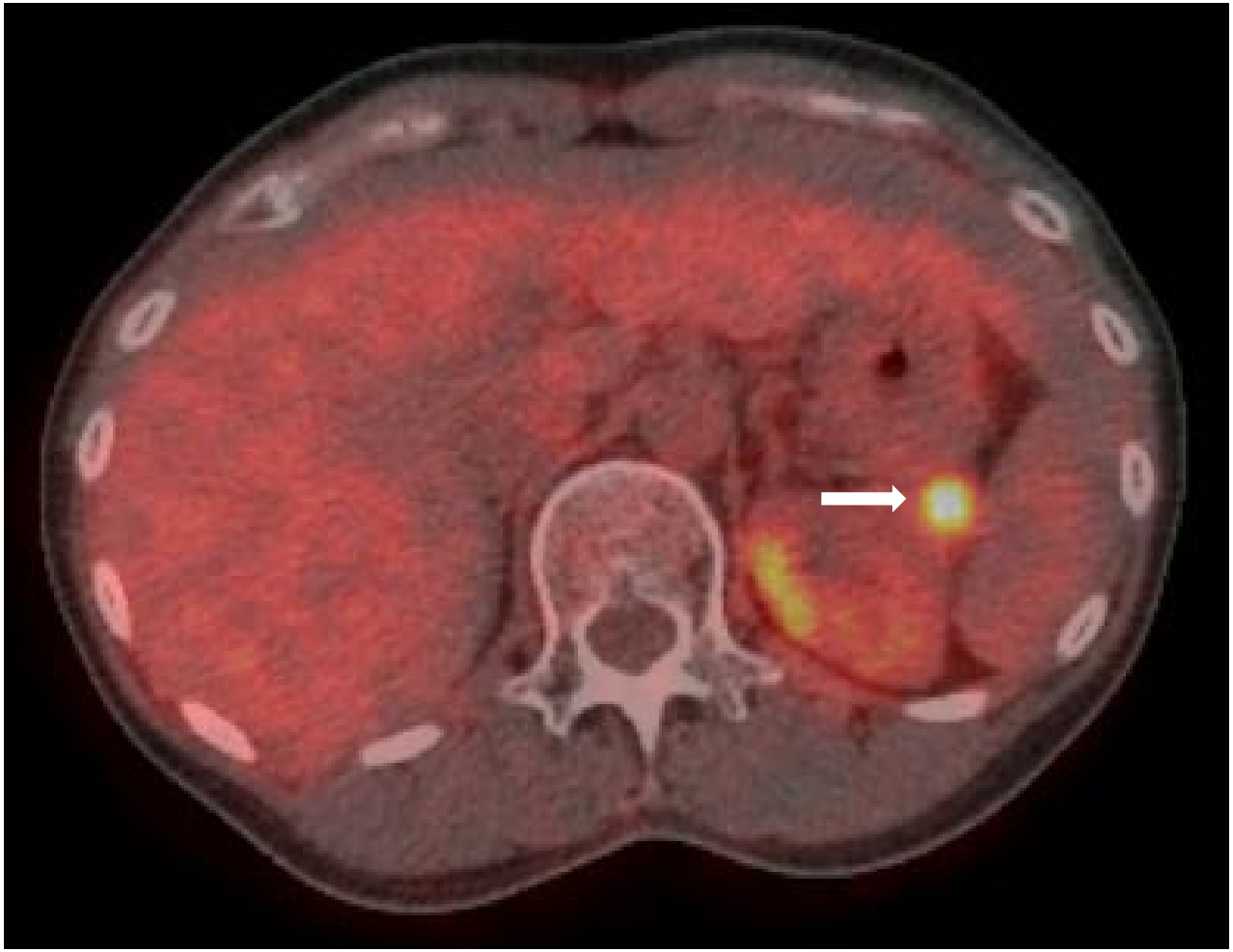

Fig. 6

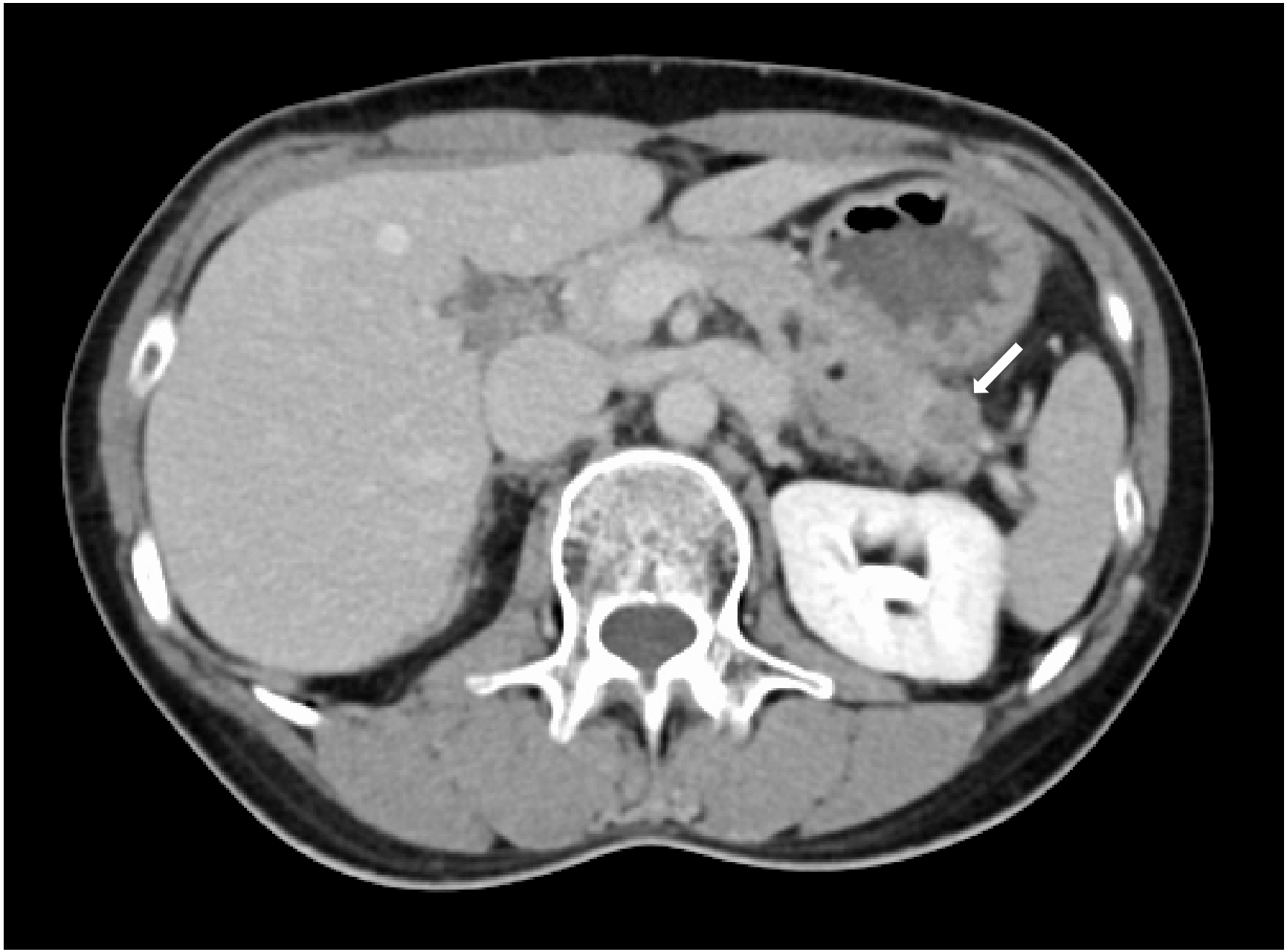

Fig. 7
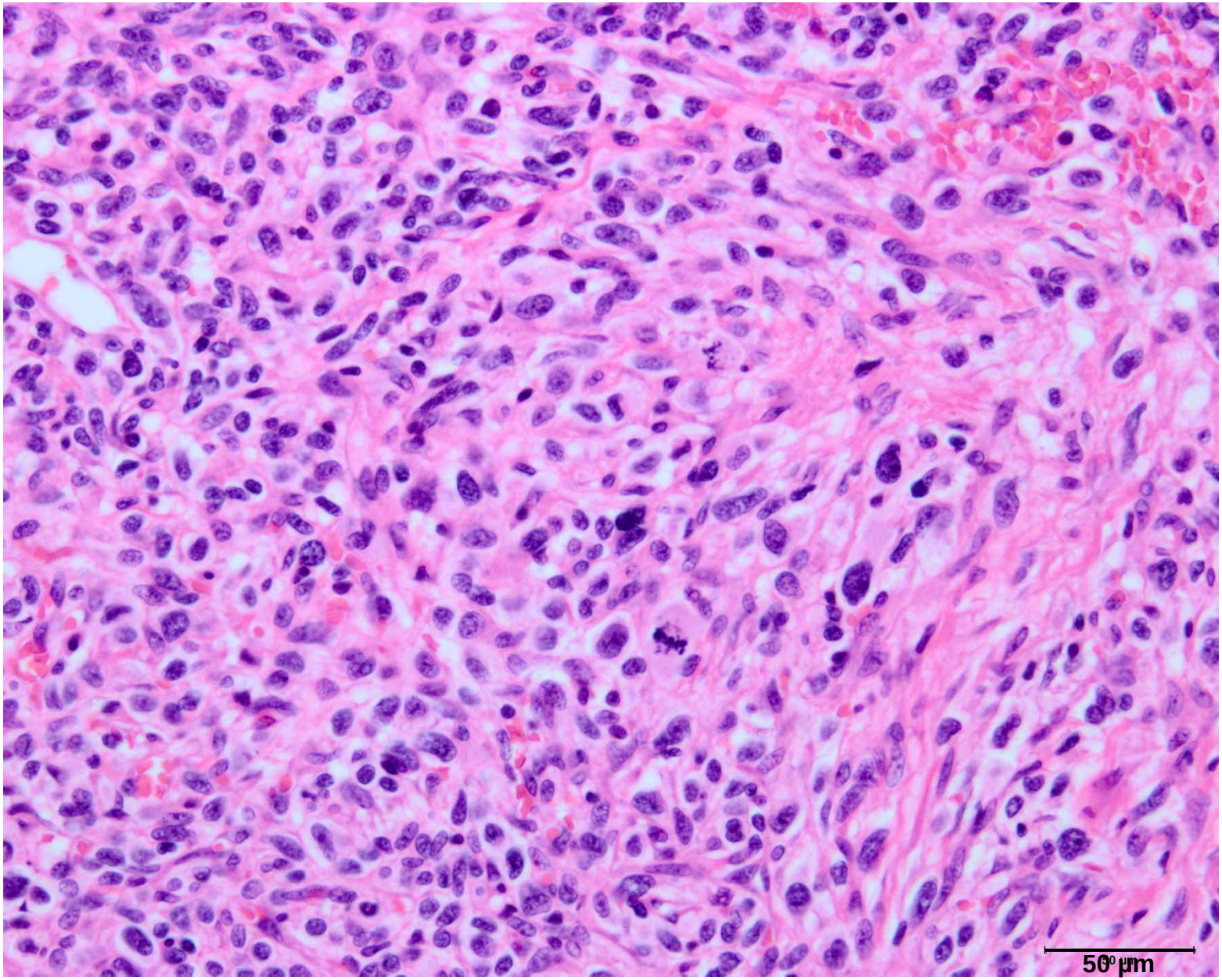
Fig. 8