Kobe University Repository : Kernel

PDF issue: 2025-12-04

Ultrasound Frequency-Based Monitoring for Bone Healing

Kumabe, Yohei ; Oe, Keisuke ; Morimoto, Masakazu ; Yagi, Naomi ; Fukui, Tomoaki ; Kuroda, Ryosuke ; Hata, Yutaka ; Niikura, Takahiro

(Citation)
Tissue Engineering Part C: Methods,27(6):349-356

(Issue Date)
2021-06-01

(Resource Type)
journal article

(Version)
Accepted Manuscript

(Rights)
© Mary Ann Liebert, Inc. Final publication is available from Mary Ann Liebert, Inc., publishers http://dx.doi.org/10.1089/ten.tec.2021.0020.

(URL)
https://hdl.handle.net/20.500.14094/90008432

Title: Ultrasound Frequency-Based Monitoring for Bone Healing

Short running title: Ultrasound Frequency Monitoring for Bone Healing

Yohei Kumabe MD[1] (Yoheikumabe@gmail.com)

Keisuke Oe MD[1] (keisuke5091@gmail.com)

Masakazu Morimoto[2] (morimoto@eng.u-hyogo.ac.jp)

Naomi Yagi[3] (naomi@gm.himeji-du.ac.jp)

Tomoaki Fukui MD[1] (tomoakifukui@yahoo.co.jp)

Ryosuke Kuroda MD[1] (kurodar@med.kobe-u.ac.jp)

Yutaka Hata[4] (hata@sim.u-hyogo.ac.jp)

Takahiro Niikura MD[1*] (niikura@tj8.so-net.ne.jp)

[1] Kobe University Graduate School of Medicine Department of Orthopaedic Surgery (+81-78-382-5985)

[2] University of Hyogo, Graduate School of Engineering (81+79-267-4911)

[3] Himeji Dokkyo University, Faculty of Health Care Science, Department of Medical Engineering (＋81-79-223-2211)

[4] University of Hyogo, Graduate school of Simulation Studies (+81-78-303-1901)

Keywords: Ultrasound Frequency-Based Method, Bone Healing, Monitoring

* Corresponding author

Abstract

Correct assessment of the bone healing process is required for the management of limb immobilization during the treatment of bone injuries, including fractures and defects. Although the monitoring of bone healing using ultrasound poses several advantages regarding cost and ionizing radiation exposure compared with other dominant imaging methods, such as radiography and CT, traditional ultrasound B-mode imaging lacks reliability and objectivity. However, the body structures can be quantitatively observed by ultrasound frequency-based methods, and therefore, the disadvantages of B-mode imaging can be overcome. In this study, we created a femoral bone hole model of a rat and observed the bone healing process using the quantitative ultrasound method and micro-CT, which provides a reliable assessment of the tissue microstructure of the bone. The current study analyzed the correlation between these two assessments. The results revealed that the quantitative ultrasound measurements correlated with the CT measurements for rat bone healing. This ultrasound frequency-based method could have the potential to serve as a novel modality for quantitative monitoring of bone healing with the advantages of being less invasive and easily accessible.

Impact statement

Bone healing monitoring with ultrasound is advantageous as it is less invasive and easily accessible; however, the traditional B-mode method lacks reliability and objectivity. This study demonstrated that the proposed ultrasound frequency-based monitoring method can quantitatively observe bone healing and strongly correlates with the CT measurements for rat bone healing. This method has the potential to become a reliable modality for monitoring bone healing.

Introduction

Bone injuries have to be stabilized with a brace or casting, or through external fixation, during treatment; moreover, in the case of internal fixation, injured limbs are subjected to limited joint motion and weight bearing until they achieve union.[1] Although limb immobilization is essential for treatment, prolonged immobilization period negatively effects joints, muscles, and bones by reducing the range of joint motion, creating joint contractures, and inducing muscle atrophy and bone loss, thus increasing the gross individual, social, and economic costs related to the treatment of bone injuries.[2-4] Therefore, the duration of treated limb immobilization must be minimized to reduce the stated losses. Moreover, the process of bone healing requires correct assessment for the management of limb immobilization. In addition to patients' complaints and physical examinations, radiography and computed tomography (CT) examinations enable doctors to appropriately judge the healing status of the bones. Although radiography and CT are dominant modalities of imaging for monitoring bone healing, their high cost and ionizing radiation exposure cannot be ignored.[5, 6]

Ultrasound assessment has emerged as a promising modality for monitoring bone healing[7] and presents several advantages, such as providing real-time images and being portable for bedside procedures, unlike other dominant imaging methods, such as radiography and CT. In addition, it is substantially inexpensive compared to other imaging modalities and does not use harmful ionizing radiation.[8] Ultrasound has long been used as a tool to detect the presence of fractures in situations where radiographic findings are inconsistent with clinical signs, such as occult fractures and stress fractures.[9] Since the 1990s, ultrasound has been tested as a tool for monitoring callus progression and detecting union. However, it has not been widely used for this purpose, which is possibly due to the main method of producing the ultrasound images—the B-mode, a conventional

ultrasound imaging method that provides a morphologic assessment of the body for clinical use.[10] As a part of the returned echo signal data is processed, two-dimensional images are created on a display composed of bright dots. Doctors can obtain information only based on the location and brightness of the dots from images that do not reflect the histological features of the structure in the body, such as the extent of progression of bony callus calcification. Consequently, such limited and subjective information do not assist in the accurate judgment of healing bones. Therefore, B-mode imaging cannot be deemed as a reliable and suitable method for monitoring bone healing.

In recent years, quantitative ultrasound methods have been developed to assess tissue microstructure that can increase the specificity of image findings.[11-14] Quantitative ultrasound involves the extraction of a set of possible parameters from the ultrasound radiofrequency signals after its propagation through the biological tissue, such as the speed of sound, broadband ultrasound attenuation coefficient, backscattering coefficient, and mean scatterer spacing.[15] Successful clinical and pre-clinical applications that demonstrate the ability of quantitative ultrasound in improving medical diagnostics include characterization of the myocardium during the cardiac cycle,[16] cancer detection, classification of solid tumors and lymph nodes,[17] and detection and quantification of fatty liver diseases.[18] Thus, the quantitative ultrasound observation of bone healing is advantageous over the conventional B-mode imaging method in terms of reliability and objectivity. In addition, it has the potential to emerge as a useful modality for monitoring the bone healing process. However, only few studies have analyzed the effectiveness of this method on bone healing.[19, 20] Therefore, we hypothesized that the bone healing process can be monitored quantitatively with ultrasound radiofrequency signal observation. The purpose of this study was to observe a bone healing process in the animal model through quantitative ultrasound and micro-CT, which serve as a reliable and quantitative assessment of the bone tissue

microstructure, and to analyze the correlation between these methods. Thus, we employed a rat bone hole model, which demonstrates a standardized basic bone healing process that is commonly observed in several types of bone injuries.

Methods

Twelve male Sprague–Dawley rats were used in this study. A transcortical 2-mm non-critical drilled bone hole defect was created bilaterally in the middle of the femur diaphysis based on Keibl's method [Fig. 1].[21] These rats were randomly separated into three groups of 2 weeks, 3 weeks, and 4 weeks from the time of surgery. The rats' bilateral femurs were harvested at each time point. Ultrasound measurement, micro-CT measurement, frequency analysis, and histological assessment were performed on them. Details of each examination are presented below.

Experiment

Experimental Design

Animal model

All protocols of this study were approved by the Animal Ethics Committee of Kobe University. This study used 12 male Sprague–Dawley rats (Japan SLC Inc., Hamamatsu, Japan) aged 12 weeks and weighing 413.0–423.8 g. The femoral bone hole model was created based on Keibl's method [Fig. 1]. The rats were anesthetized with intraperitoneal injection of medetomidine (0.15 mg/kg), midazolam (2 mg/kg), and butorphanol (2.5 mg/kg). Their hair was shaved, and a longitudinal skin incision was made on the lateral aspect of both femurs. A transcortical 2-mm non-critical drilled bone hole defect was created under sterile conditions bilaterally in the middle of the femur diaphysis. Normal saline solution was dripped onto the drilling site to prevent heating during drilling. After creating a bone hole, the skin was closed with a nylon suture. Benzylpenicillin potassium (100 thousand units/kg) was injected intramuscularly as an antibiotic agent post-operation, and the hind legs were loaded immediately after surgery without any movement restriction. All rats were housed separately in standard cages with temperature control (20–23 °C),

and food and water were provided ad libitum. These rats were randomly separated into three groups of 2 weeks, 3 weeks, and 4 weeks from the time of surgery, after which the animals were euthanized with an overdose intraperitoneal injection of pentobarbital sodium. After euthanization, the rats' bilateral femurs were harvested and stored in 4% formaldehyde solution for analysis. Three legs from the 2-weeks group, two legs from the 3-weeks group, and one leg from the 4-weeks group were excluded from analysis because of infection, fracture, or death.

Ultrasound measurement

The ultrasound data acquisition system was used in this study, where an ultrasound single probe was employed with broadband ultrasound wave of a center frequency of 5.0 MHz and point focus of 50 mm (B5K10IPF50) [Fig. 2].[22] The ultrasound pulser/receiver transmitted signals for an ultrasound probe that emitted ultrasound waves. Each of them reflected the ultrasound waves, and the pulser/receiver detected and input them into an analog/digital (A/D) converter, PicoScope 5242A (Pico Technology Limited, Cambridgeshire, UK). The ultrasound waveform data were sent to a personal computer through the A/D converter with a sampling interval of 1 ns. The Fourier transform was performed by applying a Hamming window to every echo signal in MATLAB R2020a (MathWorks, Natick, MA, USA). The ultrasound probes used in this study exhibited a frequency of 5.0 MHz and wavelength of 300 μm in a medium with a wave speed of 1500 m/s (e.g., water at 25 °C). The experiment was performed using the harvested rat bones discussed earlier. The experimental results were obtained by evaluating the reduction in frequency and magnitude of the reflected waves for confirming that the reflected waves emanated from the hole.

Micro-CT measurement

The new bone formation on the harvested femurs of each group was quantified by performing micro-CT (R_mCT2 FX, Rigaku Corp, Tokyo, Japan). The region of interest was set at 10 mm including the drilled hole. In addition, the mean CT values at the hole and bone surface were calculated.[23]

Frequency analysis

The transfer function G[ω] uses the cross spectrum of the input and received waves. X[ω] and Y[ω] are the input and output frequency responses, respectively, and $\overline{X}[\omega]$ is the conjugate complex number of X[ω]. In our experience, X[ω] expresses a frequency response from the flat surface of a silicon, and Y[ω] expresses each frequency response from the rat bone.[24]

The transfer function was calculated using Equation (1).

$$|G[\omega]| = |\overline{X}[\omega]Y[\omega]|/(X[\omega]\overline{X}[\omega]) \qquad (1)$$

The correlation between the frequency components of the two signals was high when the cross spectrum exhibited a large value at a certain frequency. To estimate frequency behavior, the spectral center of gravity (COG) was used as a measure for how high the frequencies in a spectrum were on average [Fig. 3]. The current study was designed to evidently establish that the degree of bone fracture healing correlated with the frequency.

Histological assessment

A histological assessment of the bone healing process was performed on the drilled hole. The harvested femurs were fixed in 4% paraformaldehyde at room temperature (21–26 °C) for 24 h. Thereafter, the femurs were decalcified at room temperature with a decalcifying solution (composition: 10% formic acid and 10% formalin in 1:1 ratio) and embedded in paraffin wax.

Lastly, the femurs were processed to produce 5-μm-thick sagittal sections using a microtome. The sections were deparaffinized in xylene, dehydrated with graded alcohols, and stained with safranin-O and fast green to determine the detailed histological structure.[25]

Statistical analysis

The parameters among the 2-, 3-, and 4-weeks groups were compared using one-way factorial analysis of variance (ANOVA), followed by post hoc analyses using the Tukey–Kramer test. All data are presented as the mean ± standard deviation. The P values were two-sided, and $P < 0.05$ was considered to indicate a statistically significant difference. The statistical analyses were performed using JMP Pro 14.2 (SAS Institute Inc., Cary, NC, USA).

Experimental Results

Correlation between ultrasound measurement and bone mineral density

The relationship between the mean CT values from micro-CT measurements of the hole surface and the ultrasound frequencies from the proposed system is depicted in Fig. 4, where the samples in each group are plotted with different markers. As observed, a strong positive correlation existed between the ultrasound measurements and the mean CT value with a correlation coefficient of 0.719.

Frequency analysis

In this subsection, all the data from the 2-, 3-, and 4-weeks groups were analyzed, and the frequencies of these three groups are listed in Table 1. The frequencies were significantly higher in the 4-weeks group than those in the 3- and 2-weeks group (4-weeks group: 4.44 ± 0.33 MHz, n =

7; 3-weeks group: 4.06 ± 0.16 MHz, $n = 6$, $p < 0.05$; 2-weeks group: 3.82 ± 0.25 MHz, $n = 5$, $p < 0.005$) [Fig. 5]. There was no significant difference between the femurs of the 2- and 3-weeks groups.

In addition, the 4-weeks group exhibited a higher mean of frequencies than the 2- and 3-weeks group, and it produced a result that met the criterion for fracture healing degree. Moreover, the waveforms were analyzed to accurately determine the frequency difference of the response. The single regression analysis confirmed a significant association between the frequency and CT values. Furthermore, these results provided data that are useful for demonstrating our hypothesis.

Histological assessment

After 2 weeks, the newly formed bone tissue comprised a network of woven bone in the created bone hole space. After 3 weeks, the amount of bone tissue in the cortical region increased from that at 2 weeks, and more lamellar bone was present. Moreover, the bone tissue in the marrow space had mostly disappeared. The cortical bone was widely restored at 4 weeks and most of the bone tissue in the marrow space was resorbed. Furthermore, no cartilage tissue was observed in the hole during the healing process [Fig. 6].

Discussion

In the current study, a rat femur-bone hole model was created, and its healing process was observed under ultrasound and micro-CT to investigate the correlation between these two assessment results. Consequently, a strong correlation was observed between the ultrasound frequency value and the mean CT value.

The healing of the bone hole was observed histologically. Initially, the hole was filled with newly formed woven bone tissue, which was thereafter replaced by the lamellar bone in the cortical area that disappeared in the marrow area. The cartilage tissue stained with safranin-O was hardly observed at any instant. Thus, only the intramembranous ossification was observed in our animal model. Generally, bone healing with firmly fixation shows only intramembranous ossification, and both intramembranous ossification and endochondral ossification are observed when the fixations are not firm. As bone drill holes have no instability and are similar to firmly fixed fractures, endochondral ossification was not observed in the current study. These findings are consistent with those of previous reports.[26-28]

Certain studies have investigated the possibility of monitoring fracture healing using ultrasound. Nicholson et al. observed the bone healing process of clavicle fractures with ultrasound under clinical conditions and reported appearance changes of hematoma, callus, and calcification on B-mode images. Their results demonstrated that the hematoma appeared as a hypoechogenic (dark) area on the ultrasound image after a fracture. Over time, this region transitions from an echoic (totally dark) to increasingly hyperechogenic as calcification occurs, eventually producing a bright boundary line similar to that of a cortical bone with a clear acoustic shadow.[9] The study reported that echogenicity alterations occur prior to the dense mineralization associated with mature bridging callus on radiographs, which could enable earlier union detection and later display high

sensitivity and specificity for detecting bone union by B-mode imaging at 12 weeks. Although their method can be useful for monitoring bone healing in clinical cases, they assessed the body structure simply based on the brightness of dots on the display, such as “hypoechogenic,” “echogenic,” “dark,” or “totally dark.” Thus, this method cannot be deemed with sufficient objectivity and reliability to be used widely.[29] Similarly, Glinkowski et al. quantitatively monitored human fracture healing of long bones with transmitted ultrasound.[30] They placed a transducer emitter and a receiver on each side of the fractured area and measured the propagation time of ultrasound between them. As the ultrasound transmission velocity increased with time after injury, they concluded that ultrasound measurement of bone union may support or modify clinical decisions. This method would be adequately accurate for tibia, radius, or ulna fractures, but the monitoring of small bone and metaphyseal and epiphyseal fractures would not be suitable with this method. Moreover, transmitted ultrasound measurement of fractures could be applied only for shaft fractures of long bones covered with a thin layer of soft tissues. The difficulty of the assessment is in the definition of protocols as well as its reproducibility. On the contrary, the current study investigated the reflected backscattered ultrasound. In addition, broadband ultrasound single-probe testing reveals an inverse relationship between the frequency and diameter of the columnar soft matter,[31] which suggests that a lower frequency of the reflected backscattered waveform was observed for the softer lines. Moreover, the cross-spectrum analysis used herein is a standard method for determining the relationship between two time-series as a function of frequency. As compared with the transmitted ultrasound by cross-spectrum analysis, this method could be applied to a wider range of fracture types including small bone and metaphyseal and epiphyseal fractures, and doctors are more familiar with this procedure for clinical use. Therefore,

the reflected backscattered signal assessment was considered to be the preferred method in terms of the use of ultrasound for fracture monitoring.

In the current study, we used micro-CT measurements as a comparison to ultrasound signals. CT provides quantitative and three-dimensional measurements of the structure and mineralization of the fracture callus, and these measurements could potentially be related to callus stiffness and strength, which are the most essential factors when fractured bones are judged for practical healing. Morgan et al. compared several models of fracture healing in mice to determine the factors observed with micro-CT that correlated with fracture strength. Fractured femora under various conditions were selected to represent a wide range of healing. Furthermore, mechanical testing revealed that torsional strength and rigidity correlated with callus mineral density as well as the amount of callus that was mineralized.[32] Moreover, CT is one of the most reliable modalities for monitoring callus tissue during the bone healing process and meets the requirements for comparison with ultrasound signals in the current research.

The present study has certain limitations. First, we employed a bone hole model in the current study, which does not represent all kinds of bone injuries. Although there are several patterns of bone injuries, they have a similar pathology and healing manner.[26, 33, 34] It is hard to establish a single animal model that standardizes all kinds of bone injuries; hence, we believe that the animal model employed in this study is one of the best choices to observe basic bone healing process. Only the intramembranous ossification could be observed in our animal model; therefore, models that also show endochondral ossification, such as a fracture model with relatively loose fixation like intramedullary nailing, are required for a more comprehensive observation. In addition, there are differences between rats and humans, including body size, anatomic features, and biological process in bone healing. Second, the ultrasound assessment of the bone hole was performed after

the removal of soft tissue to focus on bone and callus tissue. However, the soft tissue cannot be ignored in clinical cases. In fact, most of the energy of ultrasound was transmitted through variable amounts of soft tissue overlying the bone, which may lead to fluctuations in measurements.[35] Observations made without soft tissue removal or in a living state would highlight the influence of soft tissue on ultrasound measurements for analysis. Third, it is highly possible that some metallic implants used for fixation, such as plates, nails, and screws, are present near the bone fracture area in actual clinical situations. Their influence on ultrasound measurements is inevitable in such cases. This problem of artifacts from implanted devices is common in ultrasound observations, as well as CT and MRI observations. Thus, it is crucial to recognize these artifacts and avoid a misinterpretation of observations. Although the only way to eliminate the artifacts is to remove implants, studies were repeatedly conducted by combining ultrasound devices, data processing, and machine learning to reduce the influence of the artifacts.[36-39] Fourth, in a clinical situation, tissues at various healing stages and intact cortex exist intricately in an injured bone. We could observe a tissue healing process at a small point and distinguish it from the surrounding cortical bone through observations and data processing in this study; however, the same process is required at every point in the area to be observed in actual patients. Addressing this problem to make the approach useful for doctors in clinical practice would require efficient observations, data integration, and data presentation. Thus, it is difficult to directly adopt the results of this study to the clinical situation. Therefore, further investigations are necessary to make progress based on the current study.

In conclusion, the ultrasound measurements correlated with the CT measurements on the rat bone healing observation. Despite its limitations, this method has the potential to garner attention as a novel modality for quantitatively monitoring bone healing as it is less invasive and more easily

accessible than commonly used radio-imaging modalities. However, further studies with closer settings on actual patients and translational studies from animal to human are required before the proposed ultrasound monitoring method can be used in future clinical practice.

Disclosure Statement

No competing financial interests exist.

Funding Information

There was no funding to report with this research.

References

1. Buckley RE, Moran CG, Apivatthakakul T. *AO Principles of Fracture Management: Vol. 1: Principles, Vol. 2: Specific Fractures*. Thieme Medical Publishers; 2017.

2. Uhthoff HK, Jaworski ZF. Bone loss in response to long-term immobilisation. J Bone Joint Surg Br 1978;60-B:420-429.

3. Dittmer DK,Teasell R. Complications of immobilization and bed rest. Part 1: Musculoskeletal and cardiovascular complications. Can Fam Physician 1993;39:1427-1435.

4. Born CT, Gil JA, Goodman AD. Joint contractures resulting from prolonged immobilization: Etiology, prevention, and management. J Am Acad Orthop Surg 2017;25:110-116.

5. Axelrad TW, Einhorn TA. Use of clinical assessment tools in the evaluation of fracture healing. Injury 2011;42:301-305.

6. Schwarzenberg P, Darwiche S, Yoon RS, Dailey HL. Imaging modalities to assess fracture healing. Curr Osteoporos Rep 2020;18:169-179.

7. Li H, Le LH, Sacchi MD, Lou EH. Ultrasound imaging of long bone fractures and healing with the split-step Fourier imaging method. Ultrasound Med Biol 2013;39:1482-1490.

8. Morshed S. Current options for determining fracture union. Adv Med 2014;2014:708574.

9. Nicholson JA, Tsang STJ, MacGillivray TJ, Perks F, Simpson A. What is the role of ultrasound in fracture management?: Diagnosis and therapeutic potential for fractures, delayed unions, and fracture-related infection. Bone Joint Res 2019;8:304-312.

10. Szabo TL. *Diagnostic Ultrasound Imaging: Inside Out*. Academic Press; 2004.

11. Madaras EI, Barzilai B, Perez JE, Sobel BE, Miller JG. Changes in myocardial backscatter throughout the cardiac cycle. Ultrason Imaging 1983;5:229-239.

12. Oelze ML, Zachary JF, O'Brien WD, Jr. Parametric imaging of rat mammary tumors in vivo

for the purposes of tissue characterization. J Ultrasound Med 2002;21:1201-1210.

13. Feleppa EJ, Porter CR, Ketterling J, et al. Recent developments in tissue-type imaging (TTI) for planning and monitoring treatment of prostate cancer. Ultrason Imaging 2004;26:163-172.

14. Saegusa-Beecroft E, Machi J, Mamou J, et al. Three-dimensional quantitative ultrasound for detecting lymph node metastases. J Surg Res 2013;183:258-269.

15. Oelze ML, Mamou J. Review of quantitative ultrasound: Envelope statistics and backscatter coefficient imaging and contributions to diagnostic ultrasound. IEEE Trans Ultrason Ferroelectr Freq Control 2016;63:336-351.

16. Mondillo S, Galderisi M, Mele D, et al. Speckle-tracking echocardiography: a new technique for assessing myocardial function. J Ultrasound Med 2011;30:71-83.

17. Feleppa EJ, Mamou J, Porter CR, Machi J. Quantitative ultrasound in cancer imaging. Semin Oncol 2011;38:136-150.

18. Ozturk A, Grajo JR, Gee MS, et al. Quantitative hepatic fat quantification in non-alcoholic fatty liver disease using ultrasound-based techniques: A review of literature and their diagnostic performance. Ultrasound Med Biol 2018;44:2461-2475.

19. Tang S, Shajudeen P, Tasciotti E, Righetti R. Identification of ultrasound imaging markers to quantify long bone regeneration in a segmental tibial defect sheep model in vivo. Sci Rep 2020;10:13646.

20. Njeh CF, Kearton JR, Hans D, Boivin CM. The use of quantitative ultrasound to monitor fracture healing: A feasibility study using phantoms. Med Eng Phy 1998;20:781-786.

21. Keibl C, Fugl A, Zanoni G, et al. Human adipose derived stem cells reduce callus volume upon BMP-2 administration in bone regeneration. Injury 2011;42:814-820.

22. Hoffmeister BK, Johnson DP, Janeski JA, et al. Ultrasonic characterization of human

cancellous bone in vitro using three different apparent backscatter parameters in the frequency range 0.6-15.0 mhz. IEEE Trans Ultrason Ferroelectr Freq Control 2008;55:1442-1452.

23. Ruegsegger P, Koller B, Muller R. A microtomographic system for the nondestructive evaluation of bone architecture. Calcif Tissue Int 1996;58:24-29.

24. Li B, Xu F, Liu C, et al. Effect of spectral estimation on ultrasonic backscatter parameters in measurements of cancellous bones. IEEE Access 2019;7:83034-83045.

25. Gerstenfeld LC, Wronski TJ, Hollinger JO, Einhorn TA. Application of histomorphometric methods to the study of bone repair. J Bone Miner Res 2005;20:1715-1722.

26. Monfoulet L, Rabier B, Chassande O, Fricain JC. Drilled hole defects in mouse femur as models of intramembranous cortical and cancellous bone regeneration. Calcif Tissue Int 2010;86:72-81.

27. He YX, Zhang G, Pan XH, et al. Impaired bone healing pattern in mice with ovariectomy-induced osteoporosis: A drill-hole defect model. Bone 2011;48:1388-1400.

28. Zhang H, Shi X, Wang L, et al. Intramembranous ossification and endochondral ossification are impaired differently between glucocorticoid-induced osteoporosis and estrogen deficiency-induced osteoporosis. Sci Rep 2018;8:3867.

29. Nicholson JA, Oliver WM, LizHang J, et al. Sonographic bridging callus: An early predictor of fracture union. Injury 2019;50:2196-2202.

30. Glinkowski W, Gorecki A. Clinical experiences with ultrasonometric measurement of fracture healing. Technol Health Care 2006;14:321-333.

31. Hata Y, Takashima Y, Tsukuda K, Kikuchi S, Ishikawa T. Ultrasonic-frequency-based visualization of columnar soft matter beyond wavelength limitations. IEEE Trans. Syst Man Cybern: Syst 2016;48:224-231.

32. Morgan EF, Mason ZD, Chien KB, et al. Micro-computed tomography assessment of fracture healing: Relationships among callus structure, composition, and mechanical function. Bone 2009;44:335-344.

33. An Y, Friedman RJ, Parent T, Draughn RA. Production of a standard closed fracture in the rat tibia. J Orthop Trauma 1994;8:111-115.

34. Mills LA, Simpson AH. In vivo models of bone repair. J Bone Joint Surg Br 2012;94:865-874.

35. Markel MD, Chao E. Noninvasive monitoring techniques for quantitative description of callus mineral content and mechanical properties. Clin Orthop Related Res 1993:37-45.

36. Liu S, Wang Y, Yang X, Lei B, Liu L, Li SX, Ni D, Wang T. Deep learning in medical ultrasound analysis: a review. Engineering 2019;5:261-275.

37. Feldman MK, Katyal S, Blackwood MS. US artifacts. Radiographics 2009;29:1179-1189.

38. Wu WT, Chang KV, Hsu YC, Hsu PC, Ricci V, Ozcakar L. Artifacts in Musculoskeletal Ultrasonography: From Physics to Clinics. Diagnostics (Basel) 2020;10.

39. Quien MM, Saric M. Ultrasound imaging artifacts: How to recognize them and how to avoid them. Echocardiography 2018;35:1388-1401.

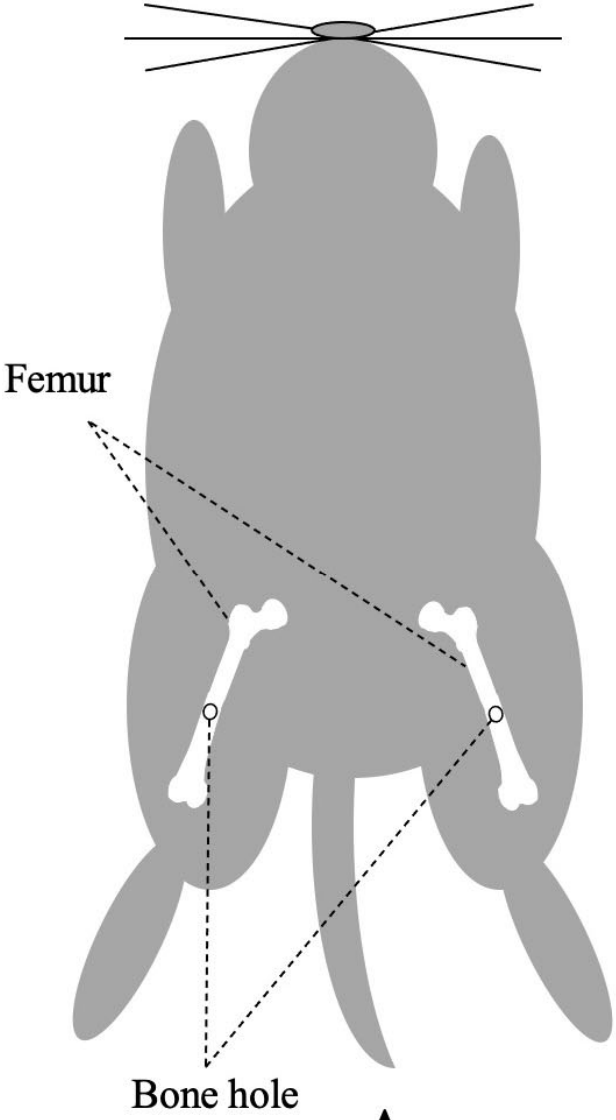

A

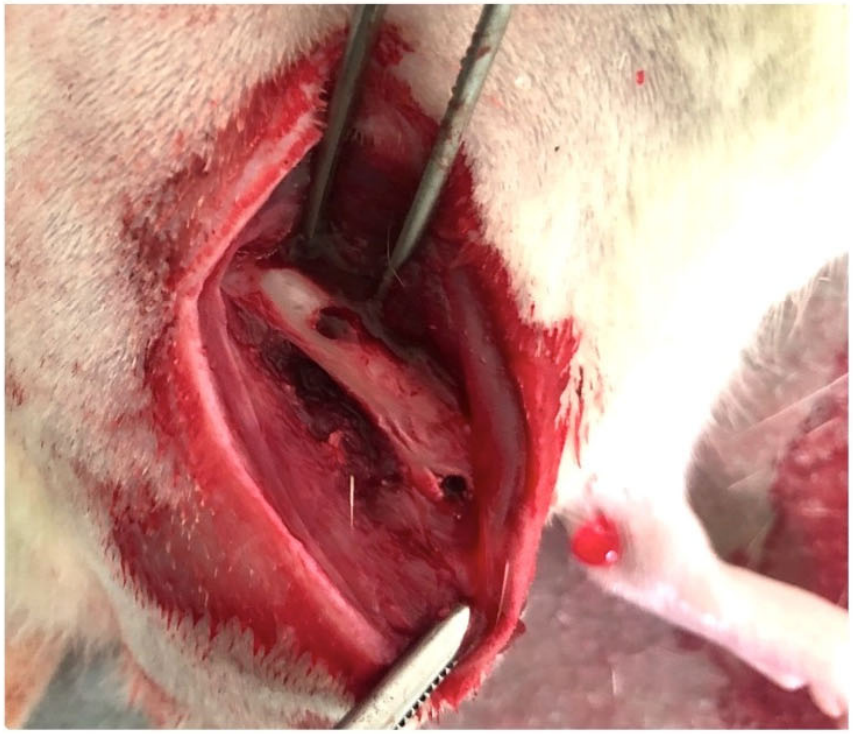

B

Figure 1

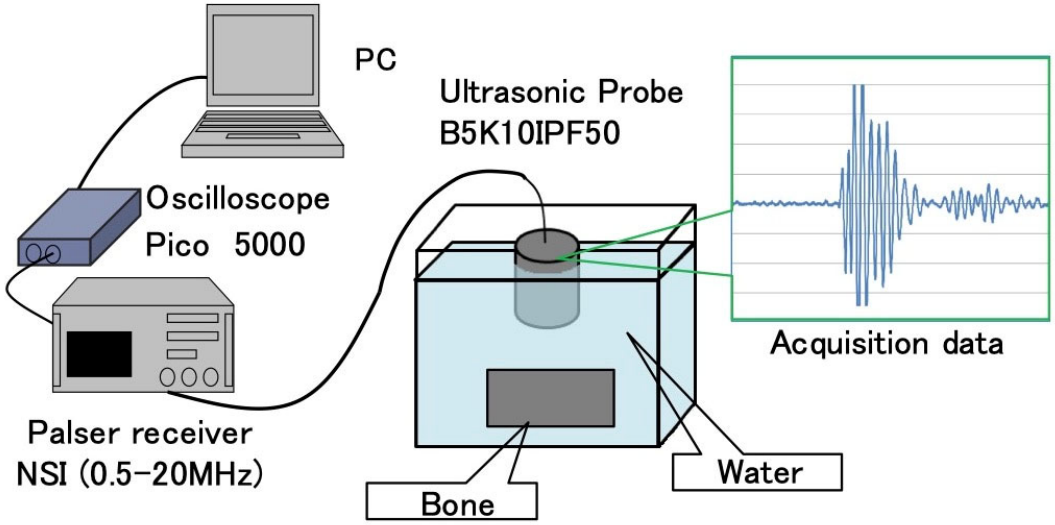
PC
Ultrasonic Probe
B5K10IPF50
Oscilloscope
Pico 5000
Acquisition data
Palser receiver
NSI (0.5-20MHz)
Water
Bone

A

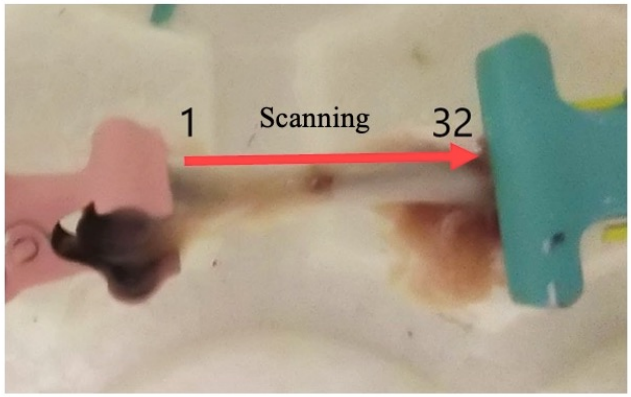
1
Scanning
32

Figure 2

B

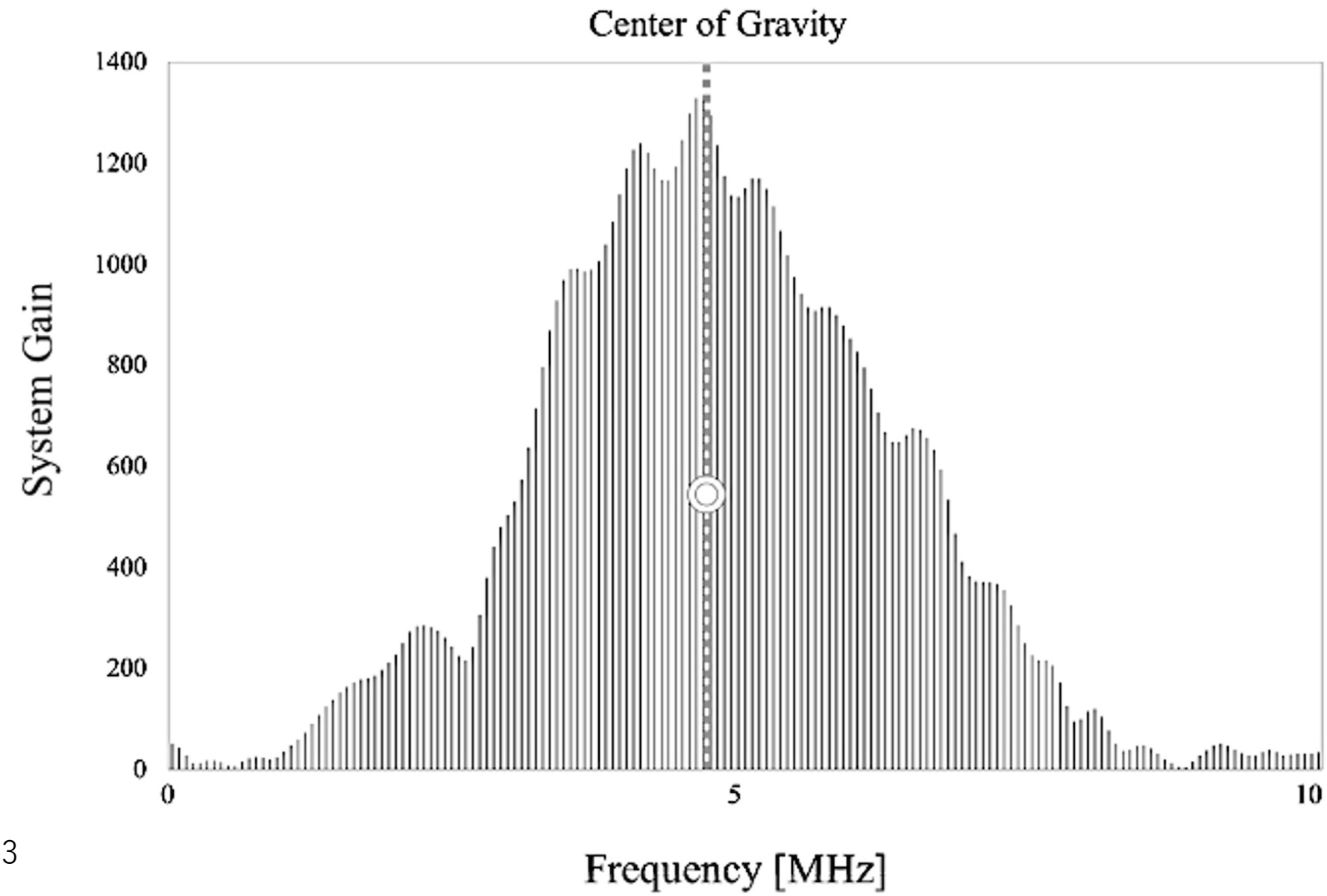
Center of Gravity
1400
1200
1000
800
600
400
200
0
System Gain
0
5
10
Frequency [MHz]

Figure 3

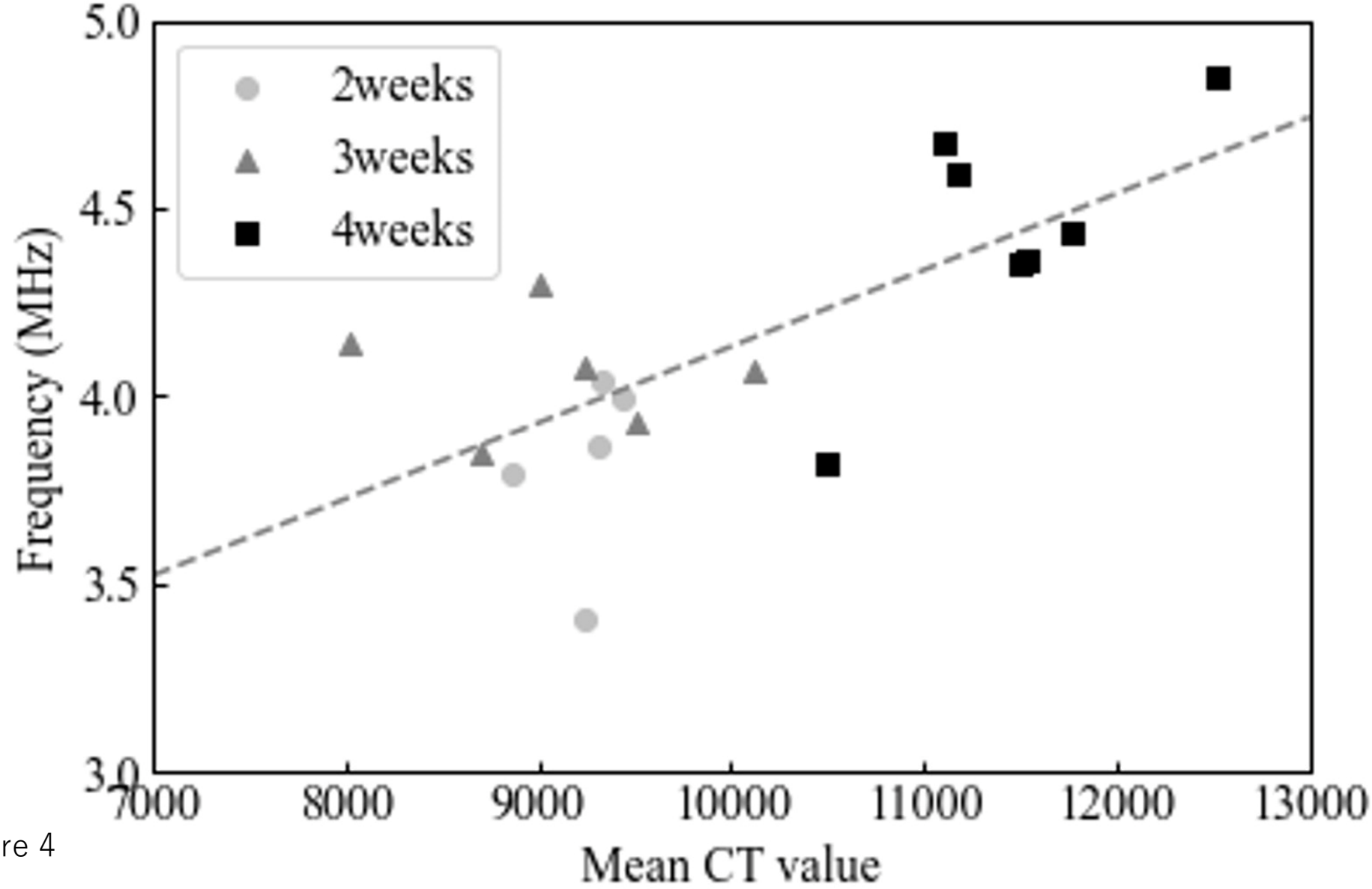
5.0
4.5
4.0
3.5
3.0
Frequency (MHz)
2weeks
3weeks
4weeks
7000
8000
9000
10000
11000
12000
13000
Mean CT value

Figure 4

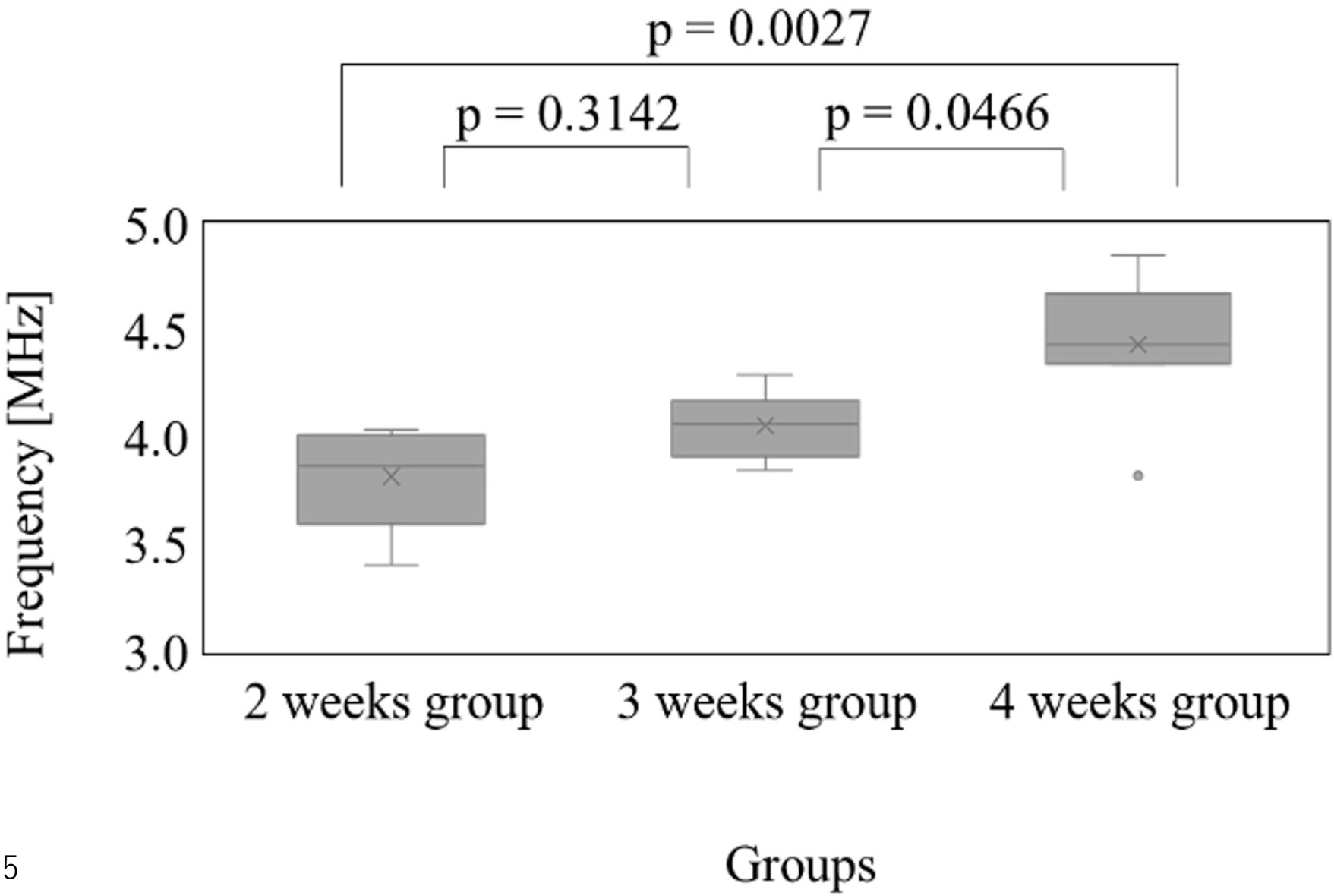
p = 0.0027
p = 0.3142
p = 0.0466
5.0
4.5
4.0
3.5
3.0
Frequency [MHz]
2 weeks group
3 weeks group
4 weeks group
Groups

Figure 5

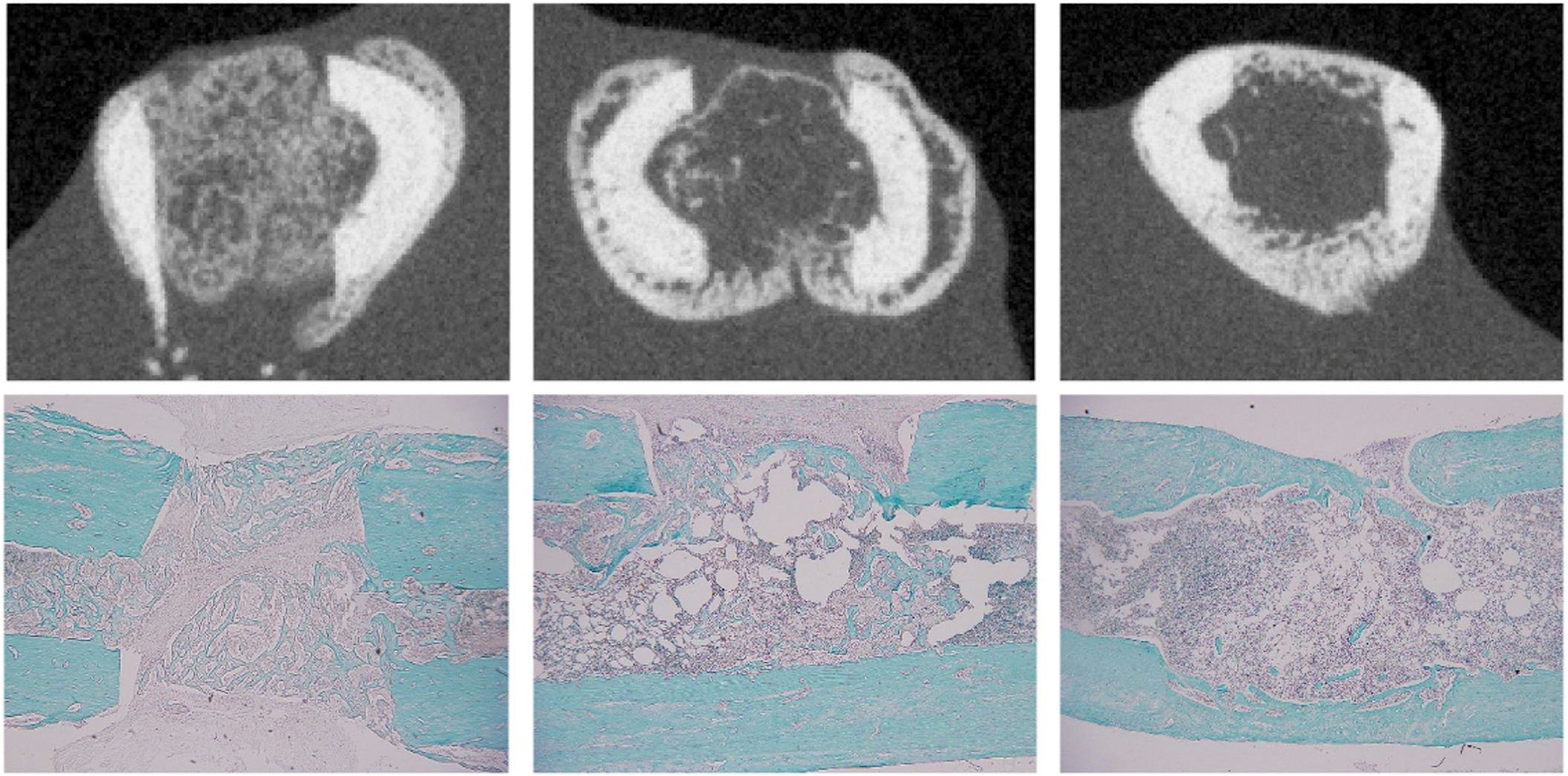

Figure 6 A B C

Table 1 Comparisons of frequencies between the 2 weeks group, the 3 weeks group, and the 4 weeks group.

	2 weeks group	3 weeks group	4 weeks group
N	5	6	7
Frequency [MHz]	3.82 ± 0.25**	4.06 ± 0.16*	4.44 ± 0.33

Tukey-Kramer test P-value to the 4 weeks group in Frequency (*$p < 0.05$, ** $p < 0.005$).