Kobe University Repository : Kernel

PDF issue: 2025-12-04

Preoperative varus deformity of the knee affects the intraoperative joint gap in unicompartmental knee arthroplasty

Nakano, Naoki ; Takayama, Koji ; Kuroda, Yuichi ; Maeda, Toshihisa ; Hashimoto, Shingo ; Ishida, Kazunari ; Hayashi, Shinya ; Hoshino,…

(Citation)
The Knee,32:90-96

(Issue Date)
2021-10

(Resource Type)
journal article

(Version)
Accepted Manuscript

(Rights)
© 2021 Elsevier B.V.
This manuscript version is made available under the CC-BY-NC-ND 4.0 license
http://creativecommons.org/licenses/by-nc-nd/4.0/

(URL)
https://hdl.handle.net/20.500.14094/90008659

Title

Preoperative varus deformity of the knee affects the intraoperative joint gap in unicompartmental knee arthroplasty

Authors

Naoki Nakano[1], Koji Takayama[1,2], Yuichi Kuroda[1], Toshihisa Maeda[1], Shingo Hashimoto[1], Kazunari Ishida[3], Shinya Hayashi[1], Yuichi Hoshino[1], Takehiko Matsushita[1], Takahiro Niikura[1], Ryosuke Kuroda[1], Tomoyuki Matsumoto[1]

Institution

[1] Department of Orthopaedic Surgery, Kobe University Graduate School of Medicine, 7-5-1 Kusunoki-cho, Chuo-ku, Kobe 650-0017, Japan

[2] Department of Orthopaedic Surgery, Anshin Hospital, 1-4-12, Minatojimaminami-machi, Chuo-ku, Kobe 650-0047, Japan

[3] Department of Orthopaedic Surgery, Kobe Kaisei Hospital, 3-11-15, Shinoharakita-machi, Nada-ku, Kobe 657-0068, Japan

Corresponding Author

Naoki Nakano MD, PhD

Department of Orthopaedic Surgery, Kobe University Graduate School of Medicine, 7-5-1 Kusunoki-cho, Chuo-ku, Kobe 650-0017, Japan

Tel: +81 (0) 78 382 5985

Fax: +81 (0) 78 351 6944

Email: gnaokix1981@gmail.com

Abstract

Background

It is generally believed that contraction of the soft tissue structures on the medial side may occur in the knee with severe varus deformity. However, the relationship between the severity of varus deformity of the knee and the intraoperative soft tissue balance in unicompartmental knee arthroplasty (UKA) has not been well reported thus far.

Methods

One hundred and three consecutive medial UKAs were enrolled. After the femoral trial prosthesis was placed, the component gap was measured at 10° (extension) and 120° (flexion) of flexion using a UKA tensor. The pre-osteotomy gap was then calculated from the thickness of the bone cut. Paired Student's t-test was used to compare the component gap, as well as the pre-osteotomy gap, in extension and those in flexion. The relationship between the preoperative Hip-Knee-Ankle (HKA) angle and the pre-osteotomy gap was analysed using Pearson's correlation coefficient and simple linear regression analysis.

Results

The component gap in extension was significantly smaller than that in flexion while the pre-osteotomy gap in extension was significantly wider than that in flexion. There was a positive correlation between the severity of varus deformation in preoperative knee and the pre-osteotomy gap in extension, while there was no correlation between the preoperative HKA angle and the pre-osteotomy gap in flexion.

Conclusions

The tension of the medial tightness does not correlate with the degree of preoperative varus deformity in UKA.

Keywords

Unicompartmental knee arthroplasty; varus deformity; intraoperative joint gap; soft-tissue balance; medial stability

1. Introduction

Osteoarthritis is the most common degenerative disease of the joint that affects a large part of the elderly population [1]. In case osteoarthritis is limited to a single compartment of the knee joint, usually the medial compartment, unicompartmental knee arthroplasty (UKA) can be a good option to obtain joint function and relieve knee pain [2]. Theoretically, UKA has some advantages over total knee arthroplasty (TKA), which is considered to be a technically well-established procedure in the treatment of end-stage degenerative joint disease or deformity of the knee over the past 30 years. UKA can preserve the bone stock and the patellofemoral compartments as well as the cruciate ligaments and natural knee kinematics [3], and has been reported to promote faster recovery [4] than TKA.

Although the results of UKA used to be disappointing with revision rates of up to 30% at 5–7 years in the 1970s [5,6], advances in implant design and surgical technique have generated promising survivorship statistics recently. The results of UKA at 10 years are approaching those reported for TKA [7], e.g., a systematic review revealed that the survival rate after medial UKA improved to 93.9% at 5 years, 91.7% at 10 years, 88.9% at 15 years, and 84.7% at 20 years [8]. On the other hand, other studies have shown that UKA survival does not match that of TKA despite current progress in the surgical procedure or implant design [9-11]. In terms of surgical technique, alignment and soft-tissue balance are considered to be essential in UKA for better clinical outcomes and implant survivorship [12-14], as aseptic loosening is the most common reason for failure in the early postoperative period and the progression of lateral osteoarthritis is the most common reason for failure in the midterm and late periods [15].

Knees with limited preoperative varus deformation are considered to have an unaltered soft

tissue envelope. However, it can be different in cases where the preoperative varus deformity is more advanced, since it is generally believed that the deformity itself has induced an abnormality in the soft tissue envelope of the knee [16, 17]. Thus, many knee surgeons believe that progressive shortening or contraction of the soft tissue structures on the medial side may occur in the knee with severe varus deformity [17-20]. However, to our knowledge, the relationship between the preoperative alignment of the knee, i.e., the severity of varus deformity of the knee, and the intraoperative soft tissue balance in UKA has not been well reported thus far and little or no data exist on the matter.

Aim of this study is to provide a detailed interpretation of the relationship between the preoperative alignment of the lower extremity and the intraoperative joint gap in patients undergoing UKA. Our hypothesis is that patients with severe varus deformation of the knee showed a narrower intraoperative joint gap.

2. Materials and Methods

The hospital ethics committee approved the study protocol (No. 1510, Data of Approval: 02 Dec 2013), and informed consent was obtained from all patients. One hundred and three consecutive patients were prospectively enrolled and underwent medial UKA using the Persona Partial Knee System (Zimmer Biomet inc., Warsaw, IN, USA) from September 2017 to August 2019. The inclusion criteria for UKA were a radiographic diagnosis of isolated medial compartment osteoarthritis or idiopathic osteonecrosis with an active ROM of > 90°, a fixed flexion deformity of < 10°, and a varus deformity of < 15°. Magnetic resonance imaging (MRI) was performed for all the cases before surgery and the cases without the intact anterior cruciate ligament (ACL) and articular surface of the lateral compartment were excluded from the study. As a result, no case was excluded and a total of 103 UKAs were finally included in the study. Three senior doctors, each with > 15 years of experience, performed the surgery.

After inflating the tourniquet to 250 mmHg, a mini-medial parapatellar approach was performed. Following the macroscopic observation of an intact ACL, the articular surface of the lateral and patellofemoral compartments, the minimal soft tissue release of the medial structures as well as the osteophyte removal was performed. A proximal tibial osteotomy was then performed using an accelerometer-based portable navigation system (OrthAlign Plus®, UniAlign™; OrthAlign Inc., Aliso Viejo, CA, USA), which helps the surgeon to precisely perform tibial osteotomy in UKA with coronal and sagittal alignment. It provides measurement accuracy of ± 0.5° when measuring the angle between the OrthAlign Plus® unit and the reference sensor (manufacturer's data). We examined the accuracy of tibial implant alignment using this system in UKA and reported that it decreased the outliers of tibial coronal and sagittal alignment [21].

The target value of preoperative planning in coronal alignment was set to 1.0° in varus and that in sagittal alignment was set with reference to the original slope. The original posterior tibial slope was measured with reference to the perpendicular line of the sagittal axis, which was defined as the line connecting the anterior one-third of the medial tibial plateau and midpoints of the tibial plafond. The mean posterior tibial slope was 7.4 ± 1.0° (range, 6.0°–10.0°). The sagittal alignment was set to 6.0° and 8.0° when the angle was ≤ 6.0° and ≥ 8.0°, respectively, and the target value was set as the target value of preoperative planning therebetween. Following the tibial osteotomy, a distal femoral osteotomy was performed with spacer block methods referring to the surface of the proximal tibial cut. The femoral rotation was carefully adjusted to the mechanical axis of the tibia, and the remaining (posterior and chamfer part) osteotomies of the femur were performed. The thickness of the tibial and femoral bone cut was measured using a caliper and the actual osteotomies were calculated by adding the thickness of the bone saw blades (1.27 mm).

Following the femoral osteotomies, a trial prosthesis was placed in the distal femur, and the component gap between the medial tibial osteotomy surface and the femoral trial prosthesis was measured using a UKA tensor. Reports on the design and the methodology of the UKA tensor have previously been published [22]. The UKA tensor (Fig. 1) consists of 3 parts - an upper plate, a lower platform plate with a spike, and an extra-articular main body. Upper and lower plates are to be placed at the medial compartment of the knee. By using this device, surgeons can measure the joint component gap while applying a constant joint distraction force. Joint distraction force was exerted between the upper and lower plates through a specially made torque driver. In preliminary in-vitro experiments, an error for joint distraction within ±3% was obtained. During the measurement, the medial parapatellar arthrotomy was temporarily repaired with stitches

proximal to the connection arm of the UKA tensor. The thigh and knee were aligned in the sagittal plane to eliminate the external load on the knee. The joint distraction forces were preloaded several times to minimise the error due to the creep of the surrounding soft tissues. After the joint distraction force of 20 lb (9.1kg) was applied, the component gap (in mm) between the centre midpoints of the upper surface of the plate and the proximal tibial cut was measured at 10° (extension) and 120° (flexion) of knee flexion, because the posterior femoral bone cut was designed to be parallel when the knee was 120° of flexion. The pre-osteotomy gap was then calculated and defined from the data of the thickness of the bone cut (Fig. 2). Preoperative and postoperative coronal hip–knee–ankle (HKA) angles were measured based on long-leg standing radiographs.

The data are expressed as means ± standard deviations. Paired Student's t-test was used to compare the component gap in extension and that in flexion. The pre-osteotomy gap in extension and that in flexion was compared using paired Student's t-test as well. The relationship between the preoperative HKA angle and the pre-osteotomy gap was analysed using Pearson's correlation coefficient and simple linear regression analysis. Data analyses were performed using BellCurve for Excel (Social Survey Research Information Co., Ltd., Tokyo, Japan). The sample size calculation was also performed using G*Power 3 (Heinrich Heine Universität Düsseldorf, Germany). Based on our calculations, a minimum sample size of 62 patients was required to observe a moderate correlation between the preoperative HKA angle and the pre-osteotomy gap with a type I error (α) of 0.01, a power ($1 - \beta$) of 0.80, and a correlation ρ H1 of 0.5. Statistical significance was considered at $P<0.01$.

3. Results

Patient demographics are shown in Table 1. Mean HKA angle was 7.7 ± 3.1° (range, 1.5°–15.5°) varus preoperatively and 3.5 ± 2.7° (range, -3.0°–10.0°) varus postoperatively. The mean values of the thickness of the tibial bone cut, the femoral distal bone cut, and the femoral posterior bone cut were 5.0 ± 0.9 mm, 6.1 ± 1.0 mm, and 8.0 ± 0.7 mm, respectively. The mean value of the component gap in extension was 10.0 ± 0.9 mm, which was significantly smaller than that in flexion (10.9 ± 1.6 mm) (Fig. 3a). The mean value of the pre-osteotomy gap in extension was 5.4 ± 1.6 mm, which was significantly greater than that in flexion (4.0 ± 2.0 mm) (Fig. 3b). Summary of results was shown in Table 2. The relationships between the preoperative HKA angle and the pre-osteotomy gap are shown in Fig. 4 (a: extension, b: flexion). There was a positive correlation between the severity of varus deformation in preoperative knee and the pre-osteotomy gap in extension (Fig. 4a, $R = 0.37$, $P < 0.01$), while there was no correlation between the preoperative HKA angle and the pre-osteotomy gap in flexion (Fig. 4b).

4. Discussion

The most important finding of the present study was that the degree of preoperative varus deformation of the knee positively correlated with the pre-osteotomy gap in extension during UKA, which shows that the tension of the medial tightness does not correlate with the degree of preoperative varus deformity. Our hypothesis was shown to be rejected. This result suggests that the contracture of the medial soft tissue structure does not exist even in knees with severe varus deformity. We assume contracture of the superficial medial collateral ligament does not exist after releasing the capsular ligaments with removal of the osteophytes, while osteoarthritic changes might increase stiffness of the medial soft tissue along with osteophyte formation.

Although it is generally believed that the development of medial tightness is correlated with the severity of the varus deformity, little data has existed on the issue. In other words, it is unknown whether the tension of the soft tissue on the medial side, i.e. mainly medial collateral ligament - medial joint tightness depends mostly on the condition of the superficial medial collateral ligament [23] - will increase with the progression of preoperative varus deformity. Therefore, it would be beneficial if we could know the relationship between intraoperative medial tightness and preoperative alignment before surgery.

It was reported by some authors that medial soft tissue contracture did not always exist in knees with varus deformation in TKA. Ushio et al [24] evaluated soft-tissue balance in 151 varus-deformed osteoarthritic knees using preoperative stress radiographs. Preoperative knee radiographs in the anteroposterior view with no stress and with varus/valgus stress in extension were assessed and the absolute joint line angle (an exact angle of the joint line) and the relative joint line angle (the absolute joint line angle minus the joint line angle in the neutral condition)

were compared. As a result, they found no significant differences in the numerical values of the relative joint line angle between varus and valgus stresses and concluded that contracture of medial soft tissue did not necessarily exist even in varus knees with osteoarthritis when considering articular cartilage wear, which is not inconsistent with our current result. They mentioned that because joint line tilting in the varus direction under non-stress conditions could cause underestimation of medial soft tissue laxity and overestimation of lateral soft tissue laxity, surgeons should be reminded that underestimating the medial joint laxity might cause excessive medial tissue release and increase the risks of postoperative instability. Okamoto et al [25] retrospectively reviewed 70 patients with varus-type osteoarthritis who underwent 90 TKA and divided them into three groups according to a degree of preoperative alignment (mild varus group (< 10°), moderate varus group (10°–20°), and severe varus group (> 20°)). Then, they compared intraoperative joint gap, amount of resected bone, and intraoperative soft tissue laxity on the lateral and medial sides according to the severity of preoperative varus deformity and found that there were no differences in the medial joint gaps among the groups. They concluded that the medial soft tissue was not shorter with greater varus deformity when taking the resected bone into account, which supports our current result.

The mean value of the pre-osteotomy gap was greater in extension than in flexion. UKA is normally performed to the knee with anteromedial osteoarthritis, which means that the anterior cruciate ligament is intact, thus the tibial anterior subluxation does not occur in the knee. The posterior slope of the medial tibial plateau decreases in the knee with anteromedial osteoarthritis where the anterior cartilage diminishes while the posterior cartilage remains, which might be the reason for the result. On the other hand, the mean value of the component gap was smaller in extension than in flexion. The Persona Partial Knee System is designed to have a feature that the

228 thickness of the femoral posterior bone resection is 2 mm greater than that of the posterior
229 portion of the component (data from Zimmer Biomet inc.) to achieve some laxity in flexion, which
230 could be the reason of the result.
231
232 The intraoperative medial compartment stability of the knee resulted in a better post-operative
233 knee flexion angle in UKA. Matsuzaki et al [26] showed that the post-operative knee flexion angle
234 following UKA was negatively correlated with the component gap at 90° of flexion and it was
235 negatively correlated with joint looseness, which was defined as the component gap minus the
236 polyethylene insert thickness, at 90° of flexion as well. In the case of UKA with severe varus
237 deformity where the pre-osteotomy gap in extension tends to be too wide, the component gap
238 can also be wider in extension than in flexion even with the use of the Persona Partial Knee
239 System where the thickness of the femoral posterior bone resection is designed to be 2 mm
240 greater than that of the femoral component. The manufacture, Zimmer Biomet inc., offers a
241 special zig to reduce the thickness of the distal femoral bone cut, and surgeons can take
242 advantage of the zig to achieve a better postoperative soft-tissue balance in such a case.
243
244 This study has several limitations. First, our study was limited to the medial compartment of
245 osteoarthritic knees and no knees with valgus deformities or rheumatoid arthritis were included.
246 Also, we did not compare non-arthritic knees with osteoarthritic knees, and these might impact
247 our results, although most knees that are subject to UKA have varus deformity due to
248 osteoarthritis. We trust our data are useful to understand the difference in the soft-tissue balance
249 between mild and severe varus deformities. Second, other factors such as patella alta/baja or
250 contracture of the quadriceps might have influenced the assessment of intraoperative joint gap.
251 In this study, we attempted to focus on preoperative varus alignment and intraoperative joint

gap as it would be useful for knee surgeons to predict the intraoperative joint gap simply from the degree of preoperative varus deformity. Third, this study was based only on plain radiographs, which could cause inaccurate measurement of the alignment in the lower extremity and misinterpretation of its effects on the medial tightness. A CT-based study may be more accurate in evaluating the alignment. Fourth, the study did not evaluate clinical outcomes. Further research involving the assessment of intraoperative joint gap and clinical outcomes, ideally subjective outcomes, should be conducted in the future. Fifth, this study is not a prospective cohort study monitoring the longitudinal change that may occur with respect to soft tissue tightness and alignment preoperatively. We have to investigate the progression of preoperative deformity of the knee before drawing a definite conclusion in the future.

5. Conclusion

Surgeons tend to consider the intraoperative joint gap to be tight in the knee with severe varus deformity, however, the present study exhibited the opposite results, i.e., the degree of preoperative varus deformation of the knee positively correlated with the intraoperative gap in extension during UKA. The result implies that the tension of the medial tightness does not correlate with the degree of varus deformity of the knee. We believe the result of the current study is helpful for knee surgeons to achieve better postoperative soft-tissue balance and consequently obtain higher patient satisfaction following UKA.

Conflict of interest

The authors have declared no conflict of interest.

Ethical approval

The study was approved by the Review Board at our institution.

Funding

None declared.

Legends to figures

Fig. 1

The UKA tensor used in this study

It consists of three parts: an upper seesaw plate, a lower platform plate with a spike and an extra-articular main body.

Fig. 2

Definition of the pre-osteotomy gap

The pre-osteotomy gap = the component gap + the thickness of the femoral component - (the thickness of the tibial bone cut + the thickness of distal femoral bone cut (in extension) or posterior femoral bone cut (in flexion))

Fig. 3

The mean component gap and the pre-osteotomy gap in extension and flexion

The mean value of the component gap in extension was significantly smaller than that in flexion (a). The mean value of the pre-osteotomy gap in extension was significantly greater than that in flexion (b).

Fig. 4

The relationships between the preoperative Hip-Knee-Ankle (HKA) angle and the pre-osteotomy gap in extension and flexion

Patients with more varus deformation in their preoperative knee tended to show a wider pre-osteotomy gap in extension (a), while there was no correlation between the preoperative HKA angle and the pre-osteotomy gap in flexion (b).

308 **References**

309 1. Brooks PM. Impact of osteoarthritis on individuals and society: how much disability?
310 Social consequences and health economic implications. Curr Opin Rheumatol. 2002;14: 573-7.
311 2. Berger RA, Nedeff DD, Barden RM, Sheinkop MM, Jacobs JJ, Rosenberg AG, et al.
312 Unicompartmental knee arthroplasty. Clinical experience at 6- to 10-year followup. Clin Orthop
313 Relat Res. 1999: 50-60.
314 3. Heyse TJ, El-Zayat BF, De Corte R, Chevalier Y, Scheys L, Innocenti B, et al. UKA closely
315 preserves natural knee kinematics in vitro. Knee Surg Sports Traumatol Arthrosc. 2014;22: 1902-
316 10.
317 4. Lombardi AV, Jr., Berend KR, Walter CA, Aziz-Jacobo J, Cheney NA. Is recovery faster for
318 mobile-bearing unicompartmental than total knee arthroplasty? Clin Orthop Relat Res. 2009;467:
319 1450-7.
320 5. Aleto TJ, Berend ME, Ritter MA, Faris PM, Meneghini RM. Early failure of
321 unicompartmental knee arthroplasty leading to revision. J Arthroplasty. 2008;23: 159-63.
322 6. Brin YS, Nikolaou VS, Joseph L, Zukor DJ, Antoniou J. Imageless computer assisted
323 versus conventional total knee replacement. A Bayesian meta-analysis of 23 comparative studies.
324 Int Orthop. 2011;35: 331-9.
325 7. Rand JA, Ilstrup DM. Survivorship analysis of total knee arthroplasty. Cumulative rates
326 of survival of 9200 total knee arthroplasties. J Bone Joint Surg Am. 1991;73: 397-409.
327 8. van der List JP, McDonald LS, Pearle AD. Systematic review of medial versus lateral
328 survivorship in unicompartmental knee arthroplasty. Knee. 2015;22: 454-60.
329 9. Lyons MC, MacDonald SJ, Somerville LE, Naudie DD, McCalden RW. Unicompartmental
330 versus total knee arthroplasty database analysis: is there a winner? Clin Orthop Relat Res.
331 2012;470: 84-90.

10. Niinimäki T, Eskelinen A, Mäkelä K, Ohtonen P, Puhto AP, Remes V. Unicompartmental knee arthroplasty survivorship is lower than TKA survivorship: a 27-year Finnish registry study. Clin Orthop Relat Res. 2014;472:1496-501.

11. Arirachakaran A, Choowit P, Putananon C, Muangsiri S, Kongtharvonskul J. Is unicompartmental knee arthroplasty (UKA) superior to total knee arthroplasty (TKA)? A systematic review and meta-analysis of randomized controlled trial. Eur J Orthop Surg Traumatol. 2015;25:799-806.

12. Whiteside LA. Making your next unicompartmental knee arthroplasty last: three keys to success. J Arthroplasty. 2005;20: 2-3.

13. Takayama K, Ishida K, Muratsu H, Kuroda Y, Tsubosaka M, Hashimoto S, et al. The medial tibial joint line elevation over 5 mm restrained the improvement of knee extension angle in unicompartmental knee arthroplasty. Knee Surg Sports Traumatol Arthrosc. 2018;26: 1737-42.

14. Takayama K, Matsumoto T, Muratsu H, Ishida K, Araki D, Matsushita T, et al. The influence of posterior tibial slope changes on joint gap and range of motion in unicompartmental knee arthroplasty. Knee. 2016;23: 517-22.

15. van der List JP, Zuiderbaan HA, Pearle AD. Why Do Medial Unicompartmental Knee Arthroplasties Fail Today? J Arthroplasty. 2016;31: 1016-21.

16. Lewek MD, Rudolph KS, Snyder-Mackler L. Control of frontal plane knee laxity during gait in patients with medial compartment knee osteoarthritis. Osteoarthritis Cartilage. 2004;12: 745-51.

17. Siston RA, Goodman SB, Delp SL, Giori NJ. Coronal plane stability before and after total knee arthroplasty. Clin Orthop Relat Res. 2007;463: 43-9.

18. Mihalko WM, Miller C, Krackow KA. Total knee arthroplasty ligament balancing and gap kinematics with posterior cruciate ligament retention and sacrifice. Am J Orthop (Belle Mead NJ).

356 2000;29: 610-6.

357 19. Sharma L, Lou C, Felson DT, Dunlop DD, Kirwan-Mellis G, Hayes KW, et al. Laxity in
358 healthy and osteoarthritic knees. Arthritis Rheum. 1999;42: 861-70.

359 20. Matsumoto T, Muratsu H, Kubo S, Matsushita T, Kurosaka M, Kuroda R. The influence
360 of preoperative deformity on intraoperative soft tissue balance in posterior-stabilized total knee
361 arthroplasty. J Arthroplasty. 2011;26: 1291-8.

362 21. Suda Y, Takayama K, Ishida K, Hayashi S, Hashimoto S, Niikura T, et al. Improved implant
363 alignment accuracy with an accelerometer-based portable navigation system in medial
364 unicompartmental knee arthroplasty. Knee Surg Sports Traumatol Arthrosc.2020;28:2917-23.

365 22. Matsumoto T, Muratsu H, Kubo S, Kuroda R, Kurosaka M. Intra-operative joint gap
366 kinematics in unicompartmental knee arthroplasty. Clin Biomech (Bristol, Avon). 2013;28: 29-33.

367 23. Ren D, Liu Y, Zhang X, Song Z, Lu J, Wang P. The evaluation of the role of medial
368 collateral ligament maintaining knee stability by a finite element analysis. J Orthop Surg Res.
369 2017;12: 64.

370 24. Ushio T, Mizu-Uchi H, Okazaki K, Miyama K, Akasaki Y, Ma Y, et al. Medial soft tissue
371 contracture does not always exist in varus osteoarthritis knees in total knee arthroplasty. Knee
372 Surg Sports Traumatol Arthrosc. 2019;27: 1642-50.

373 25. Okamoto S, Okazaki K, Mitsuyasu H, Matsuda S, Iwamoto Y. Lateral soft tissue laxity
374 increases but medial laxity does not contract with varus deformity in total knee arthroplasty. Clin
375 Orthop Relat Res. 2013;471: 1334-42.

376 26. Matsuzaki T, Matsumoto T, Muratsu H, Ishida K, Takayama K, Nagai K, et al. The
377 contribution of intraoperative medial compartment stability to post-operative knee flexion angle
378 in unicompartmental knee arthroplasty. Knee Surg Sports Traumatol Arthrosc. 2017;25: 272-76.

379

380

381

Fig. 1

Fig. 2

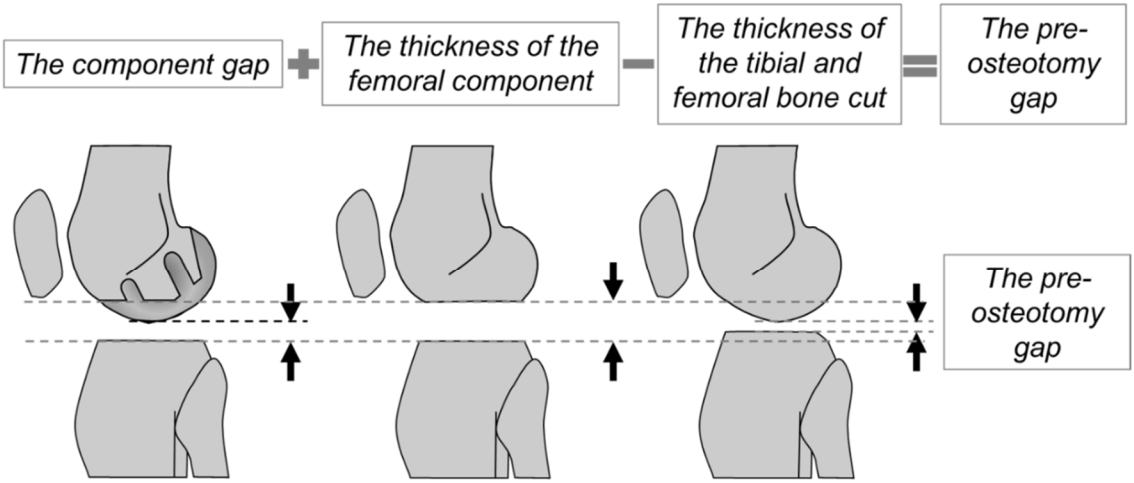
The component gap
The thickness of the femoral component
The thickness of the tibial and femoral bone cut
The pre-osteotomy gap
The pre-osteotomy gap

Fig. 2

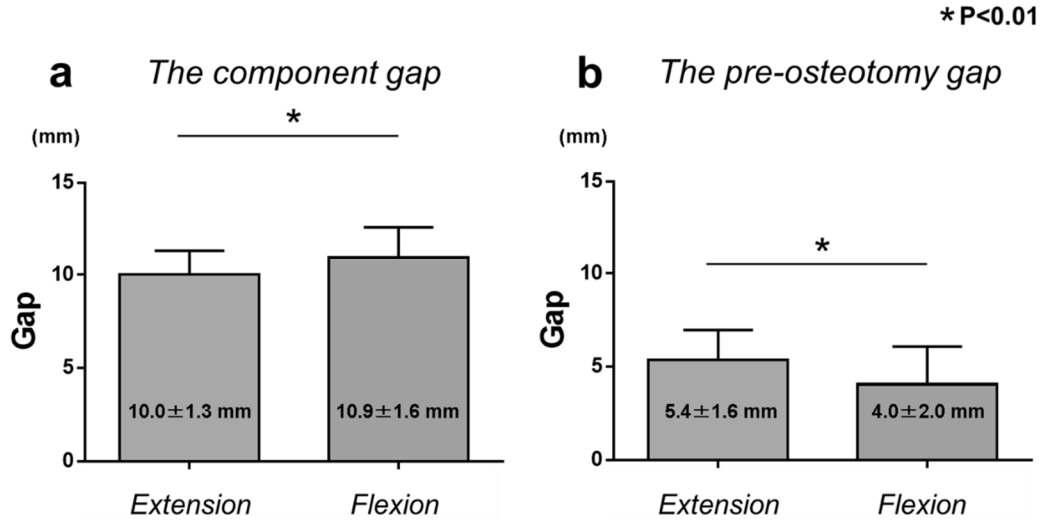
* P<0.01
a
The component gap
(mm)
*
Gap
15
10
5
0
10.0±1.3 mm
10.9±1.6 mm
Extension
Flexion
b
The pre-osteotomy gap
(mm)
*
Gap
15
10
5
0
5.4±1.6 mm
4.0±2.0 mm
Extension
Flexion

Fig. 4

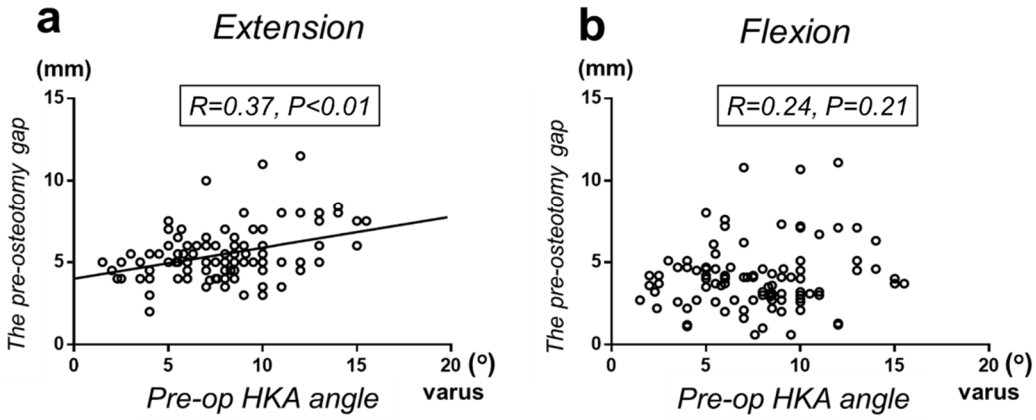
a
Extension
(mm)
R=0.37, P<0.01
The pre-osteotomy gap
15
10
5
0
0
5
10
15
20 (°)
Pre-op HKA angle
varus
b
Flexion
(mm)
R=0.24, P=0.21
The pre-osteotomy gap
15
10
5
0
0
5
10
15
20 (°)
Pre-op HKA angle
varus

Table 1

Patient demographics

The values are given as the mean and standard deviation for continuous variables

UKA: unicompartmental knee arthroplasty, HKA: Hip- Knee- Ankle, SD: standard deviation

Age (years)	74.4 (range, 54–95; SD: 8.7)
Gender (male : female)	28 : 75
Side of UKA (left : right)	50 : 53
Preoperative diagnosis	Osteoarthritis: 87, idiopathic osteonecrosis: 16
Preoperative HKA angle (°)	7.7 (range, 1.5–15.5; SD: 3.1)

Table 2

Summary of results

The values are given as the mean and standard deviation

HKA: Hip- Knee- Ankle, SD: standard deviation

Postoperative HKA angle (°)	3.5 (range, -3.0–10.0; SD: 2.7)
Thickness of the tibial bone cut (mm)	5.0 (range, 2.3–6.8; SD: 0.9)
Thickness of the femoral distal bone cut (mm)	6.1 (range, 4.3–9.3; SD: 1.0)
Thickness of the femoral posterior bone cut (mm)	8.0 (range, 6.3–10.3; SD: 0.7)
The component gap in extension (mm)	10.0 (range, 8.0–15.0; SD: 0.9)
The component gap in flexion (mm)	10.9 (range, 8.0–16.0; SD: 1.6)
The pre-osteotomy gap in extension (mm)	5.4 (range, 2.0–11.5; SD: 1.6)
The pre-osteotomy gap in flexion (mm)	4.0 (range, 0.6–11.1; SD: 2.0)