Kobe University Repository : Kernel

PDF issue: 2025-12-04

Efficacy of preoperative cine magnetic resonance imaging in evaluation of adhesion of renal cancer thrombus to inferior vena cava wall

Ueki, Hideto ; Terakawa, Tomoaki ; Ueno, Yoshiko ; Sofue, Keitaro ; Horii, Shintaro ; Okamura, Yasuyoshi ; Bando, Yukari ; Hara, Takuto ;…

(Citation)
Journal of Vascular Surgery: Venous and Lymphatic Disorders,10(4):908-915

(Issue Date)
2022-07

(Resource Type)
journal article

(Version)
Accepted Manuscript

(Rights)
© 2022 by the Society for Vascular Surgery. Published by Elsevier Inc.
This manuscript version is made available under the Creative Commons Attribution-NonCommercial-NoDerivatives 4.0 International license.

(URL)
https://hdl.handle.net/20.500.14094/90009445

Efficacy of Preoperative Cine MRI in the Evaluation of Adhesion of Renal Cancer Thrombus to the Wall of the Inferior Vena Cava

Hideto Ueki[1)], Tomoaki Terakawa[1)], Yoshiko Ueno[2)], Keitaro Sofue[2)], Shintaro Horii[3)], Yasuyoshi Okamura[1)], Yukari Bando[1)], Takuto Hara[1)], Junya Furukawa[1)], Kenichi Harada[1)], Nobuyuki Hinata[1)], Yuzo Nakano[1)], Takamichi Murakami[2)], and Masato Fujisawa[1)]

1) Department of Urology, Kobe University Graduate School of Medicine, Kobe, Japan.

2) Department of Radiology, Kobe University Graduate School of Medicine, Kobe, Japan.

3) Division of Radiology, Department of Medical Technology, Kobe University Hospital, Kobe, Japan

Corresponding Author:

Tomoaki Terakawa:

Department of Urology, Kobe University Graduate School of Medicine, Kobe, Japan.

Kusunoki-cho, Chuo-ku, Kobe, 650-0017, Japan.

Tel: +81-78-382-5681

Fax: +81-78-382-5715

E-mail address: daatera0804@yahoo.co.jp

Post-publication Corresponding Author:

Hideto Ueki:

Department of Urology, Kobe University Graduate School of Medicine, Kobe, Japan.

Kusunoki-cho, Chuo-ku, Kobe, 650-0017, Japan.

Tel: +81-78-382-5681

Fax: +81-78-382-5715

E-mail address: far.e.is.w@gmail.com

Keywords:

Renal cell carcinoma; Inferior vena cava thrombus; Cine MRI; Preoperative planning, Sensitivity and specificity

ARTICLE HIGHLIGHTS

Type of Research: Single-center retrospective cohort study

Key Findings: The presence of dynamic blood flow, and the presence of tumor thrombus mobility on cine MRI could reliably predict IVC resection with 100% (95%-CI: 51.8-100) sensitivity and 85.7% (95%-CI:42.1-1.00) specificity.

Take home Message: Cine MRI could be a helpful examination modality to predict the need for IVC wall resection in patients with renal cell carcinoma with venous tumor thrombus.

Table of Contents Summary

Cine MRI predicted the need for IVC resection with high accuracy in this retrospective study of 15 patients who underwent radical nephrectomy and tumor thrombectomy. The authors suggest the use of cine MRI to predict the IVC wall resection preoperatively.

Abstract

Objective:

In renal cell carcinoma with inferior vena cava (IVC) thrombus, adhesion or invasion to the IVC wall often increases the level of surgical difficulty and even necessitates resection of the IVC. It is generally difficult to perform an accurate preoperative assessment by the standard imaging modalities of contrast-enhanced computed tomography and standard magnetic resonance imaging (MRI). Cine MR imaging is an MRI sequence that captures motion to produce detailed information on both anatomy and dynamic motion. The present study aimed to evaluate the accuracy of preoperative cine MRI for determining IVC wall resection, with the validation of the imaging findings based on the intraoperative findings.

Methods:

Fifteen patients who underwent radical nephrectomy and tumor thrombectomy between May 2018 and April 2020 met the inclusion criteria. The primary outcome of interest was the need for IVC resection because of adhesion or invasion of a venous tumor thrombus. Cine MRI evaluated the blood flow between the tumor thrombus and the IVC wall, and the presence of tumor thrombus mobility under free respiration. Sensitivity and specificity were

calculated for preoperative cine MRI for IVC wall resection. Fisher's exact test was used to determine the association between intraoperative IVC wall resection and the cine MRI findings. Furthermore, receiver operating characteristic curves and the area under the curve were used to compare the accuracy of conventional MRI and cine MRI.

Results:

Eight (53.3%) of the patients underwent IVC resection. We found that the absence of dynamic blood flow and tumor thrombus mobility on cine MRI could reliably predict IVC resection with 100% (95%-CI: 51.8-100) sensitivity and 85.7%(95%-CI:42.1-1.00) specificity. The area under the curve of the receiver operating characteristic curve was 0.821 for conventional MRI and 0.929 for cine MRI.

Conclusion:

In the preoperative setting, cine MRI could be a helpful examination modality to predict the need for IVC wall resection in patients with renal cell carcinoma with venous tumor thrombus.

Introduction

Renal cell carcinoma (RCC) shows a propensity for vascular growth, with 4-10% of patients developing an inferior vena cava (IVC)thrombus[1]. Radical nephrectomy with thrombectomy is a curative option, offering a 5-year-survival rate of 40-65% for RCC with venous tumor thrombus (VTT)[2,3]. However, in the case of IVC wall invasion, surgery to achieve the radical resection of the tumor is more challenging. The surgical approach to patients with RCC and VTT should be individualized, mainly according to the characteristics of the VTT. The current RCC with VTT classification systems, such as the Mayo Clinic classification[1], only take into account the VTT's location, which may be insufficient for evaluating the probability of IVC invasion intraoperatively. If tumor invasion of the inferior vena cava (IVC) wall is present, partial or circumferential resection of the IVC is indicated, often resulting in the need for IVC reconstruction. Although there is an increasing number of cases in which tyrosine kinase inhibitor (TKI) or TKI-Immuno oncology (IO) are administered preoperatively to reduce VTT, it is unclear whether this reduces adhesions and invasion to the IVC. Before surgery, it is essential to know the level of the thrombus, and whether the tumor thrombus is adherent to the IVC wall.

Pre-surgical imaging to evaluate the proximal extent, the volume of tumor thrombus, potential of caval wall adhesion, and invasion is crucial in the management of RCC with VTT, and provides the information that is necessary to determine the best surgical approach for a given patient.[4–6] Conventionally, ultrasonography (US), computerized tomography (CT), and magnetic resonance imaging (MRI) have been used to detect VTT. Although US is a first-line modality that is commonly used to evaluate patients with RCC[5], this method mainly depends on the ultrasonographer and the position of the thrombus[5]. If the tumor thrombus lies below the level of the insertion of the hepatic veins, the sensitivity of US in the detection of VTT is reported to be as low as 68%[7]. The advent of multi-detector computed tomography (MDCT) enabled the use of 3D CT datasets for reconstruction without loss of quality. However, one disadvantage of MDCT is the difficulty of delineation because the Hounsfield unit (HU) values of blood and thrombus can be similar. It is challenging to diagnose venous invasion or adhesion because the contrast medium does not flow past the compression and prohibits good delineation of a tumor thrombus.[5,8]. MRI has proven to be the most effective imaging modality for detecting VTT, with a sensitivity level of 100%[8]. MRI has intrinsic contrast superiority to CT and does not rely on contrast medium to differentiate tumor thrombus from blood. MRI has

therefore replaced conventional methods as the new choice for elucidating the presence of VTT. However, when the IVC blood flow decreases below a specific range due to tumor compression, the effect of slice saturation may lead to false-positive diagnoses[9]. As with CT, it is challenging to detect adhesion or infiltration of the IVC wall.

Cine MR imaging is a type of MRI sequence that captures motion. Cine images are obtained by repeatedly imaging the area of interest for a certain time, typically within a single slice. This yields detailed information on both anatomy and dynamic motion. Several studies reported that cine MRI was beneficial for evaluating abdominal adhesion[10] or lung cancer invasion to the thoracic wall[11] for surgical planning.

Therefore, in the present study, we aimed to evaluate the accuracy of preoperative cine MRI for determining wall resection of the IVC, based on features such as the presence of dynamic flow between the tumor thrombus and IVC wall and tumor thrombus mobility under free respiration, with the validation of the imaging findings based on the intraoperative results.

Methods

Patients

The Institutional Review Board approved this retrospective study (the number of the ethics approval: No. B210141). Between May 2018 and June 2021, 18 patients who diagnosed with RCC and IVC thrombus by CT received a radical nephrectomy and vena cava thrombectomy at Kobe University Hospital. Three patients who had level 0 VTT were excluded from this cohort. The remaining 15 patients with VTT formed were included in the analysis.

Approval of the study was obtained from the local institutional review board (Kobe University Hospital Review Board, Protocol Number: B210141, 30 in August 2021, and written informed consent was obtained from all patients.

Patient characteristics

The clinical features included age, sex, tumor side, pre-surgical therapy, operative methods, pathological diagnosis, VTT Mayo level, and pathological wall invasion. Preoperative MRI was used to assess the IVC thrombus levels for all patients. The tumor thrombus level in the IVC was classified according to the Mayo classification, Level I:

within 2 cm of the renal vein, Level II: more than 2 cm from the renal vein and less than or equal to the short hepatic vein, Level III: more than the short hepatic vein and below the diaphragm, and Level IV: above the diaphragm. Cases with tumor thrombus as low as the cephalic end of the renal vein were excluded.

MR imaging technique

In all cases, MRI examinations, including cine MRI were performed within one month before surgery. Patients who underwent pre-surgical therapies such as TKI or IO had a cine MRI immediately before surgery to provide the most recent information on VTT. All MRI examinations were performed on 1.5T or 3.0T units (Achieva nova dual 1.5T; Philips Medical Systems, The Netherlands, Signa Premier 3.0T; GE Healthcare, United States) with body array coils. The usual clinical protocol for urological MR imaging [axial T1-, T2-, and diffusion-weighted images (WI), and coronal/sagittal steady-state free precession (SSFP) images] was taken to cover the kidney and VTT. For cine imaging, two different types of SSFP images were obtained to assess the adhesion of VTT and the vessel wall: images taken on the largest cross-sectional area of VTT in the oblique coronal plane under deep breathing; and images taken to cover the whole VTT in the oblique coronal plane with

pulse wave synchronization. The cine imaging enabled to visualize motion of IVC wall and VTT, and venous flow in the IVC, which resulted in precise assessment of the adhesion between the VTT and the IVC wall (supplementary video). For both types of cine imaging, the image time for 1 slide was 0.824 s, and one loop was taken in 33.1 s. The MRI parameters are shown in Table 1.

Image analysis

Two board-certified radiologists (Y.U. and K.S.), with 10 and 8 years of experience, independently evaluated the MR images. The MR images of each patient were presented on a dedicated workstation (ShadeQuest/ViewR v1.27.01, FUJIFILM Medical Solutions Corporation). On MR images,the following items were evaluated: vertical tumor diameter, the contact length between the VTT and the IVC wall, maximum anterior-posterior (AP) IVC diameter, AP and coronal IVC diameter at the renal vein ostium (RVo), and AP and coronal renal vein diameters at the RVo[12] (Fig 1). Since standard MRI was taken with breath-hold and IVC diameter is almost unaffected by cardiac cycle, the effect of respiration and the cardiac cycle were considered negligible. The following items were assessed on cine MRI: the high signal of blood flow between tumor thrombus and the IVC

wall on the same side and the presence of tumor thrombus mobility under free respiration (Supplementary file 1 and 2). More specifically, the presence of dynamic flow between tumor thrombus and the IVC wall referred to a delineation between the thrombus and the vessel wall and the blood signal in the affected area (Fig 2-B.). At the time of evaluation, the two readers were blinded to the histopathological findings and surgical results.

Operating technique and outcomes of interest

The intraoperative decision of the presence of tumor adhesion was made as follows. First, the IVC wall was incised after blocking the proximal, distal IVC and the contralateral renal vein, and the lumen was observed. Next, adhesions between the VTT and the IVC wall were determined grossly and by palpation. Simple thrombectomy was undertaken if there was no intraoperative evidence of VTT involving the IVC wall. Vein resection was performed if the VTT appeared to have adhesion or invasion to the IVC wall. If IVC resection compromised ≥1/3 of the IVC lumen, the IVC was then reconstructed using patch grafts. GORE-TEX® EPTFE GRAFT II (W.L. Gore & Associates, Inc. USA) was used for the patch grafts. If complete circumferential resection of the IVC was required due to an IVC wall defect of ≥1/2, a synthetic tube interposition graft was employed. The

primary outcome of interest was the need for IVC resection because of adhesion or invasion of the VTT. The relationship between the presence or absence of IVC resection and the clinical findings, including the cine MRI findings, was investigated. We set out to determine whether cine MR is a reliable and effective method for detecting the presence of IVC wall adhesion or invasion in cases of RCC with VTT.

Statistical analysis

Continuous features were summarized as the median and interquartile range (IQR); categorical features were summarized as the number and percentage. The Mann-Whitney U test was used to evaluate differences, and Fisher's exact test was used for cross-tabulated data. Due to the small sample size, only a univariate analysis was performed. Furthermore, receiver operating characteristic (ROC) curves were used to analyze the sensitivity and specificity of each cutoff value for IVC resection. AUCs were calculated. In addition, the accuracy of conventional MRI and cine MRI for IVC wall resection was assessed according to the sensitivity, specificity, positive predictive value, and negative predictive value. All statistical analyses were conducted using EZR (Saitama Medical Center, Jichi Medical University, Japan). P values of <0.05 were considered statistically significant.

Results

Intraoperative findings and outcomes

Table 2 shows all 15 patients who received radical nephrectomy for RCC with IVC thrombus and the univariate analysis of the clinical and radiographic features predicting IVC resection during tumor thrombectomy. Eight (53.3%) of these patients underwent IVC resection, including 2 vascular patch grafts and 2 synthetic tube interposition grafts. Thirteen patients were preoperatively treated with tyrosine kinase inhibitor (TKI) or immune-oncology–KI combination therapy. IVC resection was related to the level of thrombus extension (I to IV) (P=0.031). The tumor thrombus level just before the surgery was Level I in 4 patients, Level II in 9 patients, and Level III in 2 patients. The 2 cases of Level IV were both reduced to Level III or less by pre-surgical therapy when cine MRI was performed. In the beginning, pre-surgical therapy was performed for patients with RCC with thrombus at level Ⅲ or higher at our hospital. However, the indication for pre-surgical therapy has been expanded as its efficacy has been established. The two cases in the non-resection group were early cases in this study, and their tumor thrombus level was less than or equal to level Ⅱ. Therefore pre-surgical therapy was not performed.

Cine MRI imaging findings

A significant difference in the AP diameter of the IVC at the ostium on conventional MRI (20.5 vs. 17.3 mm; P=0.037) was observed between the two groups, namely the IVC resection group vs. the No resection group. The maximum AP IVC diameter (23.4 vs. 18.6 mm; P=0.132), coronal diameter of the IVC at the RVo (25.9 vs. 17.3 mm; P=0.563), and AP and coronal diameters of the renal vein at the level of the RVo (12.9 vs. 18.6 mm; P=0.487 and 17.8 vs. 18.0 mm; P=1.000, respectively) did not differ to a statistically significant extent between the two groups. An ROC curve analysis was performed to determine the cutoff value of the AP diameter of the IVC at the ostium for predicting IVC resection. The cutoff value of the AP diameter of the IVC at the ostium was 18.48 mm (sensitivity, 85.7%; specificity, 75.0%) (Fig 2). Moreover, there was no significant difference in the vertebral median tumor diameter in the IVC (55.3 vs. 39.2 mm; P=0.083) or the median tumor-IVC wall contact length (54.9 vs. 16.2 mm; P=0.064) between the two groups.

We found that the absence of dynamic blood flow on cine MRI could reliably predict IVC resection with 100% sensitivity (95%-CI: 51.8-100) and 85.7% specificity (95%-CI:42.1-1.00) (Fisher's test: p-value < 0.001). Moreover, the absence of tumor thrombus mobility on cine MRI could predict IVC resection with 100% sensitivity (95%-CI: 51.8-

100) and 85.7% specificity (95%-CI: 42.1-100) (Fisher's test: p-value < 0.001). The positive predictive value (PPV) was 89.0% (95%-CI: 51.8-99.7), and the negative predictive value reached 100% (95%-CI: 42.1-100). The area under the curve (AUC) of the ROC was 0.821 for the IVC diameter and 0.929 for the absence of dynamic blood flow and tumor thrombus mobility (Fig 3). The Kappa coefficients were 0.86 and the cine MRI findings of the two radiologists were almost in perfect agreement. There were 2 cases of pathological wall invasion, both of which were correctly identified based on the absence of blood flow and tumor thrombus mobility on cine MRI.

Discussion

This study was performed to determine whether cine MRI could accurately determine adhesion or invasion of the IVC wall by VTT. There were two important clinical observations. First, there was a significant difference in dynamic flow between the tumor thrombus and the IVC wall and the absence of tumor thrombus mobility on cine MRI between patients managed with or without resection of the IVC with 100% sensitivity (95%CI: 51.8-100) and 85.7% specificity (95%-CI:42.1-1.00). Second, when these two features on cine MRI were used, the accuracy of the prediction of whether additional resection of the IVC wall was required was superior to that of the prediction based on the AP diameter of the IVC at the ostium. We believe that this critical information is imperative for determining the best surgical approach when VTT is suspected. When evaluating images, the presence of tumor thrombus mobility did not depend on the size of the VTT. However, when evaluating the presence of blood flow, the dynamic flow of level II-III thrombus was easier to recognize in comparison to level I thrombus. We therefore believe that a certain thrombus height is necessary to determine the flow in detail.

There have been some previous reports on imaging risk factors for IVC invasion, adhesion, and wall resection. Psutka et al. [12]. identified three radiographic features as

preoperative risk factors that predicted the need for IVC resection: AP diameter of the IVC, right side, and complete occlusion of the IVC with renal vein at the ostium (RVo). They defined IVC resection as any partial or segmental resection that resulted in the need for vascular surgical reconstruction, as in our study. They suggested that the most tolerable area for invasion of the IVC wall is the RVo, and that the IVC diameter at the RVo can be used to predict IVC resection or invasion of the IVC wall. They presented a multivariable model of these three factors, and the c-index for the model was 0.81. In the present study, the AP diameter of the IVC at the RVo was significantly higher in the IVC resection group (20.5 vs. 17.3 mm; P=0.037), which is consistent with previous reports. Liu et al. [12]. also reported a multivariate model of maximum coronal IVC diameter, residual IVC blood flow on ultrasound, and bland thrombus for IVC vascular wall invasion. This prediction model was designed to evaluate factors that potentially predict the probability of IVC resection by combining US with MRI/CT findings. US could provide hemodynamic information. Therefore, the use of different modalities was revolutionary in that they covered each other's shortcomings. That accuracy was 80.8%, and the AUC of the ROC was 0.899. Adams et al. [13] proposed a purely MR-based approach to predicting IVC wall invasion and reported that contact of the IVC thrombus or breach of the vessel wall could reliably

diagnose wall invasion on preoperative MRI imaging with 92.3% sensitivity and 86.4% specificity. Previous studies found tumor signals on both sides of the vessel wall and contrast enhancement of the thrombus to be reliable indicators of vessel breach and IVC wall invasion[14]. However, when the IVC wall is compressed by a large tumor or an enlarged lymph node, blood flow is reduced, and the lumen becomes saturated, making it difficult to evaluate the presence of invasion by MRI. They suggested that future studies on the preoperative evaluation of IVC invasion could include the reduced field of view diffusion-weighted imaging sequences to investigate whether additional information on thrombus composition may be gained. However, this method has not yet been proven, and it is not clear whether it is practical. In this respect, cine MRI, which can express the presence or absence of blood flow with continuous imaging, can detect low-velocity blood flow and thus fully overcome the shortcomings of MRI. There has not yet been a systematic comparison between CT and MRI in the detection of IVC wall invasion. Therefore, the proposal of a method to qualitatively evaluate VTT is of great value.

In respiratory surgery, Kajiwara et al. [14] compared the performance of cine MRI and CT in the detection of chest wall invasion. Their prospective study showed that cine MRI had better results than conventional static CT in terms of specificity, sensitivity, and

accuracy (sensitivity: 100.0%, specificity: 68.5%, and accuracy: 77.0%, respectively). Akata et al. [15]. suggested that cine MR provides more reliable information on chest wall invasion in lung cancer patients, showing high sensitivity (100%) and specificity (82.8%). In the present study, two radiologists evaluated dynamic flow between the tumor thrombus and the IVC wall and tumor thrombus mobility on cine MRI and obtained similar sensitivity and specificity to past reports concerning the respiratory region. Since the AUC was higher for cine MRI findings than for standard MRI findings, dynamic flow between tumor thrombus and the IVC wall and tumor thrombus mobility were more accurate predictors of IVC resection. Regarding the results of the present study , the high sensitivity (100%) and the high negative predictive value (100%) achieved with cine MRI suggest that if the IVC thrombus does not show any contact with the vessel wall, IVC wall invasion can be reliably excluded. Since the two factors showed the same value in all cases, an increased number of cases is required to determine which is the superior predictive factor. No additional equipment is required for cine MRI, and it is even possible to set up within a standard 1.5T MRI system. In addition, although we evaluated the VTT on coronal imaging, it can be depicted with other slices (e.g., sagittal imaging); thus, the VTT can be evaluated irrespective of the side of the IVC that it is in contact with. The fact that no

contrast medium is used and no radiation exposure is involved is also a significant advantage of cine MRI. In clinical practice, urologists can use cine MRI information to improve their preoperative planning (e.g., consultation with vascular surgeons or determining the need for specific operative resources). Since it is not difficult to introduce cine MRI, as described above, urologists should actively use cine MRI and apply it clinically. Since there is no established evaluation factor for cine MRI, we would like to provide a highly accurate prediction model combining standard MRI in the future.

This study was associated with some limitations. First, the sample size was relatively small. Second, due to its retrospective design, a potential selection bias cannot be excluded. Third, as the reference standard of intraoperative IVC resection was used for wall invasion and adhesion, the outcome was subjective. However, the presence or absence of intraoperative IVC resection is more important than the presence or absence of adhesion or invasion when considering the degree of impact on the patient. Therefore, we believe that the outcomes were appropriately set in this study. Fourth, as the present study was performed in a single center, external validation of the applied MR features is warranted.

In conclusion, cine MRI could be useful for preoperatively predicting the adhesion or invasion of of the IVC wall by a tumor thrombus in renal cancer with VTT.

1. Blute ML, Leibovich BC, Lohse CM, Cheville JC, Zincke H. The Mayo Clinic experience with surgical management, complications and outcome for patients with renal cell carcinoma and venous tumour thrombus. BJU Int. 2004 Jul;94(1):33–41.

2. Lambert EH, Pierorazio PM, Shabsigh A, Olsson CA, Benson MC, McKiernan JM. Prognostic risk stratification and clinical outcomes in patients undergoing surgical treatment for renal cell carcinoma with vascular tumor thrombus. Urology. 2007 Jun;69(6):1054–8.

3. Manassero F, Mogorovich A, Di Paola G, Valent F, Perrone V, Signori S, et al. Renal cell carcinoma with caval involvement: contemporary strategies of surgical treatment. Urol Oncol. 2011 Nov;29(6):745–50.

4. Pouliot F, Shuch B, Larochelle JC, Pantuck A, Belldegrun AS. Contemporary management of renal tumors with venous tumor thrombus. J Urol. 2010 Sep;184(3):833–41; quiz 1235.

5. Guo H-F, Song Y, Na Y-Q. Value of abdominal ultrasound scan, CT and MRI for diagnosing inferior vena cava tumour thrombus in renal cell carcinoma. Chin Med J . 2009 Oct 5;122(19):2299–302.

6. Trombetta C, Liguori G, Bucci S, Benvenuto S, Garaffa G, Belgrano E. Evaluation of tumor thrombi in the inferior vena cava with intraoperative ultrasound. World J Urol. 2007 Aug;25(4):381–4.

7. Schwerk WB, Schwerk WN, Rodeck G. Venous renal tumor extension: a prospective US evaluation. Radiology. 1985 Aug;156(2):491–5.

8. Hallscheidt PJ, Fink C, Haferkamp A, Bock M, Luburic A, Zuna I, et al. Preoperative staging of renal cell carcinoma with inferior vena cava thrombus using multidetector CT and MRI: prospective study with histopathological correlation. J Comput Assist Tomogr. 2005 Jan;29(1):64–8.

9. Liu Z, Li L, Hong P, Zhu G, Tang S, Zhao X, et al. A Predictive Model for Tumor Invasion of the Inferior Vena Cava Wall Using Multimodal Imaging in Patients with Renal Cell Carcinoma and Inferior Vena Cava Tumor Thrombus. Biomed Res Int. 2020

Oct 6;2020:9530618.

10. Lang RA, Buhmann S, Hopman A, Steitz H-O, Lienemann A, Reiser MF, et al. Cine-MRI detection of intraabdominal adhesions: correlation with intraoperative findings in 89 consecutive cases. Surg Endosc. 2008 Nov;22(11):2455–61.

11. Kajiwara N, Akata S, Uchida O, Usuda J, Ohira T, Kawate N, et al. Cine MRI enables better therapeutic planning than CT in cases of possible lung cancer chest wall invasion. Lung Cancer. 2010 Aug;69(2):203–8.

12. Psutka SP, Boorjian SA, Thompson RH, Schmit GD, Schmitz JJ, Bower TC, et al. Clinical and radiographic predictors of the need for inferior vena cava resection during nephrectomy for patients with renal cell carcinoma and caval tumour thrombus. BJU Int. 2015 Sep;116(3):388–96.

13. Adams LC, Ralla B, Bender Y-NY, Bressem K, Hamm B, Busch J, et al. Renal cell carcinoma with venous extension: prediction of inferior vena cava wall invasion by MRI. Cancer Imaging. 2018 May 3;18(1):17.

14. Aslam Sohaib SA, Teh J, Nargund VH, Lumley JSP, Hendry WF, Reznek RH. Assessment of tumor invasion of the vena caval wall in renal cell carcinoma cases by magnetic resonance imaging. J Urol. 2002 Mar;167(3):1271–5.

15. Akata S, Kajiwara N, Park J, Yoshimura M, Kakizaki D, Abe K, et al. Evaluation of chest wall invasion by lung cancer using respiratory dynamic MRI. J Med Imaging Radiat Oncol. 2008 Feb;52(1):36–9.

Table1. MR Imaging Parameters

Parameter	Sequence	Acquisition plane	TR/TE (msec)	matrix	number of excitations	FOV (cm)	section thickness (mm)	b-value (sec/mm^2)
Routine examinations								
T2WI	FSE	axial	2600-2800/80	256-320/204-260	1	36-38	5	-
DWI	EPI	axial	-/60	96-120/96-166	3	36-38	5	0, 1000
SSFP	3D-GRE	coronal and sagittal	3/1.3	192/240-272	1	36-40	5	-
T1WI	Dual GRE	axial	190/[1.1/2.3]	120/166	1	36-38	5	
Cine MRI								
SSFP Under deep breathing	3D-GRE	Oblique coronal	3/1.3	192/204	1	36-38	8	
SSFP with pulse synchronization	3D-GRE	Oblique coronal	3/1.3	160-192/200-224	1	36	5	

Note. T2WI = T2 weighted imaging, DWI=diffusion weighted imaging, SSFP= steady-state free precession, T1WI = T1 weighted imaging, FSE = fast spin echo, EPI=echo planar imaging, 3D-GRE= three-dimensional gradient-echo, TE = echo time, TR = repetition time, FOV= field of view.

Table 2. Characteristics of the study population

Features	Resection of the IVC n=8	No resection of the IVC n=7	P
	Median (IQR)		
Age, years	71.5 (66.5-79.0)	68.0 (60.0-69.5)	0.352
Tumor Vertabral Diameter, mm	55.3 (36.5-79.6)	39.2 (24.3-41.7)	0.083
Tumor-IVC wall contact length, mm	54.9 (19.5-75.6)	16.2 (7.40-24.4)	0.064
Coronal Diameter of the IVC at the ostium, mm	25.9 (21.7-29.0)	17.3 (15.8-17.9)	0.563
Coronal Diamerer of the Renal Vein at the ostium, mm	17.8 (14.2-23.5)	18.0 (15.1-21.1)	1
Maximum AP diameter of the IVC, mm	23.4 (19.6-26.1)	18.6 (17.6-19.7)	0.132
AP diameter of the Renal Vein at the ostium, mm	12.9 (12.3-15.3)	18.6 (11.8-20.7)	0.487
AP diameter of the IVC at the ostium, mm	20.5 (18.3-25.2)	17.3 (15.8-17.9)	0.037*
	N (%)		
Sex			0.315
Male	3 (37.5)	5 (71.4)	
Female	5 (62.5)	2 (28.6)	
Sides			1
Right	7 (87.5)	7 (100.0)	
Left	1 (12.5)	0	
Pre-surgical Therapy			0.2
No	0	2 (28.6)	
Yes	8 (100.0)	5 (71.4)	
Tumor thrombus level			0.031*
I	0	4 (57.1)	
II	6 (75.0)	3 (42.9)	
III	2 (25.0)	0	

IV	0	0	
Operative method			0.467
Open	8 (100.0)	6 (85.7)	
Laparoscopic surgery	0	1 (14.3)	
Pathological type			1
Clear Cell Carcinoma	6 (75)	7 (100.0)	
Other	2 (25)	0	
Vascular wall invasion			0.467
No	6 (75.0)	7 (100.0)	
Yes	2 (25.0)	0	
IVC Blood Flow on Cine MRI			0.001*
No	8 (100.0)	1 (14.3)	
Yes	0	6 (85.7)	
Thrombus Mobility on Cine MRI			0.001*
No	8 (100.0)	1 (14.3)	
Yes	0	6 (85.7)	

Figure legends

Figure 1.

Coronal (A) and axial (B) fast imaging employing steady-state acquisition (FIESTA) shows an infiltrative RCC in the right kidney of a 68-year-old man with a level II tumor thrombus throughout the right renal vein and extending into the inferior vena cava (IVC). The renal vein ostial diameter (black arrow) and antero-posterior IVC (white arrow) were evaluated as measurable endpoints on standard MRI. This patient was treated without IVC resection. Another coronal (C) image shows the maximum anterior-posterior (AP) IVC diameter (white arrow).

Figure 2-A.

A coronal contrast-enhanced CT image did not clearly show adhesion between the tumor and the IVC (Dotted black line of the ellipse).

Figure 2-B.

Cine MRI clearly showed blood flow between the IVC wall and tumor thrombus (white arrows: supplemental file). The authors predicted that there was no adhesion of tumor

thrombus from this preoperative image. Simple thrombectomy without reconstruction was undertaken if the tumor thrombus did not adhere to or invade the IVC.

Fig 3.

The area under the ROC curve was 0.821 for the IVC diameter (Dotted black line) and 0.929 for the presence of dynamic blood flow or tumor thrombus mobility (solid black line).

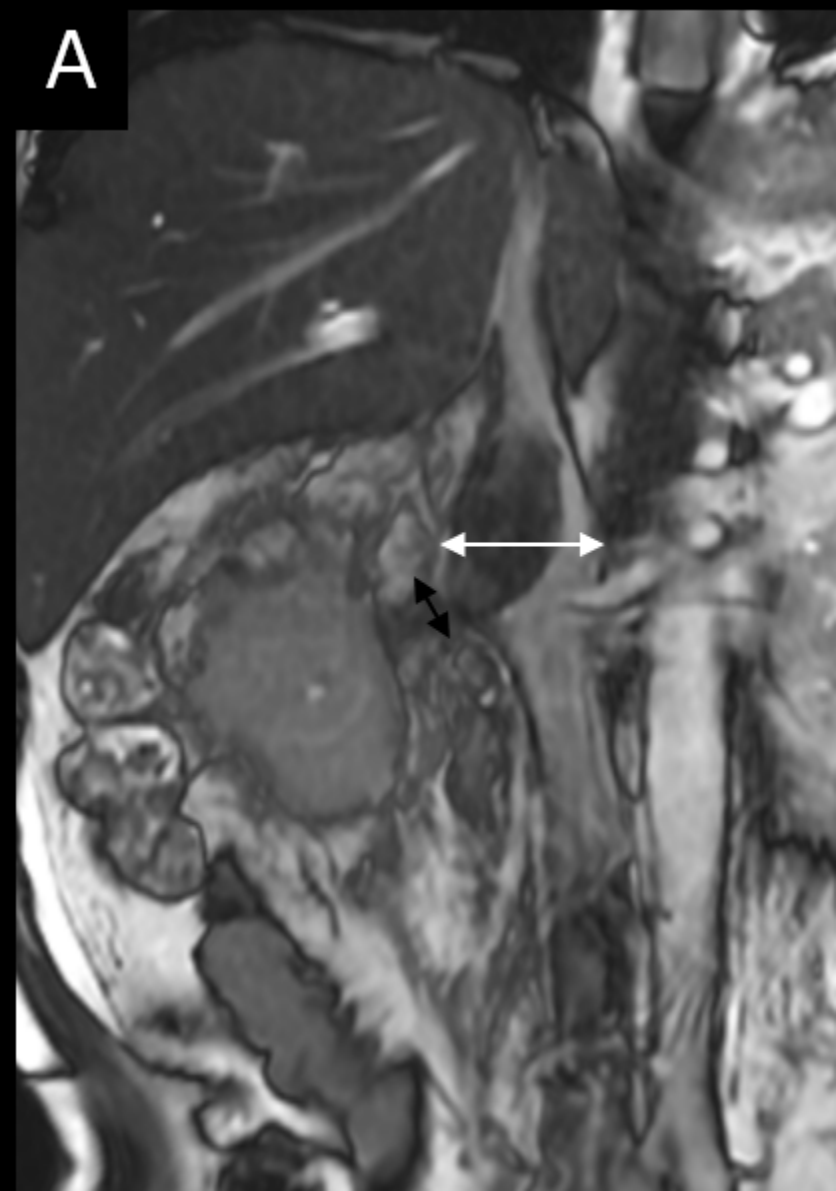
A

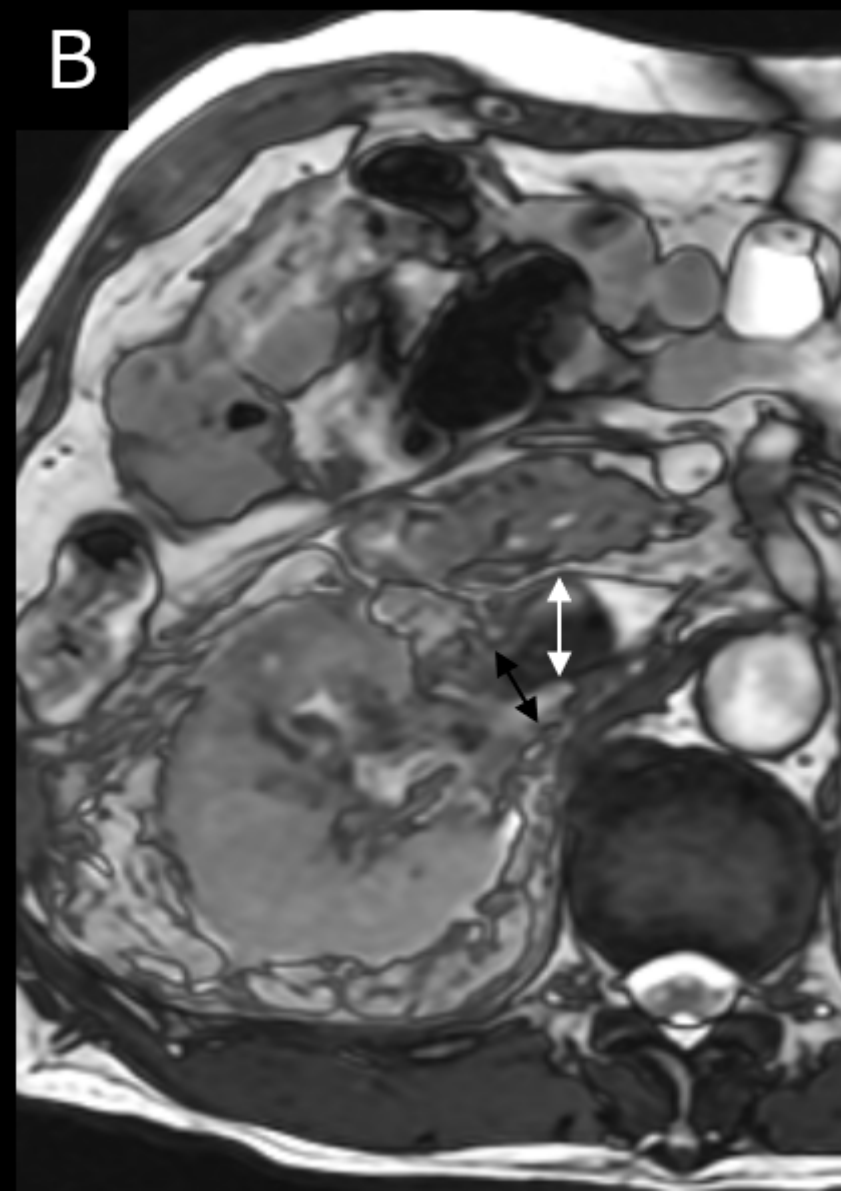
B

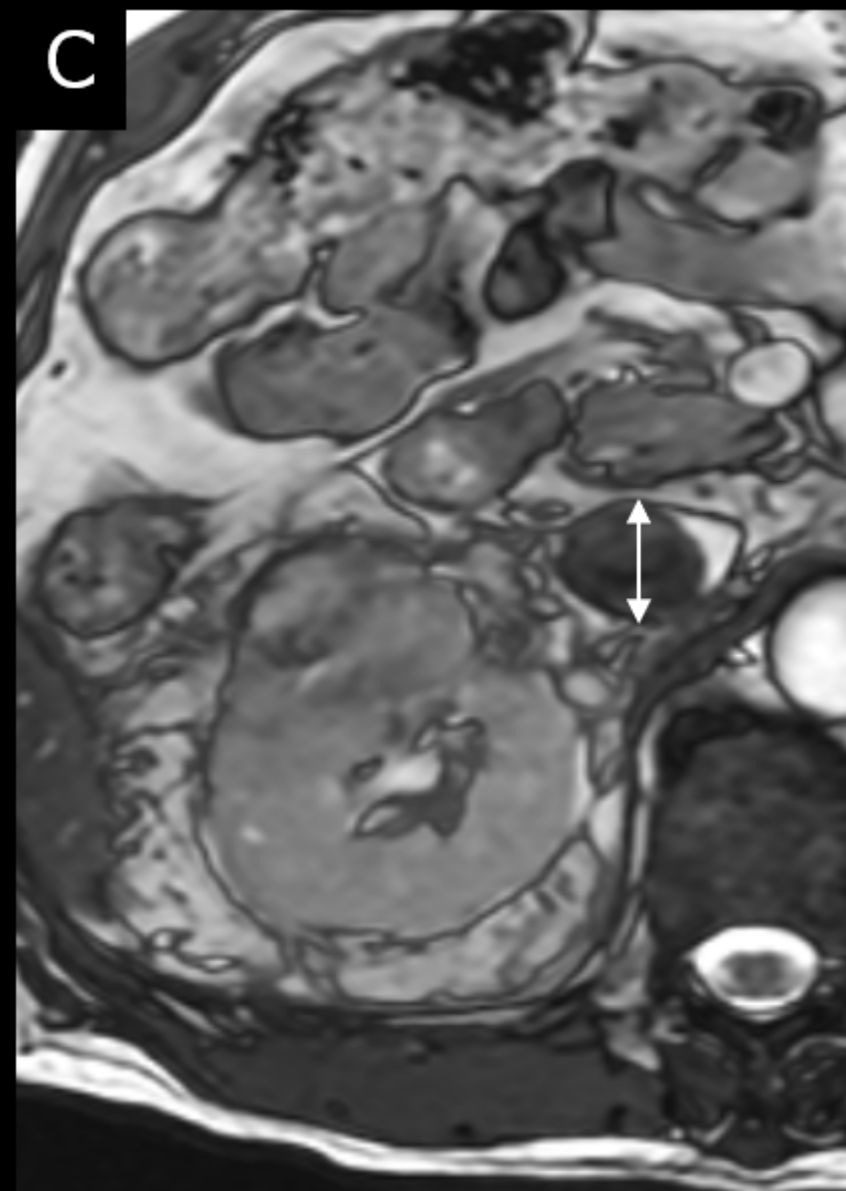
C

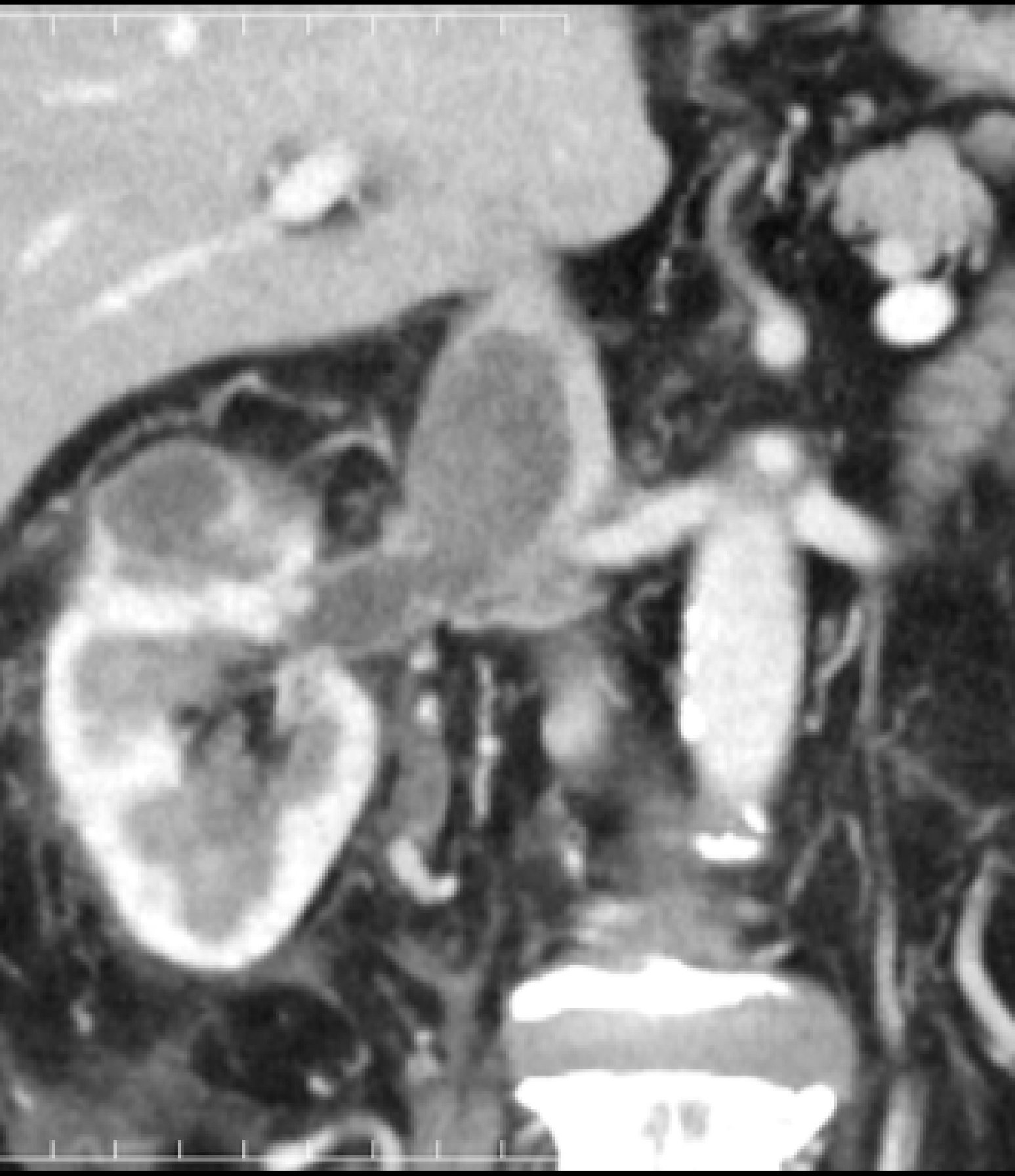

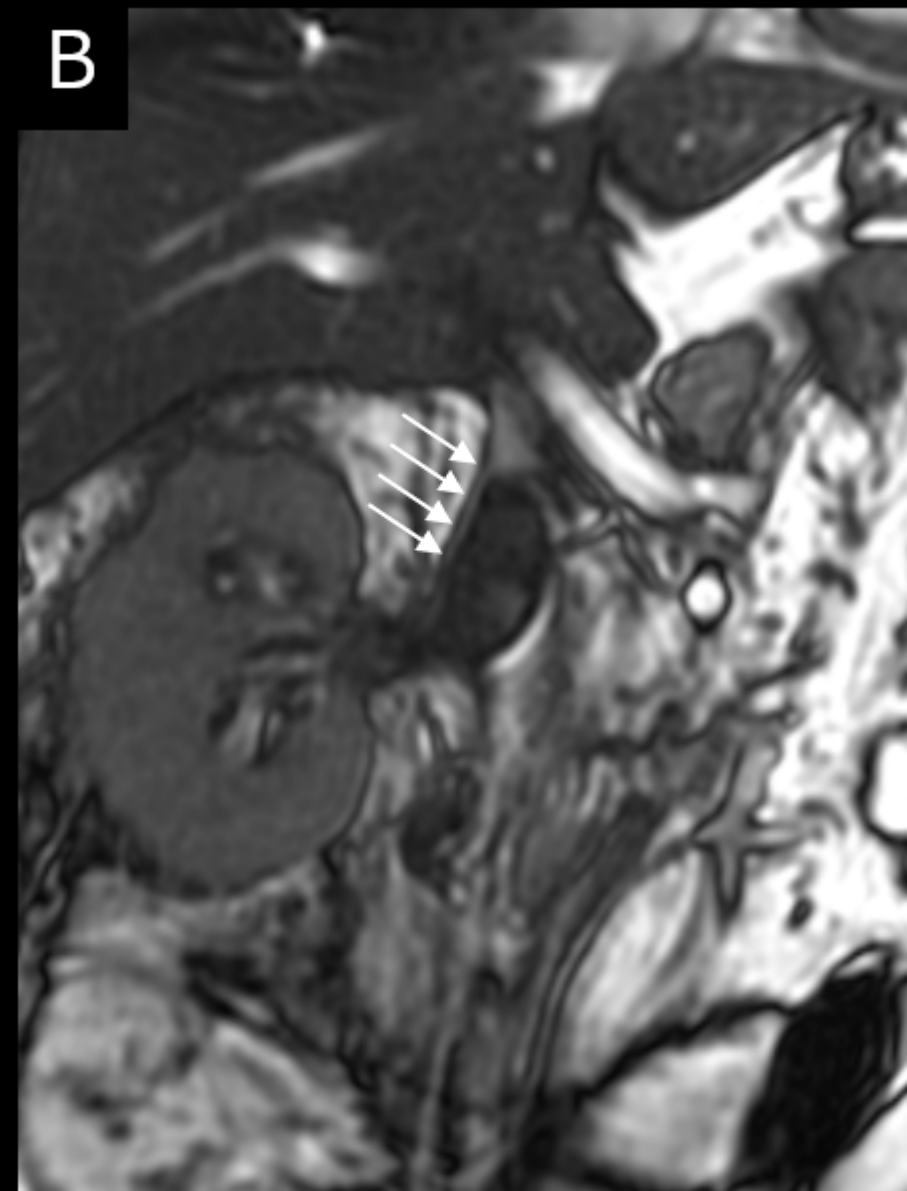
B

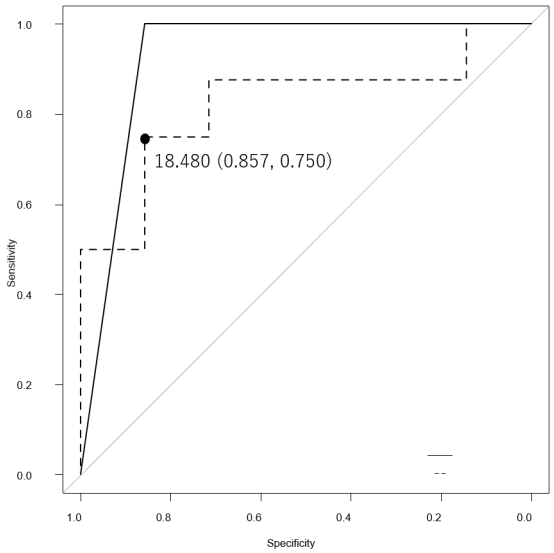
1.0
0.8
0.6
0.4
0.2
0.0
Sensitivity
18.480 (0.857, 0.750)
1.0
0.8
0.6
0.4
0.2
0.0
Specificity

Supplementary file 1

Case of left kidney tumor with level III tumor thrombus.

There is clear blood flow between IVC and VTT, and the tumor is moving with the blood flow.

(Blood flow +, Tumor thrombus mobility +)

Supplementary file 2

Case of right kidney tumor with level III tumor thrombus.

The tumor is in close contact with the IVC wall and there is no blood flow between them. There is no movement as well.

(Blood flow -, Tumor thrombus mobility -)