



Data base of Histology Color slides

Mizoguchi, Fumio

(Issue Date)

2015-05-04

(Resource Type)

learning object

(Version)

Version of Record

(Rights)

1. 利用者による利用の範囲は、著作権法に定める私的利用の範囲とする。2. 研究成果を利用者が利用した結果について、許諾者はその責任を負わない。
私的利用の範囲を超える二次利用（印刷物、ウェブサイト、発表資料等への転載など）については、利用希望者は附属図書館（<https://lib.kobe-u.ac.jp/da/secondaryuse/#secondaryuse-...>）

(URL)

<https://hdl.handle.net/20.500.14094/90009617>



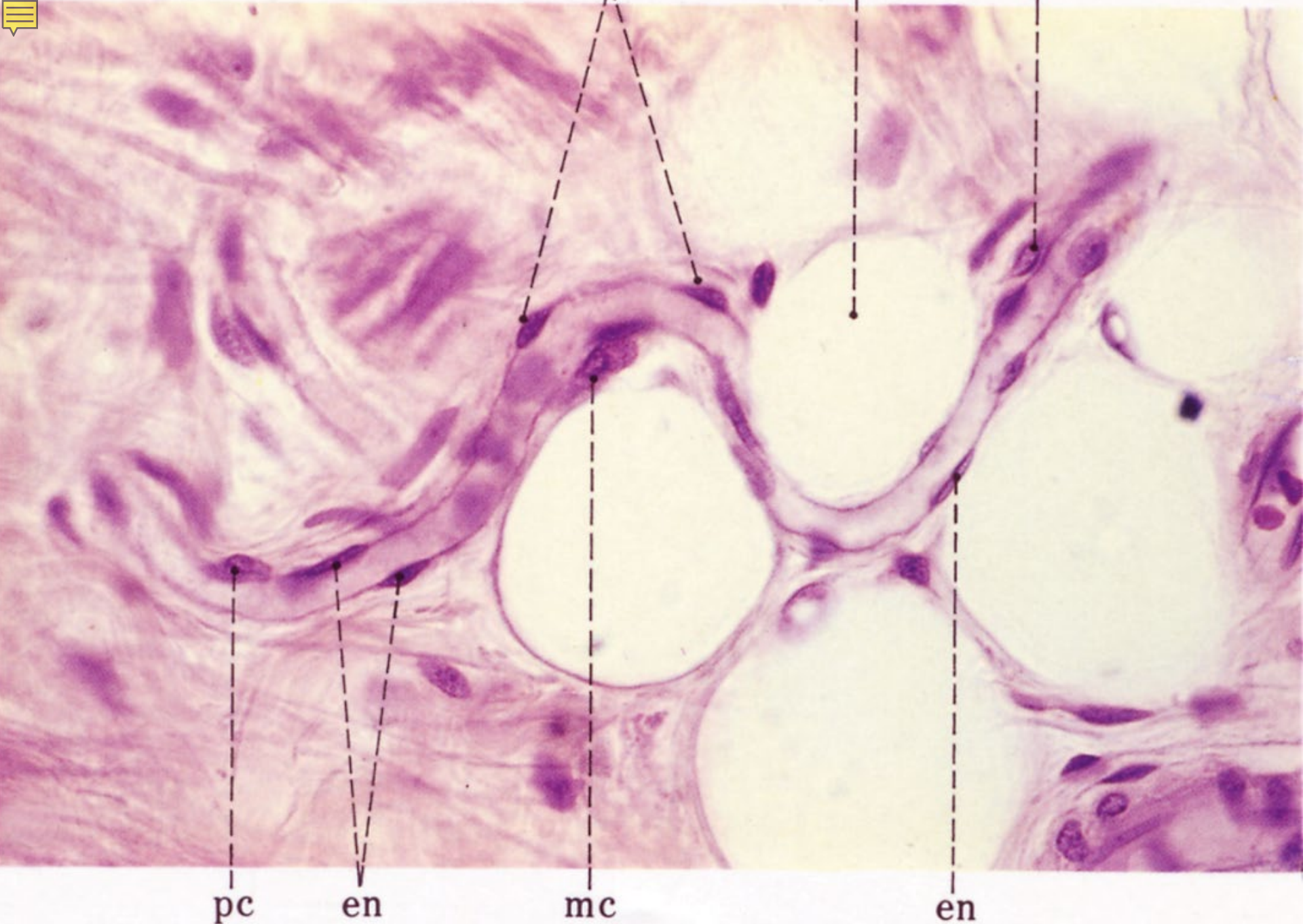


06

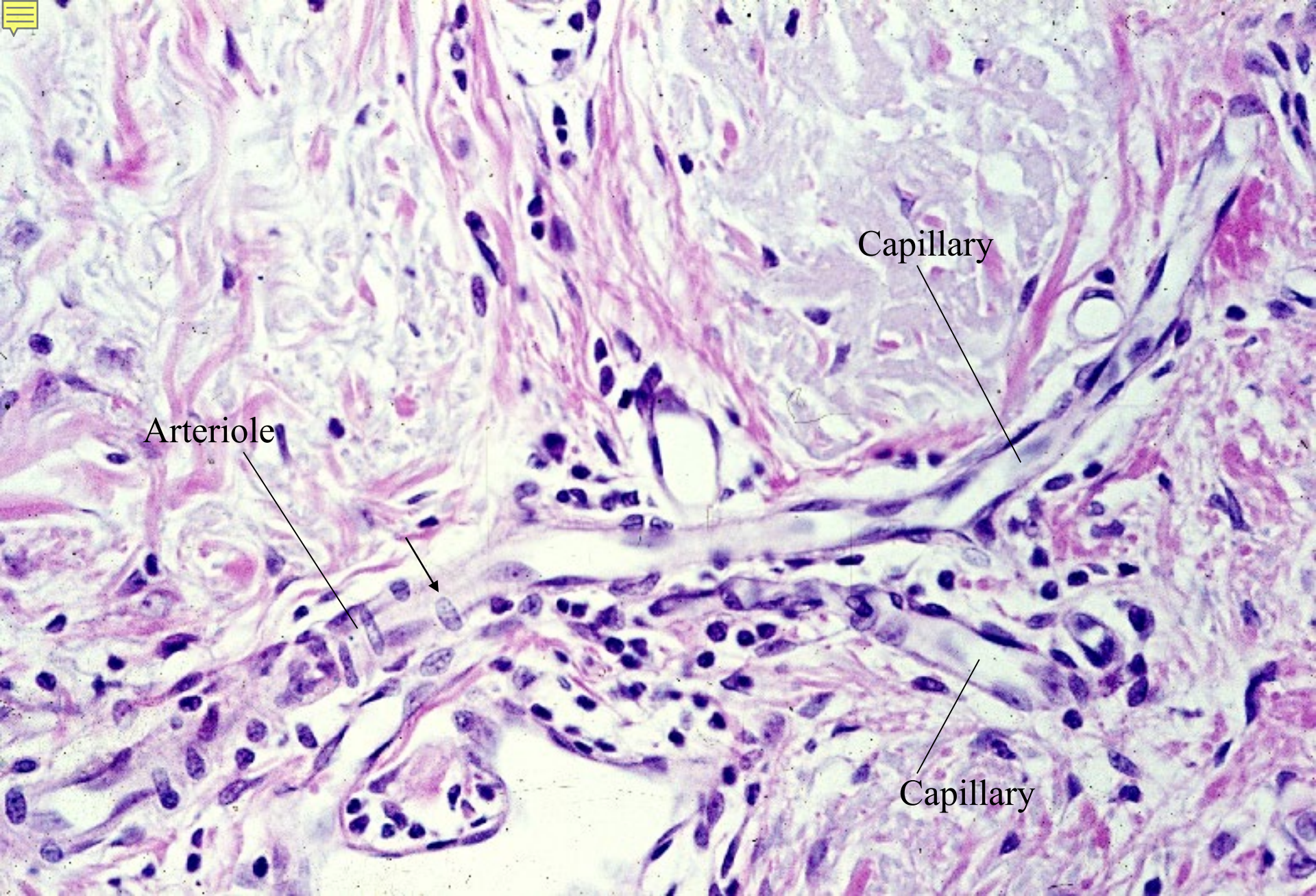
Vascular System

06-001

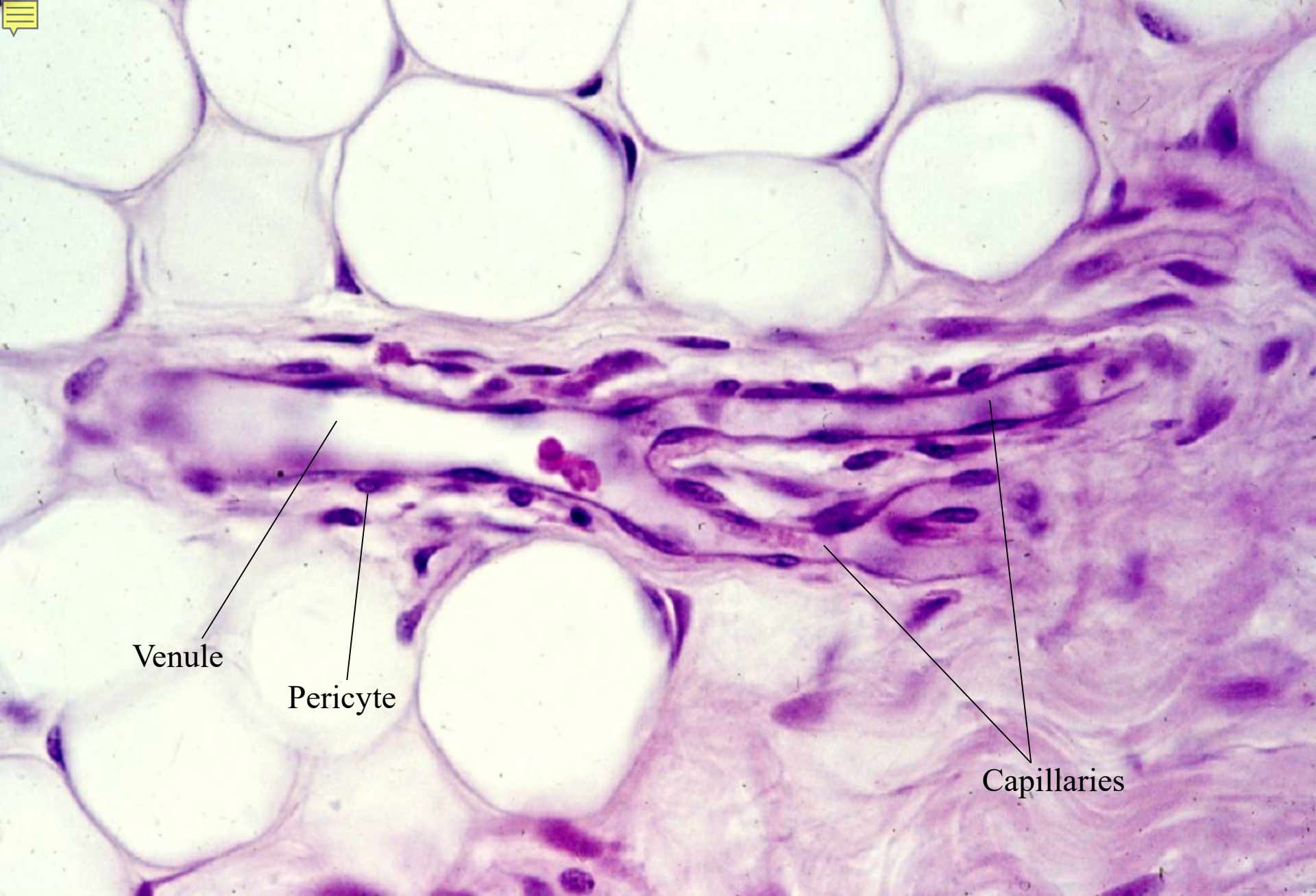
Blood Vessels



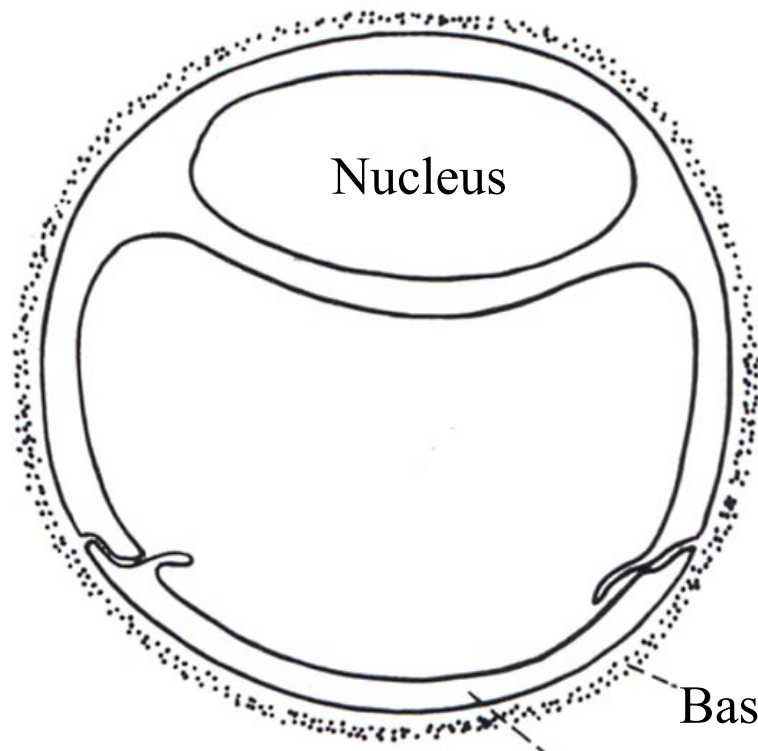
06-01. Capillary, longitudinal section. Human, H-E stain, x 125.



06-02. Arteriole and capillaries, longitudinal section. Human, H-E stain, x 100.



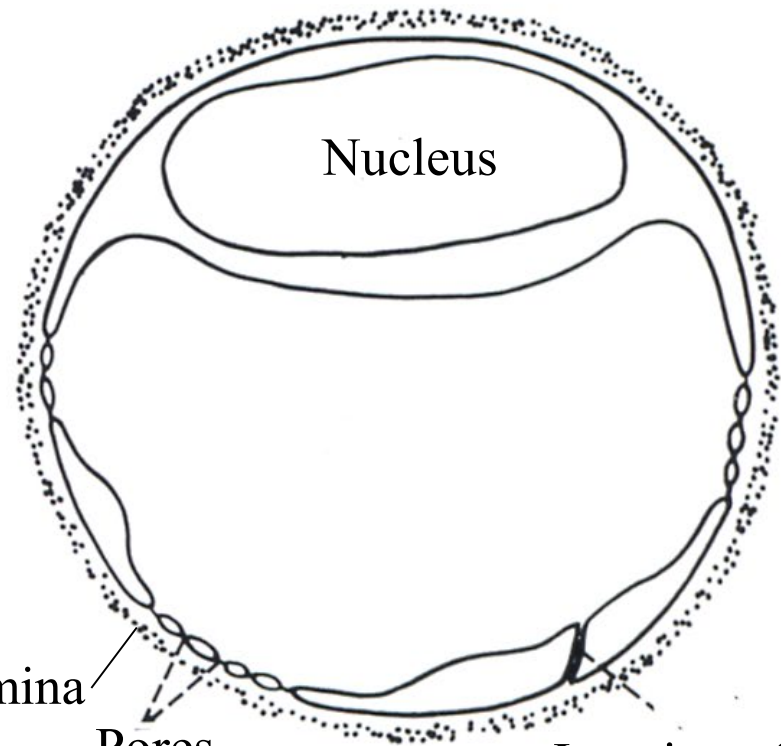
06-03. Capillaries and venule, longitudinal section. Human,
H-E stain, x 125



①

Cytoplasm of
endothelial cell

Basement lamina

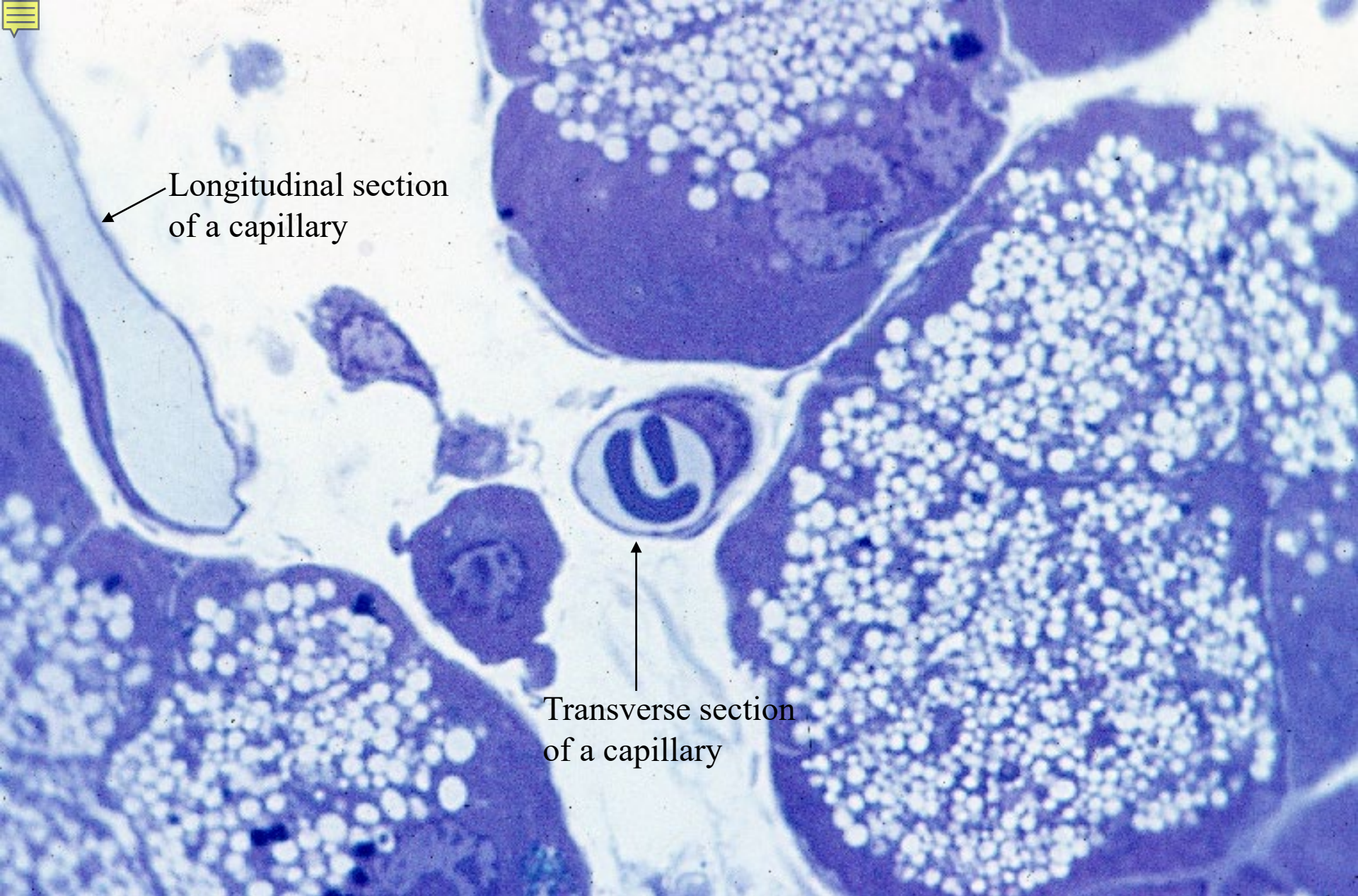


②

Pores

Junction of
endothelial cells

06-04. Scheme showing the structure of capillaries

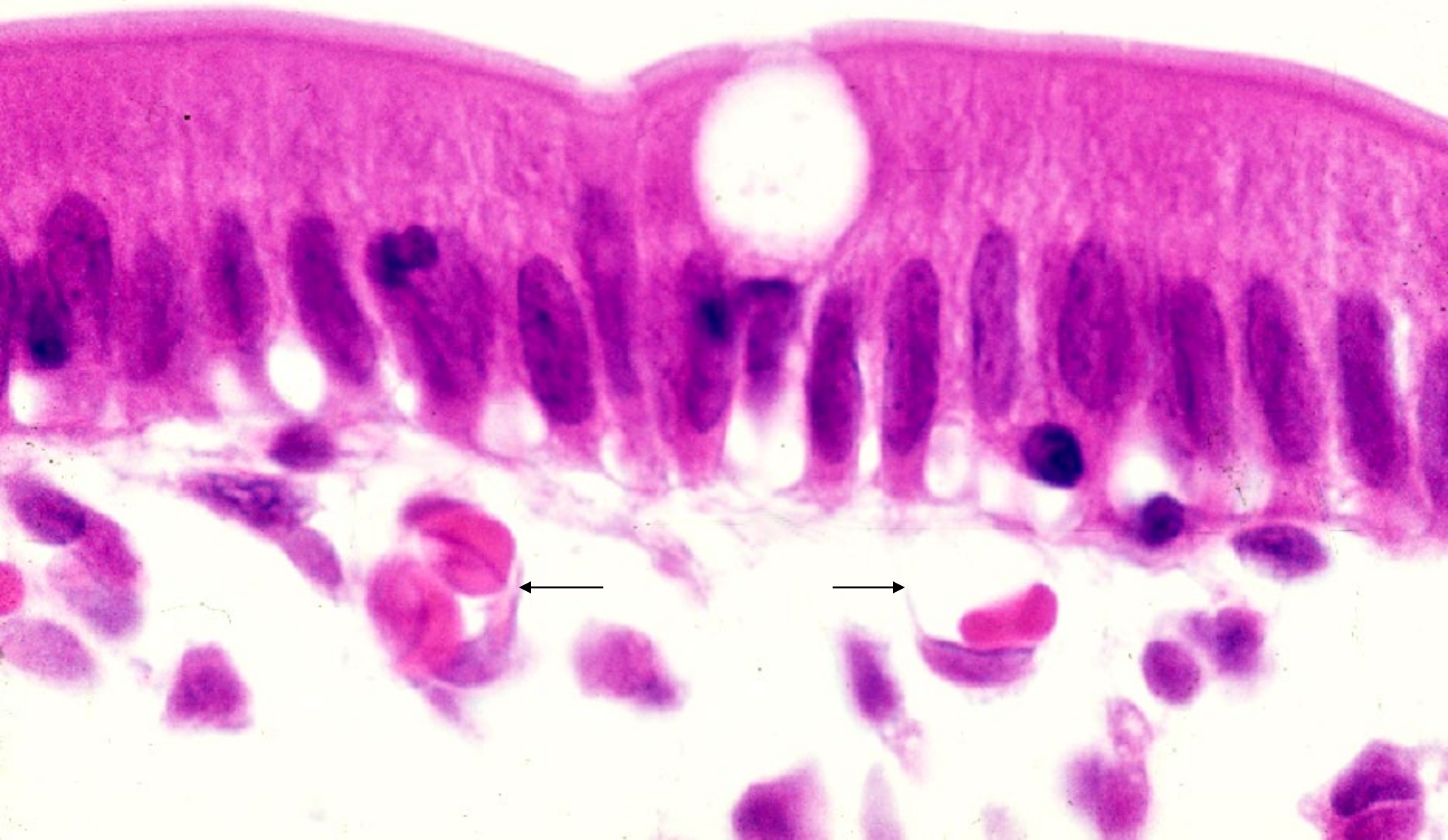


Longitudinal section
of a capillary

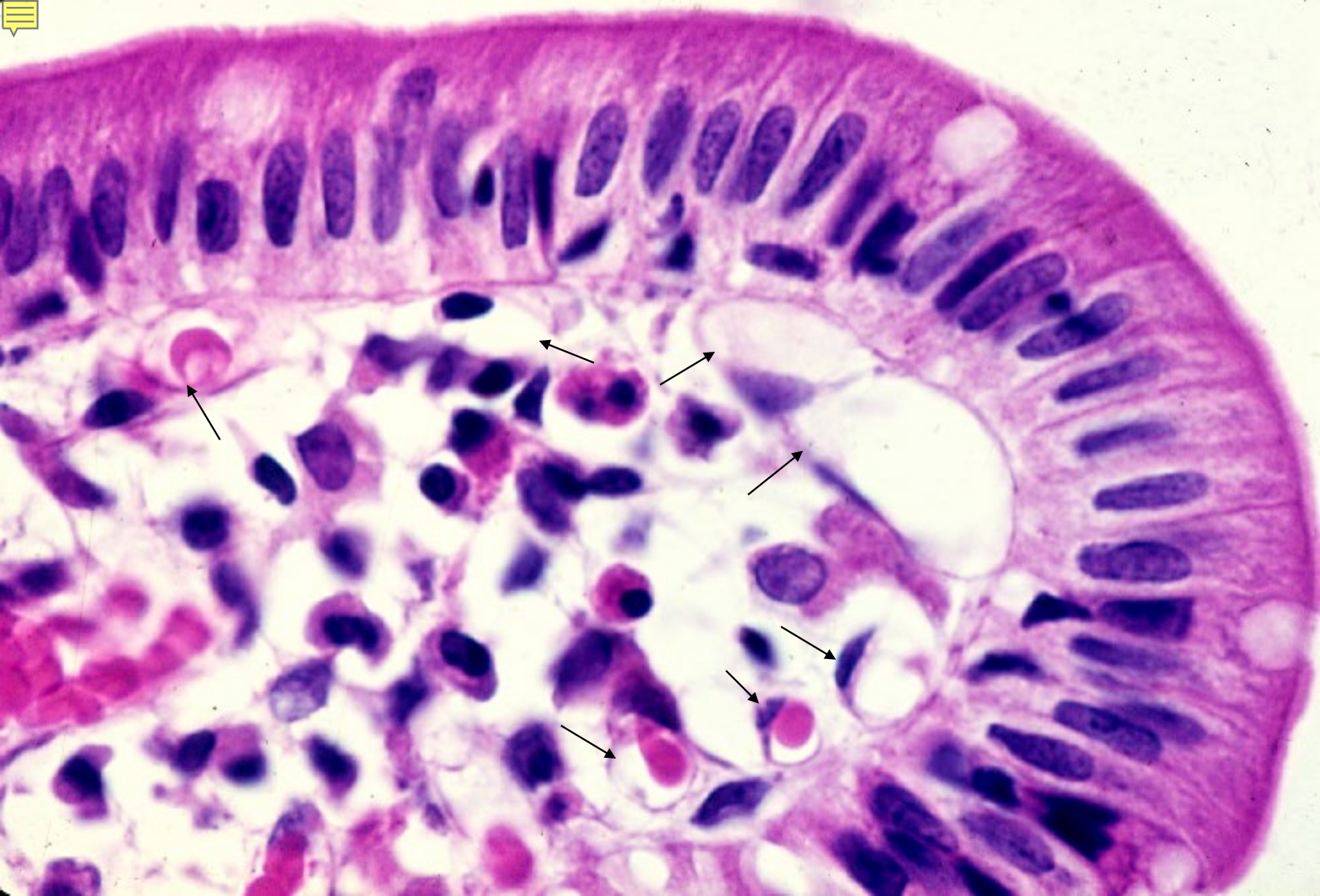
Transverse section
of a capillary

06-05. Capillaries, longitudinal and transverse sections.

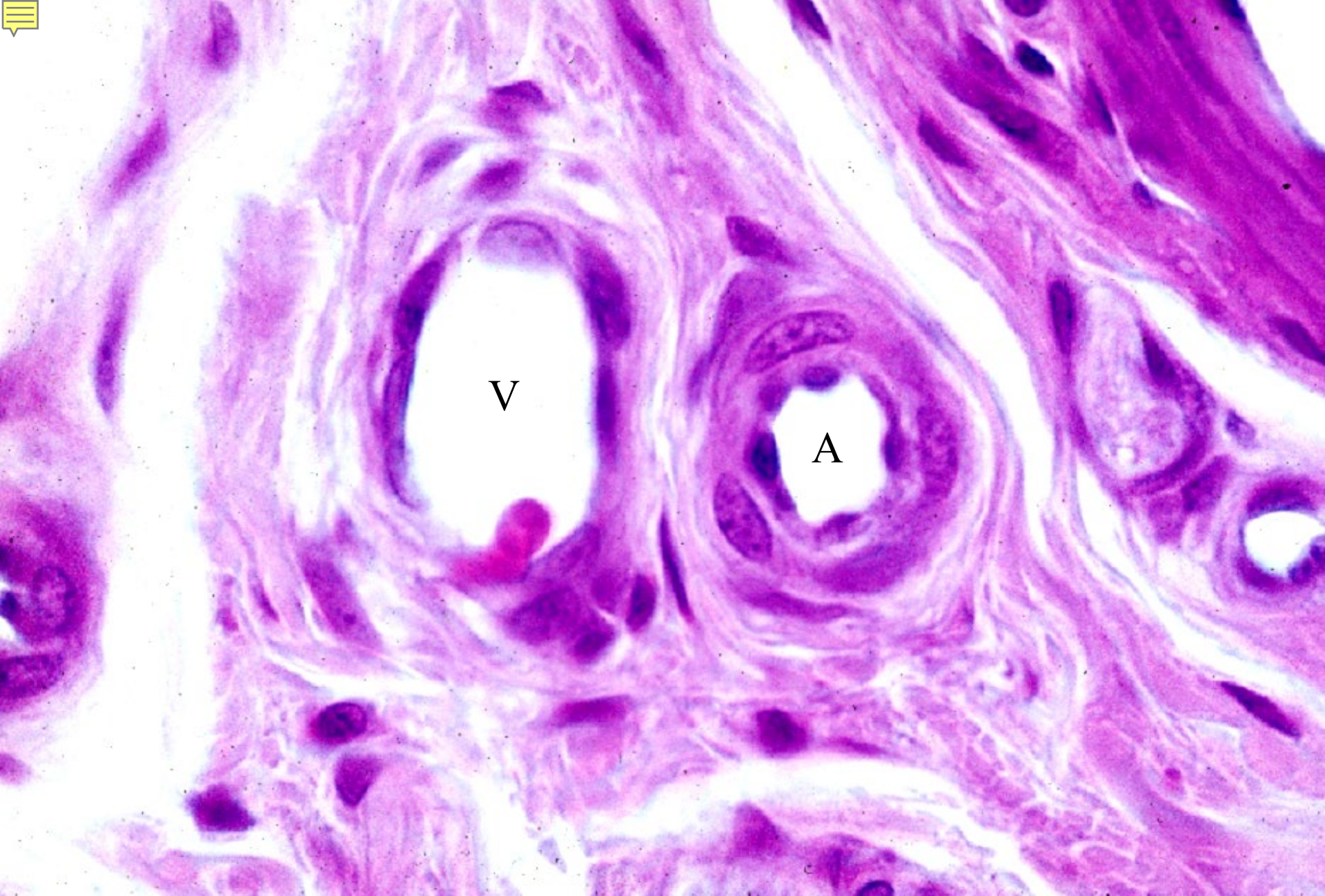
Rat, epon section, toluidinblue stain, x 400.



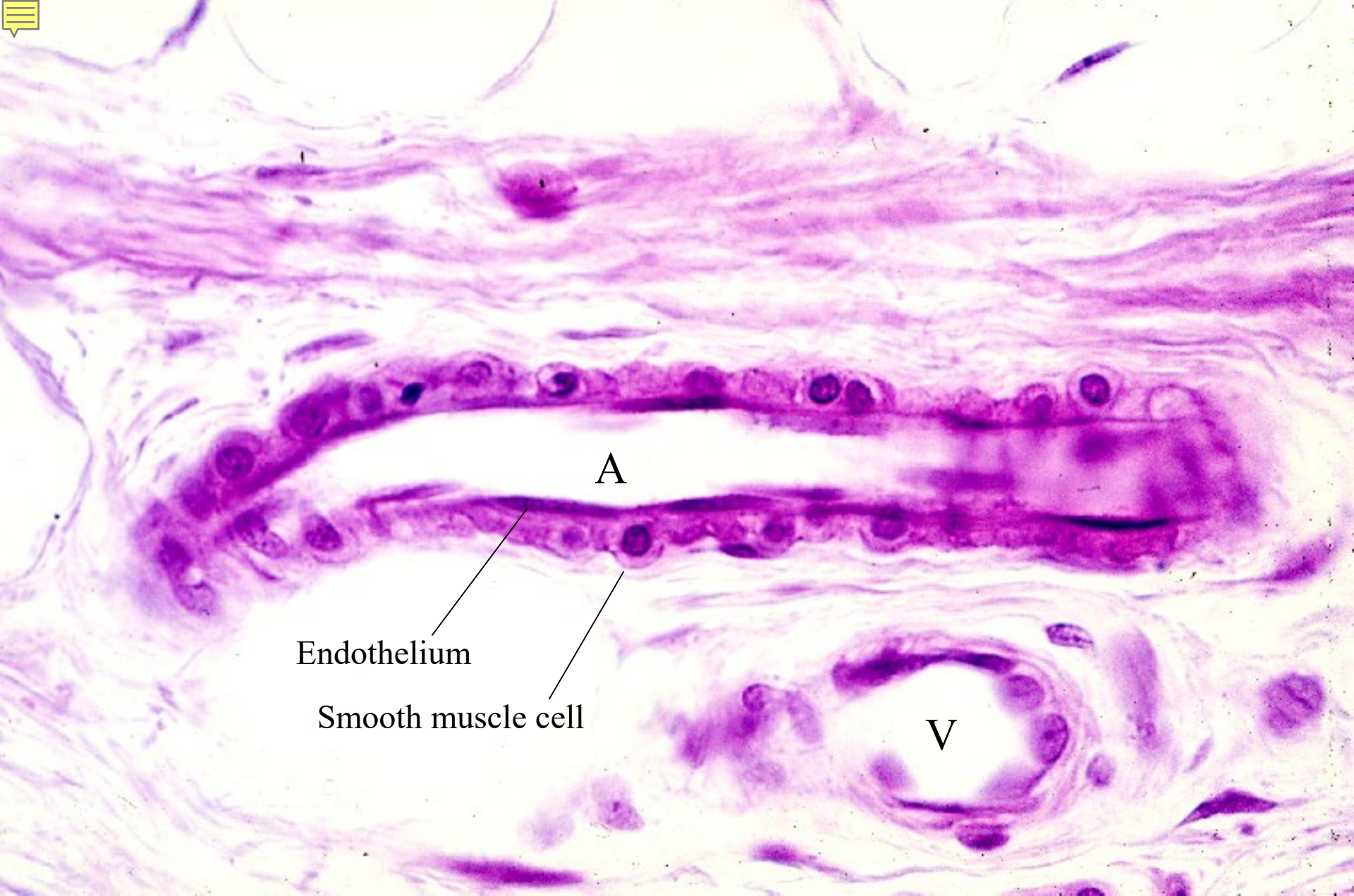
06-06. Capillaries, transverse section. Human, H-E stain, x 400.



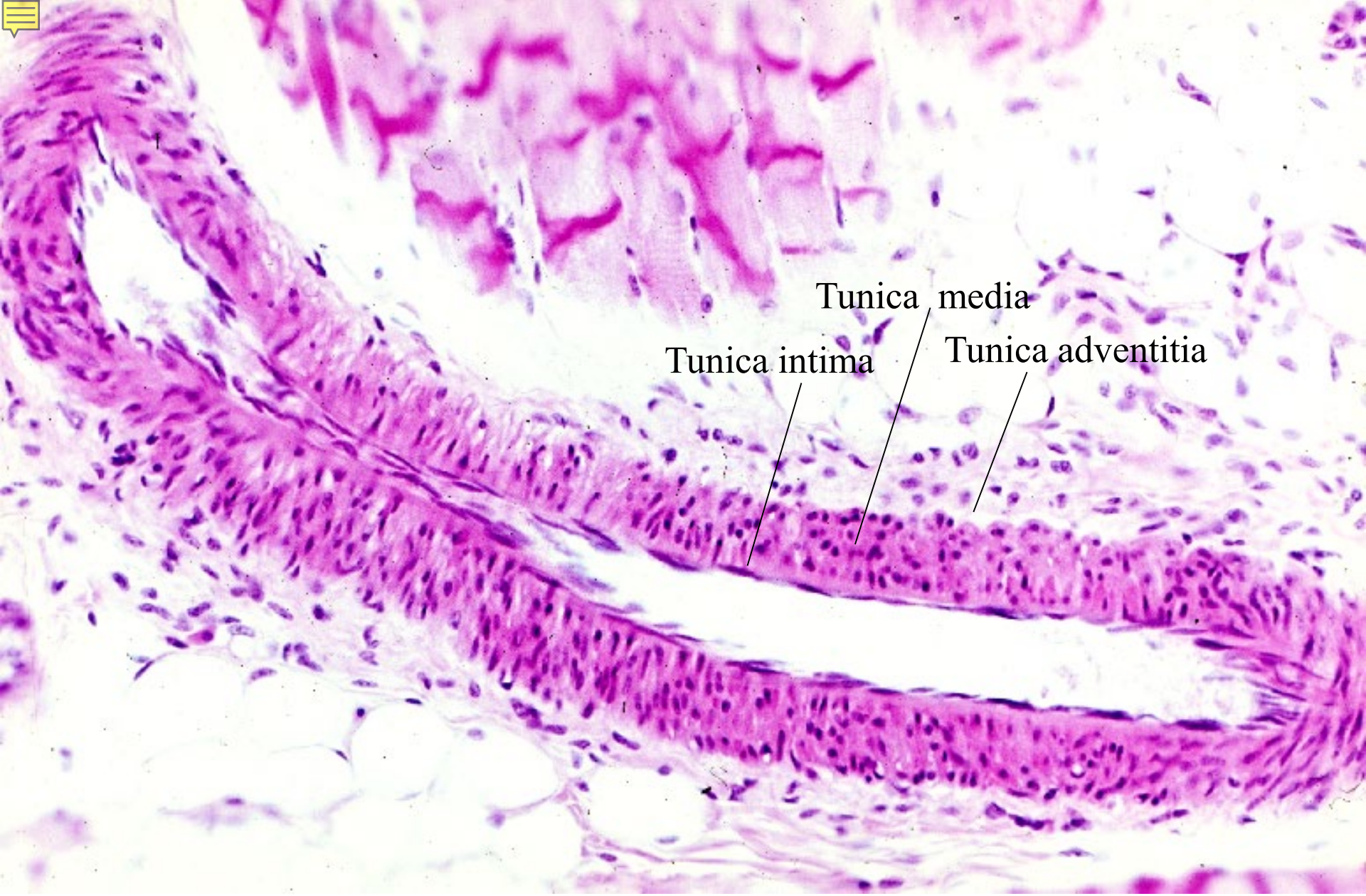
06-07. Capillaries. Human intestine, H-E stain, x 160.



06-08. Arteriole and venule, transverse section. Human, H-E stain, x 250.



06-09. Arteriole, longitudinal section. Human, H-E stain, x 160.



06-10. Small artery, longitudinal section. Human, H-E stain, x 64.

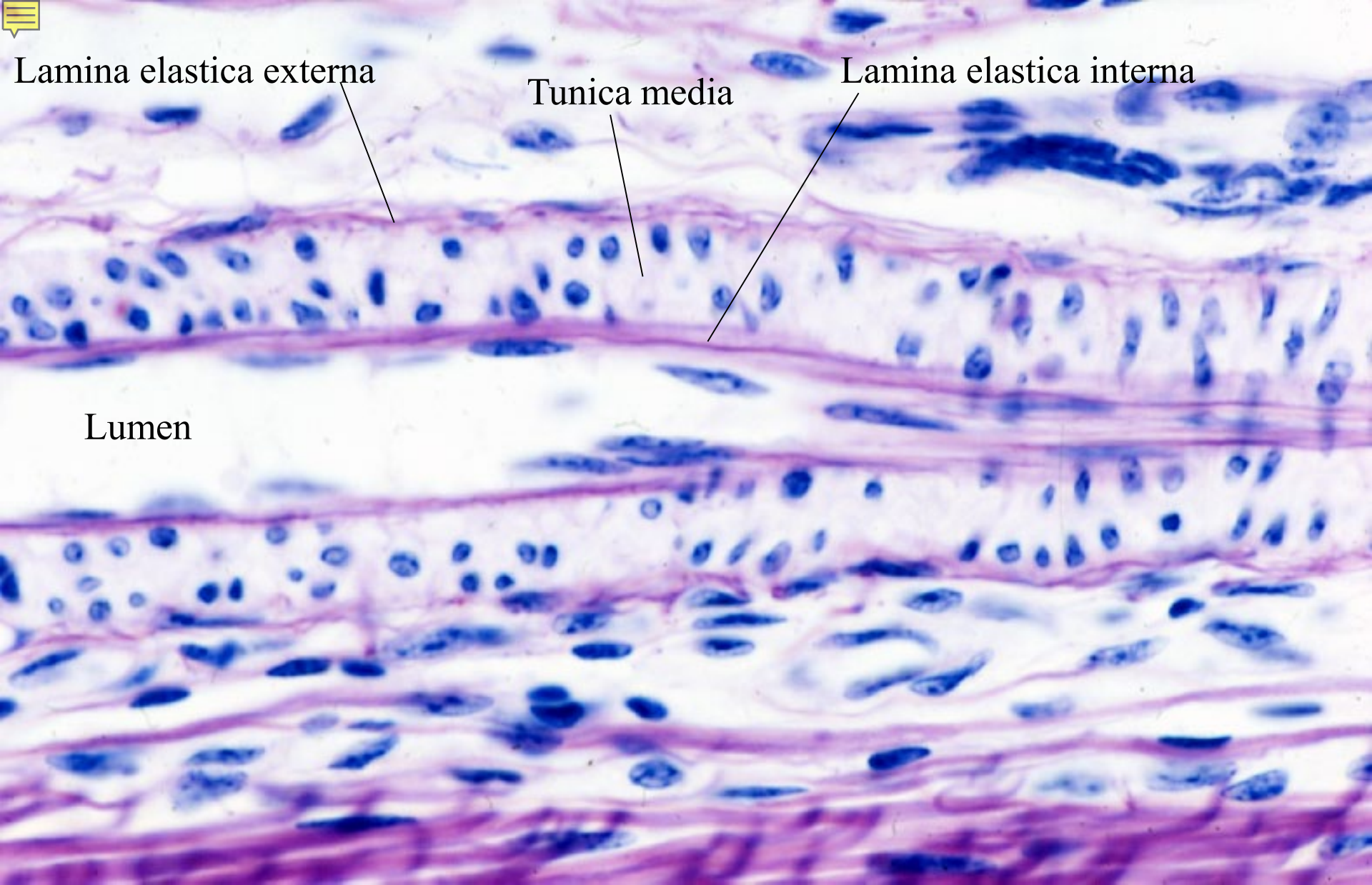


Lamina elastica externa

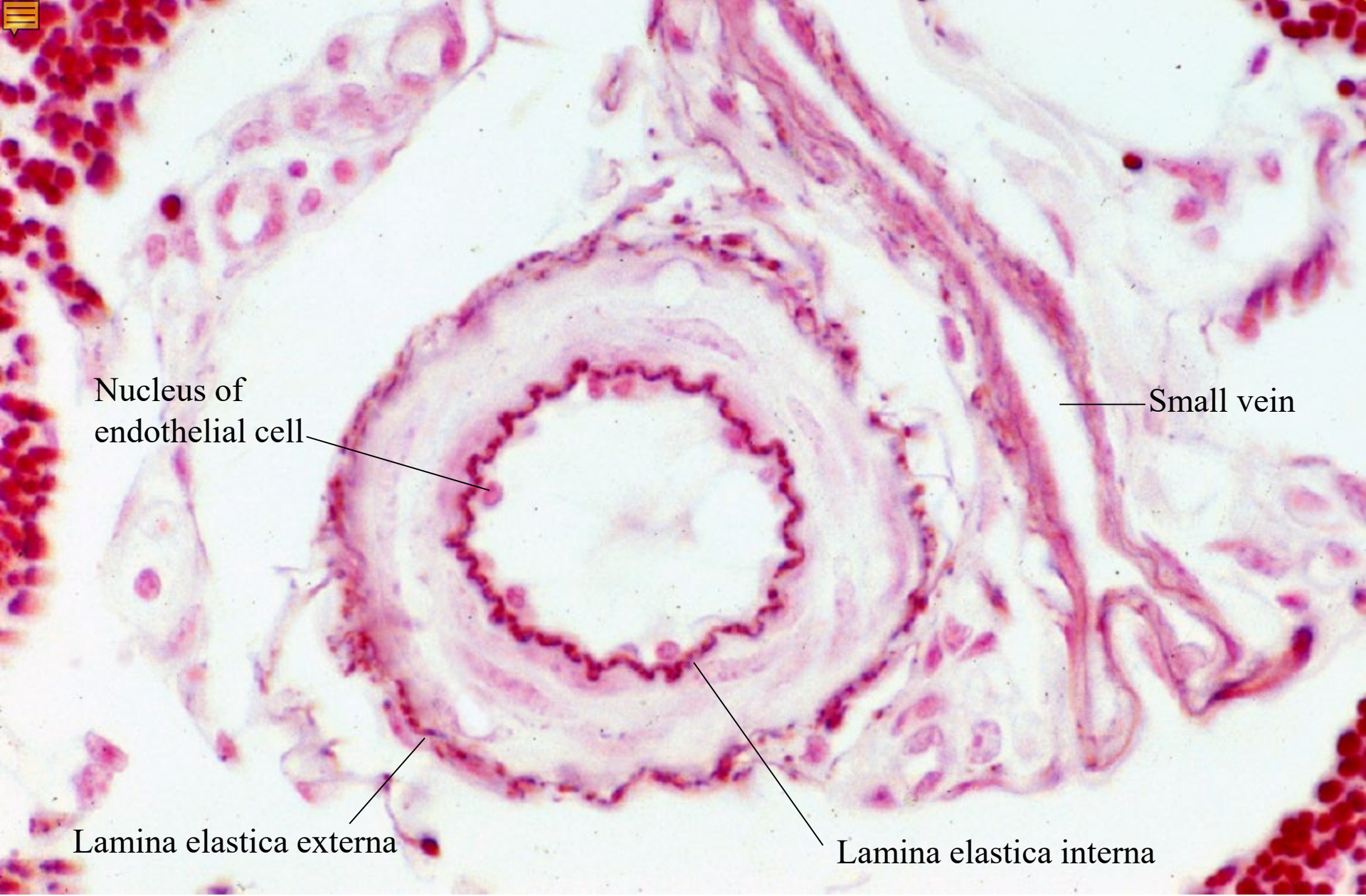
Tunica media

Lamina elastica interna

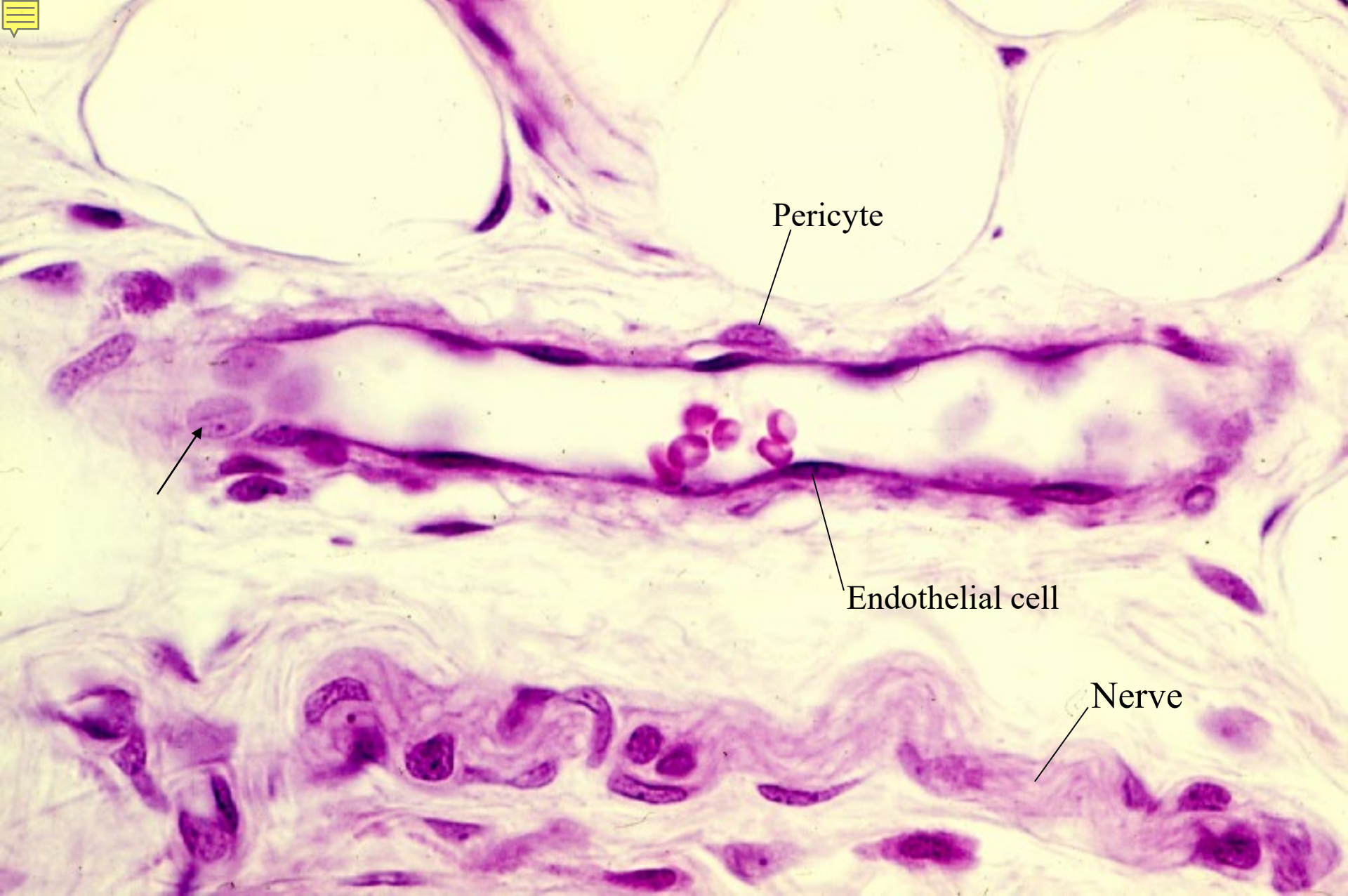
Lumen



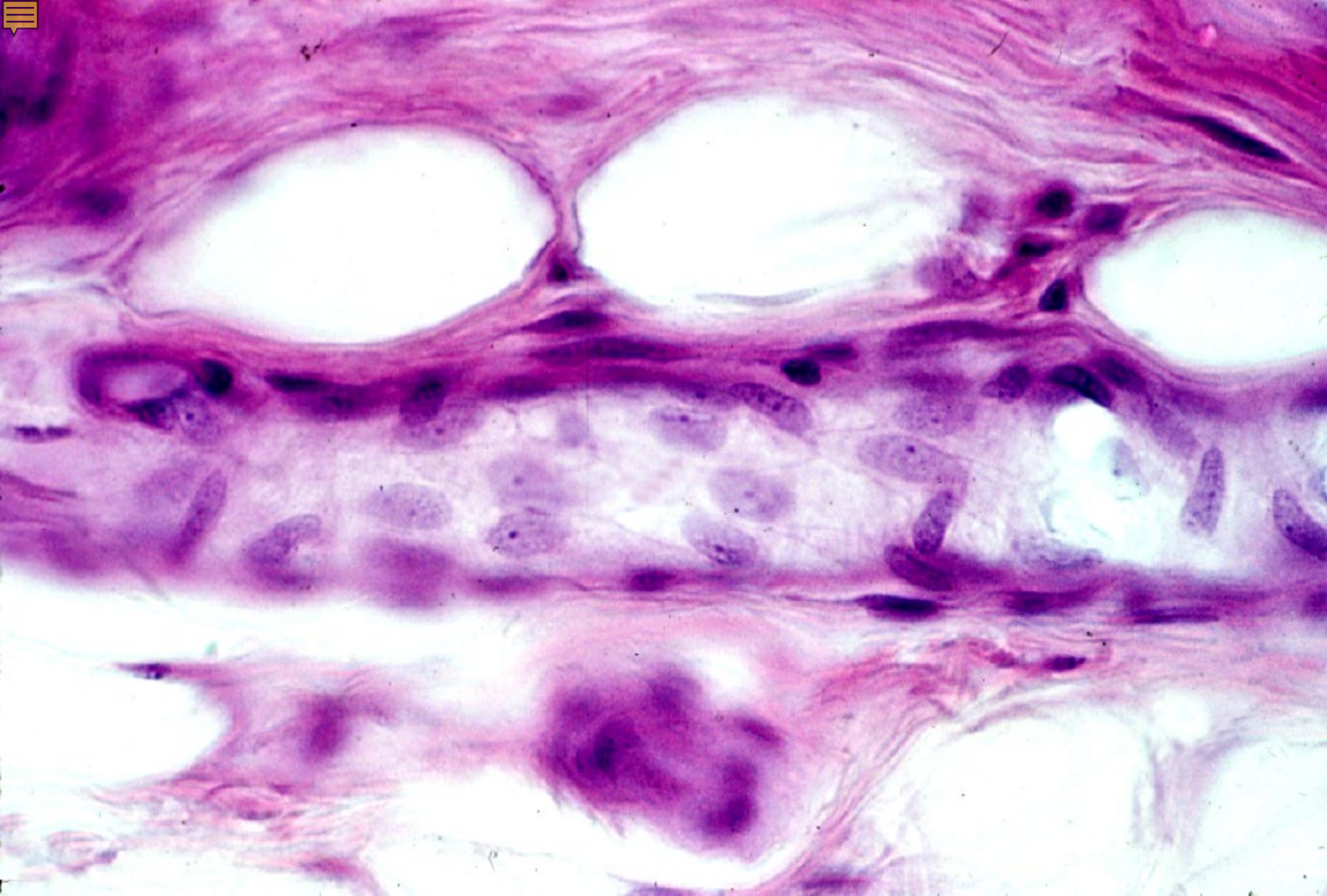
06-11. Small artery, longitudinal section.
Bovine, resorcin-fuchsin and hematoxylin stain. x 160.



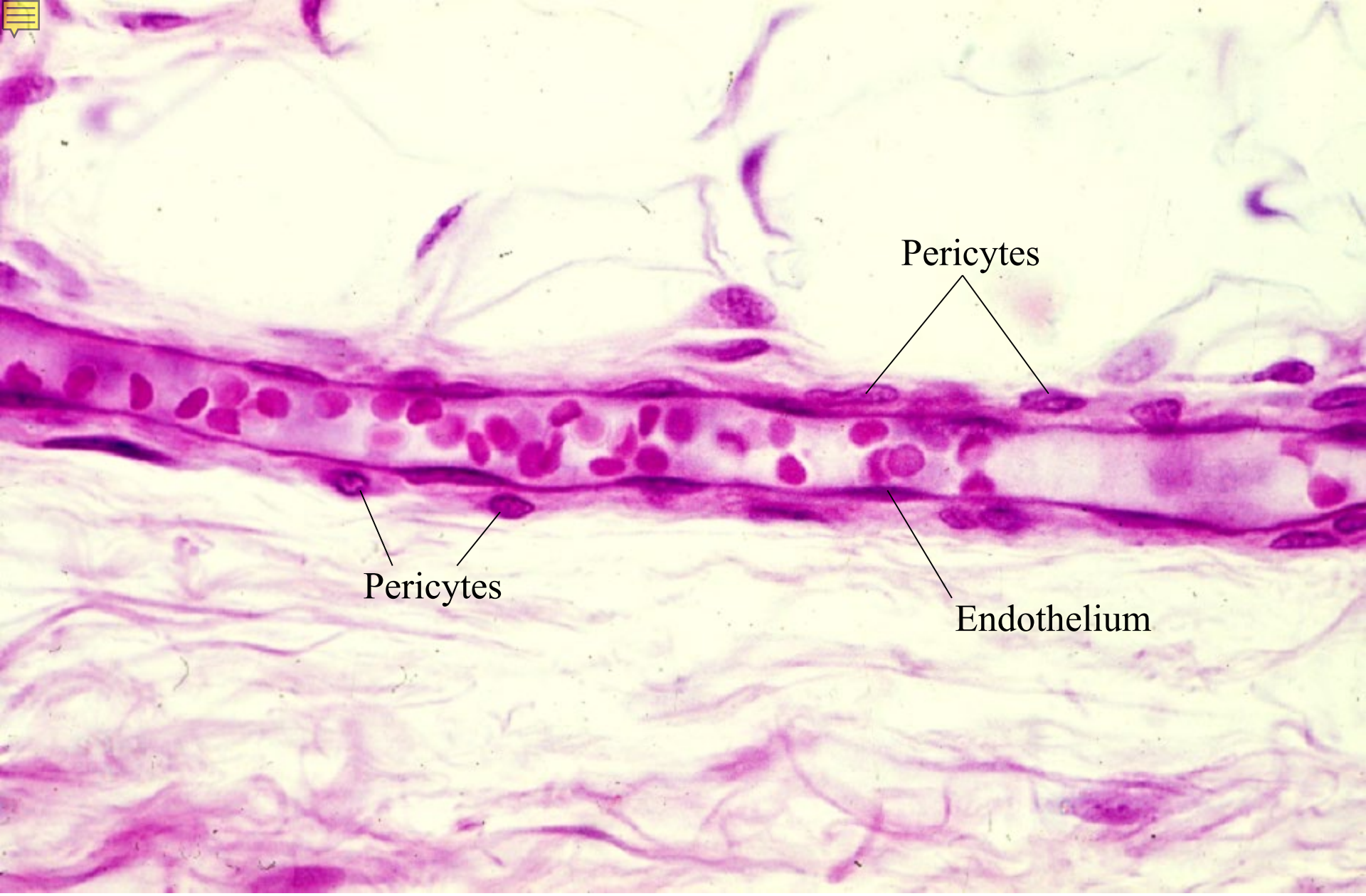
06-12. Small artery, transverse section.
Bovine, orcein and Kern-echtrot stain, x 160.



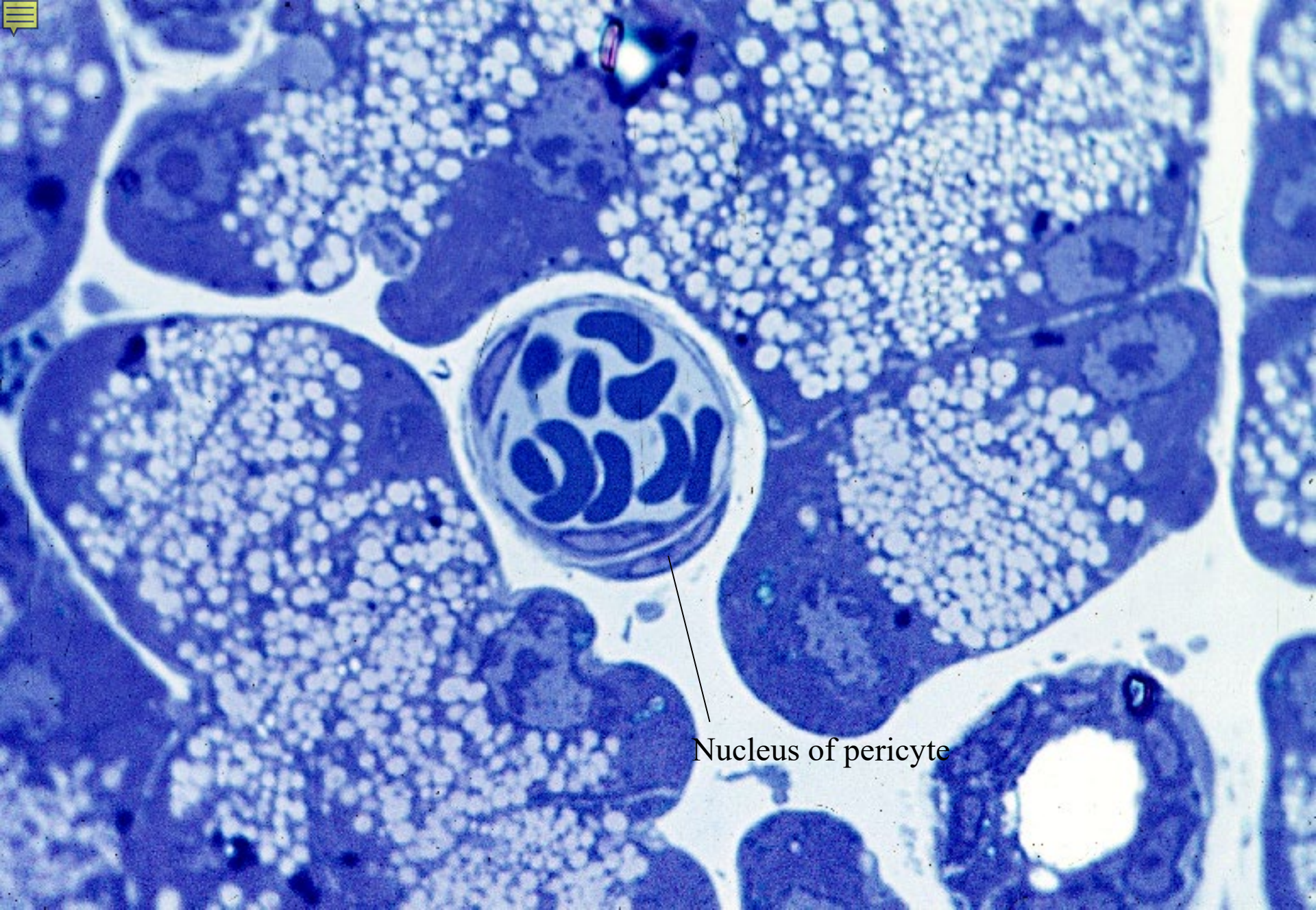
06-13. Venule, longitudinal section. Human, H-E stain, x 160.



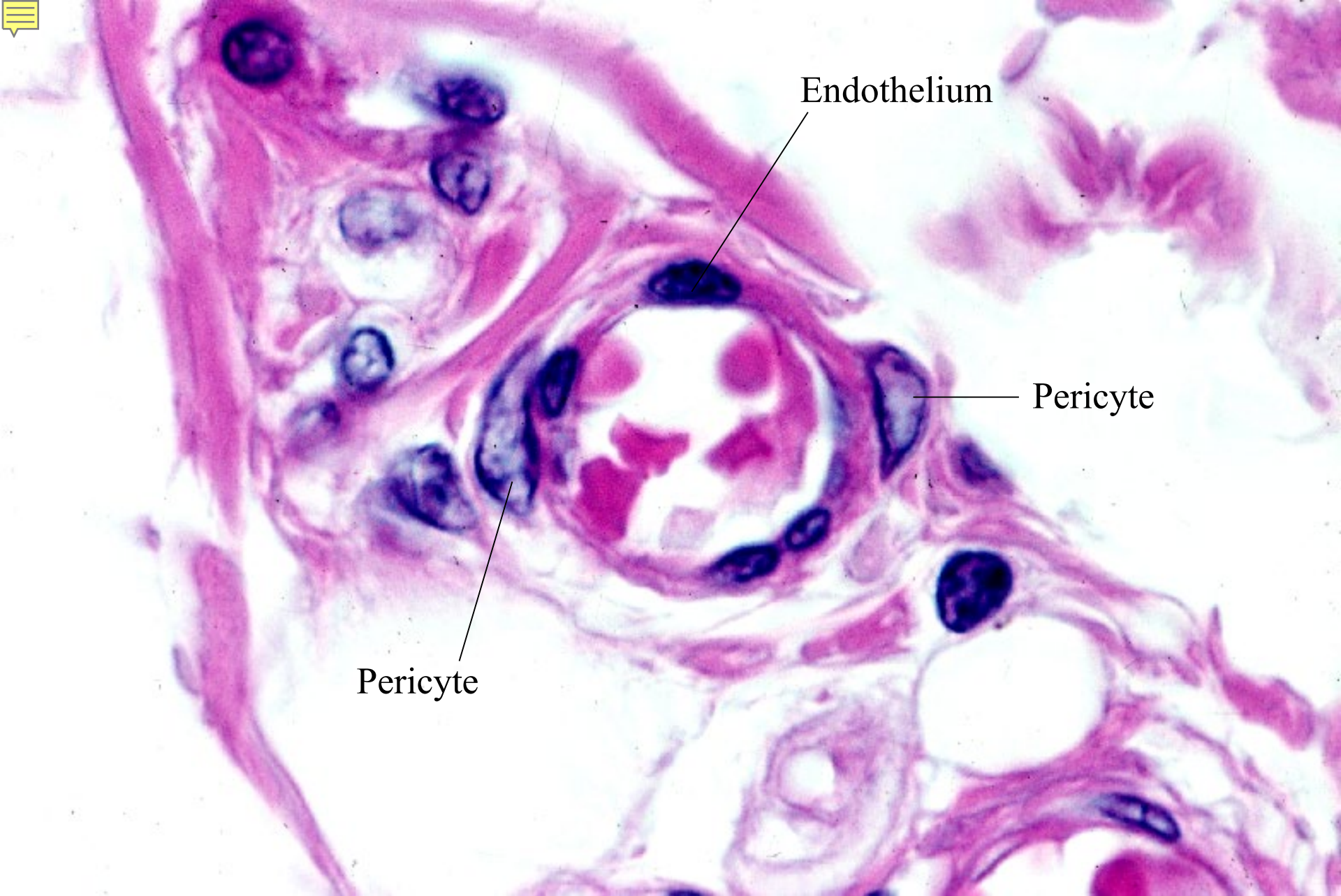06-14. Venule, longitudinal section, endothelial cells. Human, H-E stain, x 160.



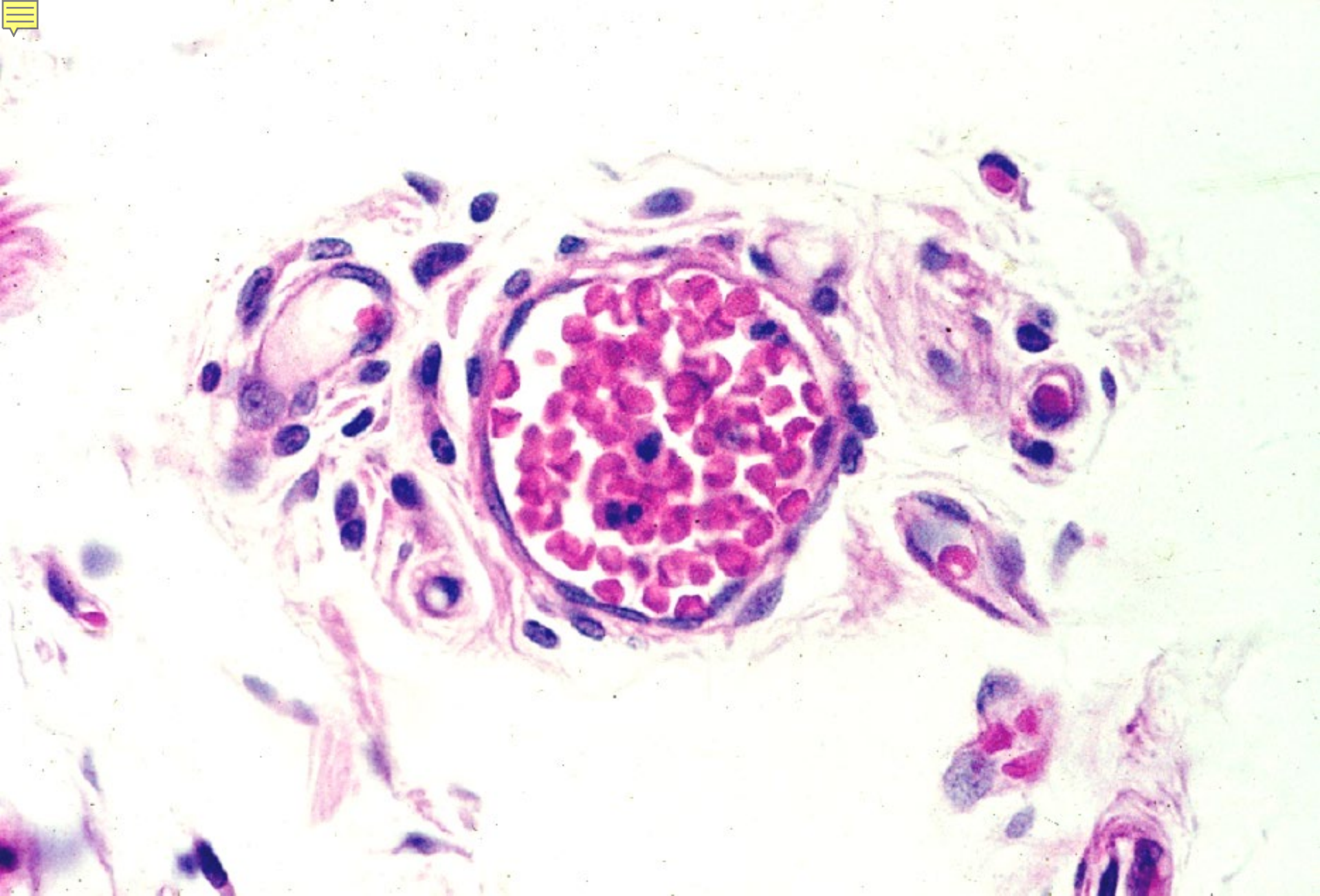
06-15. Venule, longitudinal section. Human, H-E stain, x 160.



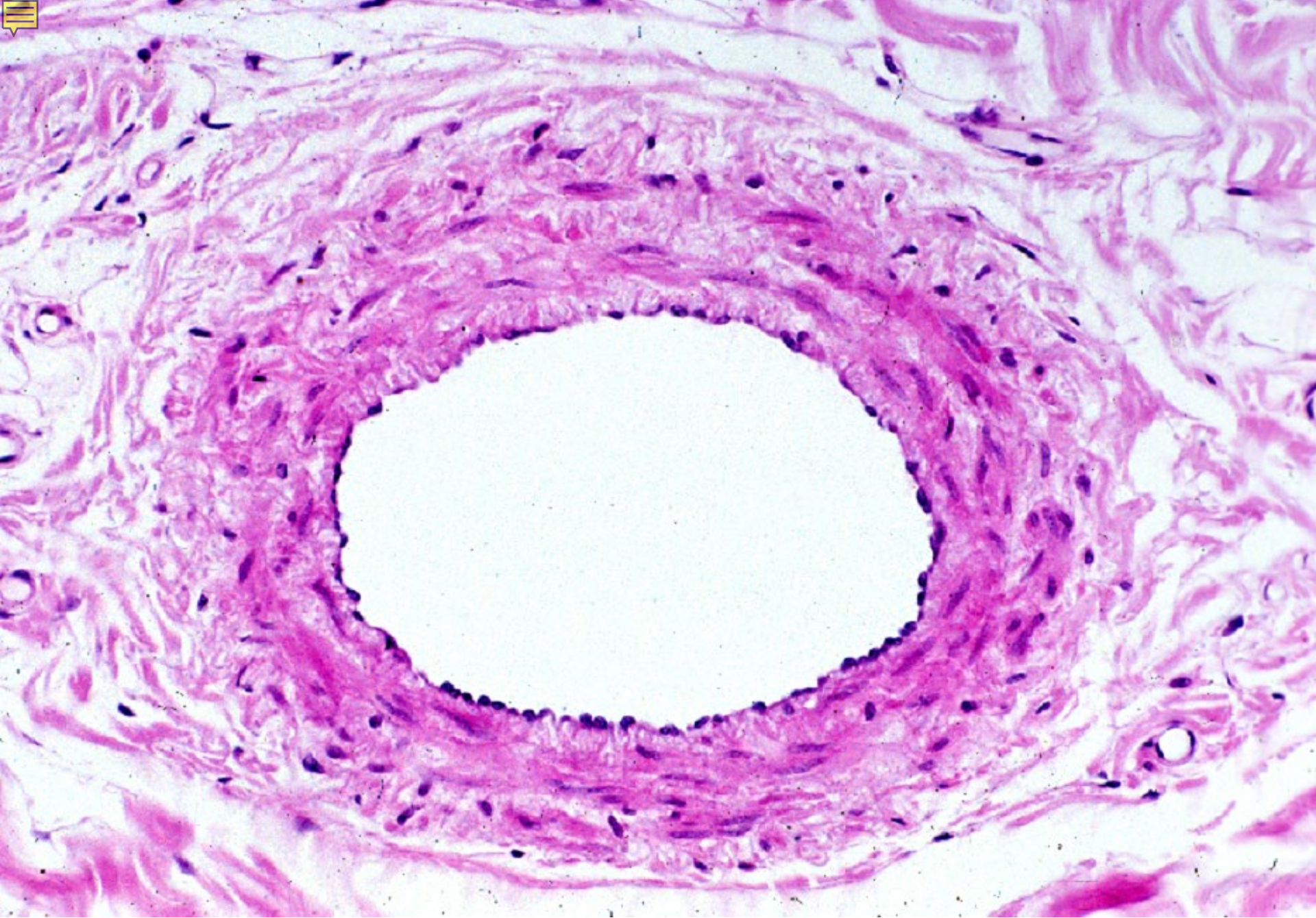
06-16. Venule, transverse section. Rat, epon section, toluidinblue stain, x 400.



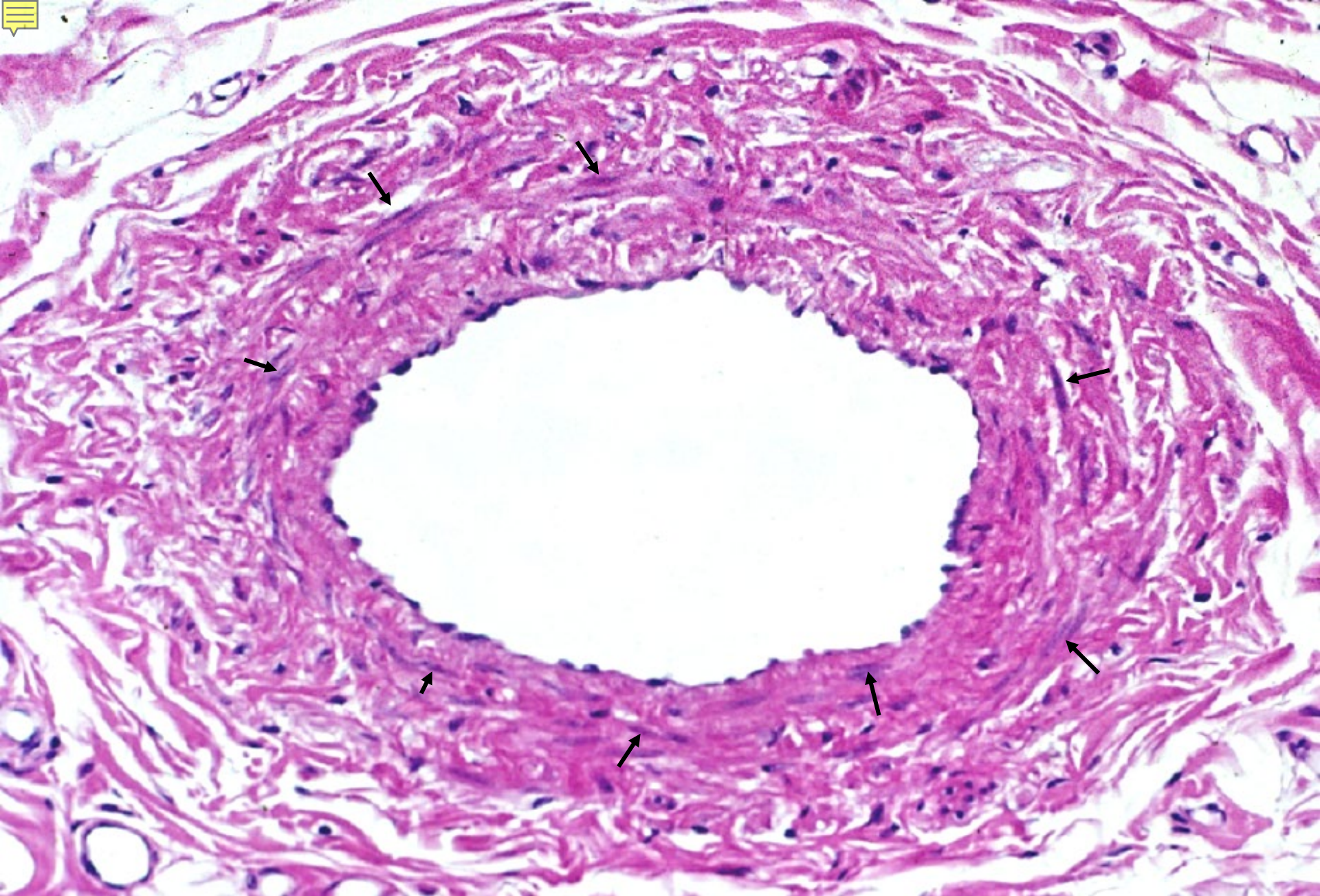
06-17. Small vein, transverse section. Human, H-E stain, x 400.



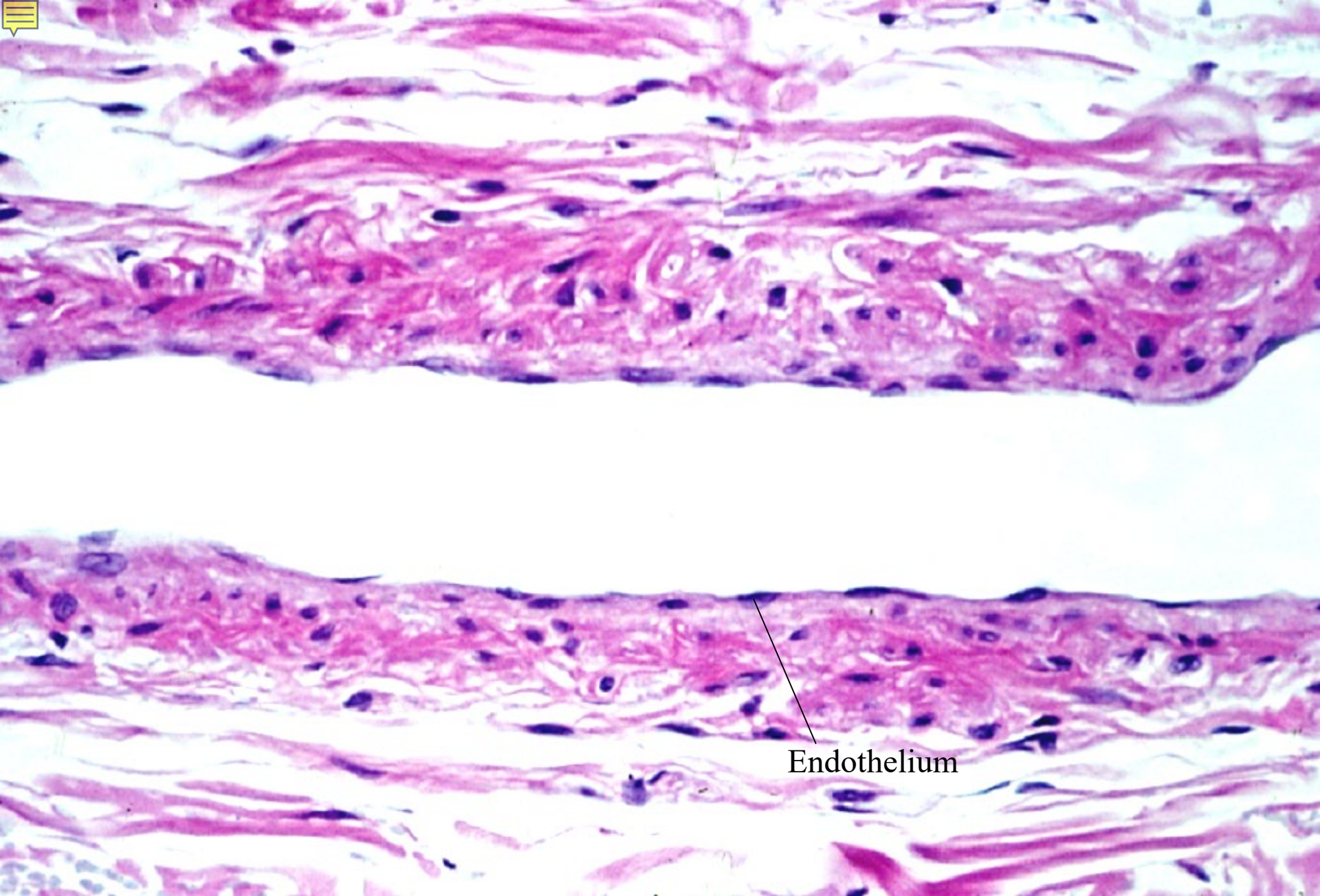
06-18. Small vein, transverse section. Human, H-E stain, x 160.



06-19. Small vein, transverse section. Human, H-E stain, x 64.



06-20. Small vein, transverse section. Human, H-E stain, x 64.

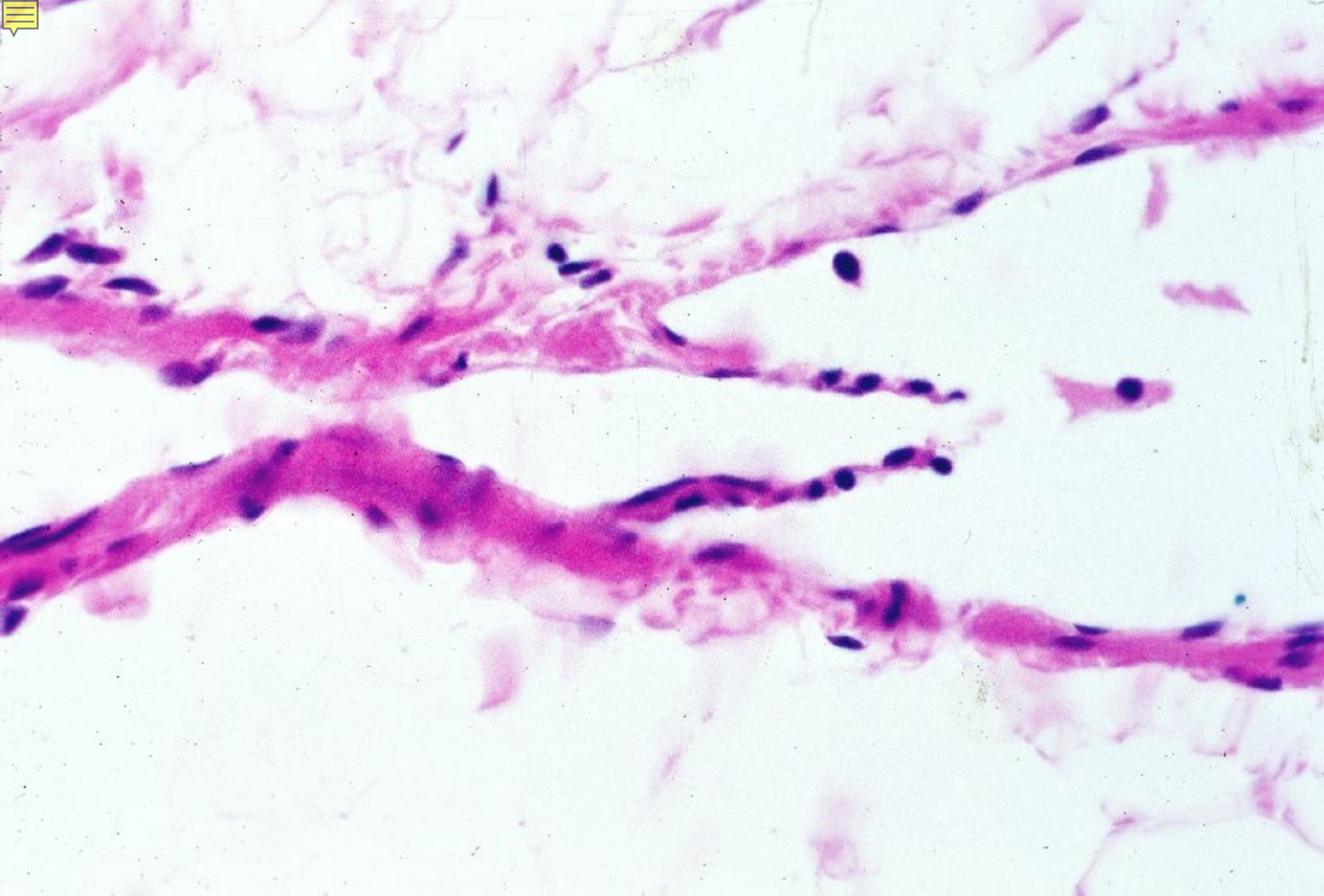


06-21. Small vein, longitudinal section. Human, H-E stain, x 100.

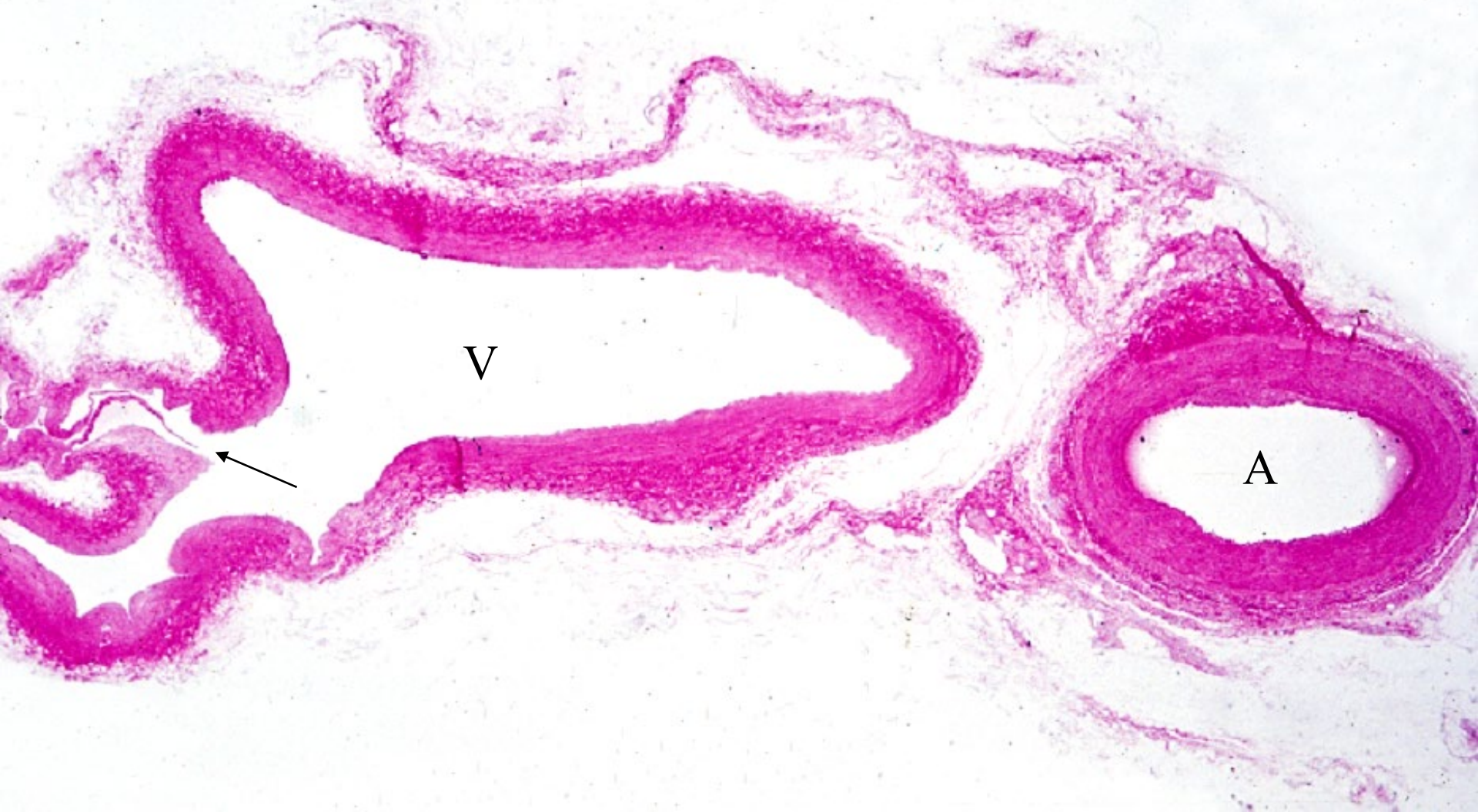

06-002

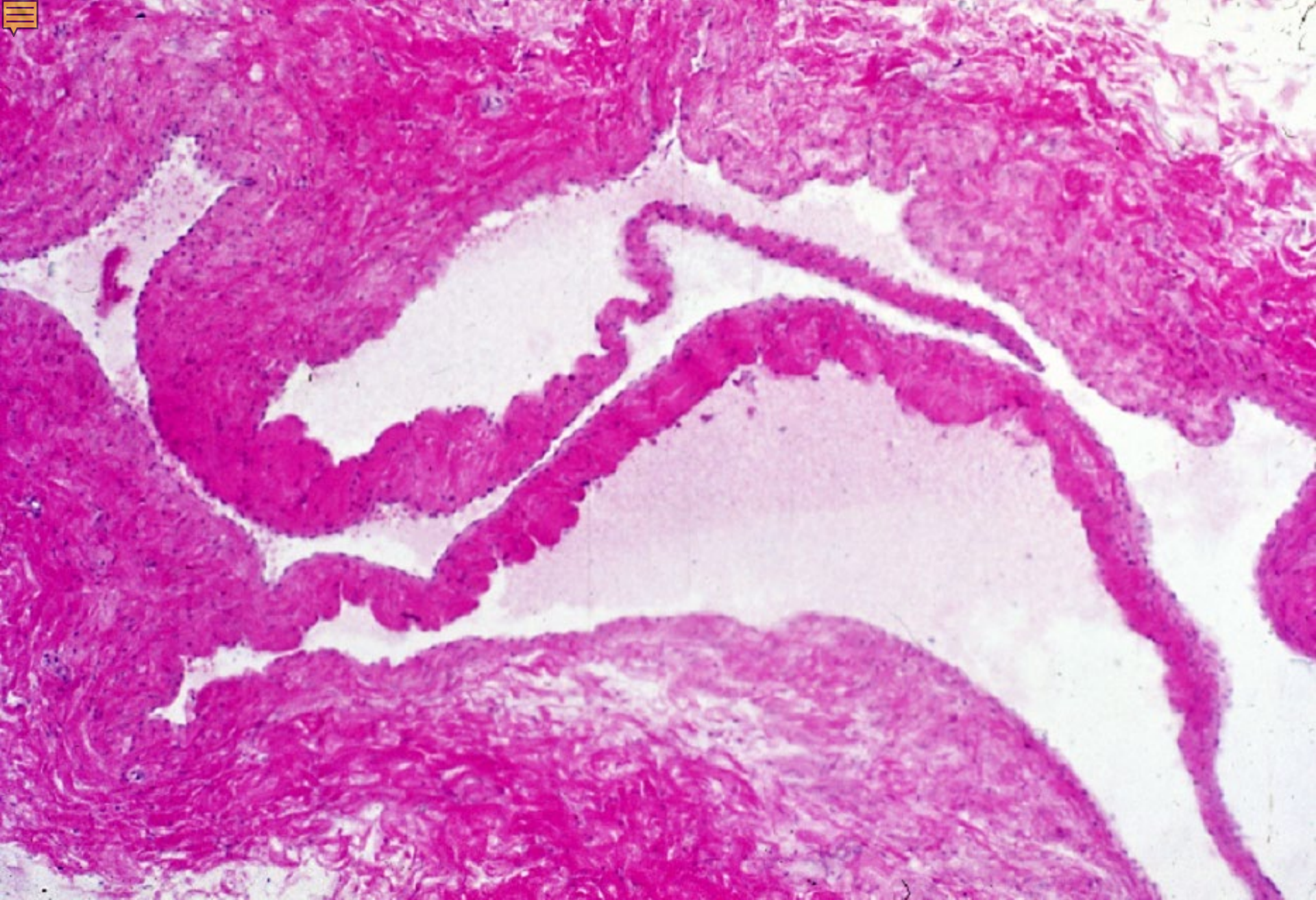
Valves of Veins



06-22.Valves of small vein. Monkey, H-E stain, x 160.



06-23. Valves of v. femoralis 1. Human, H-E stain, x 2.5.

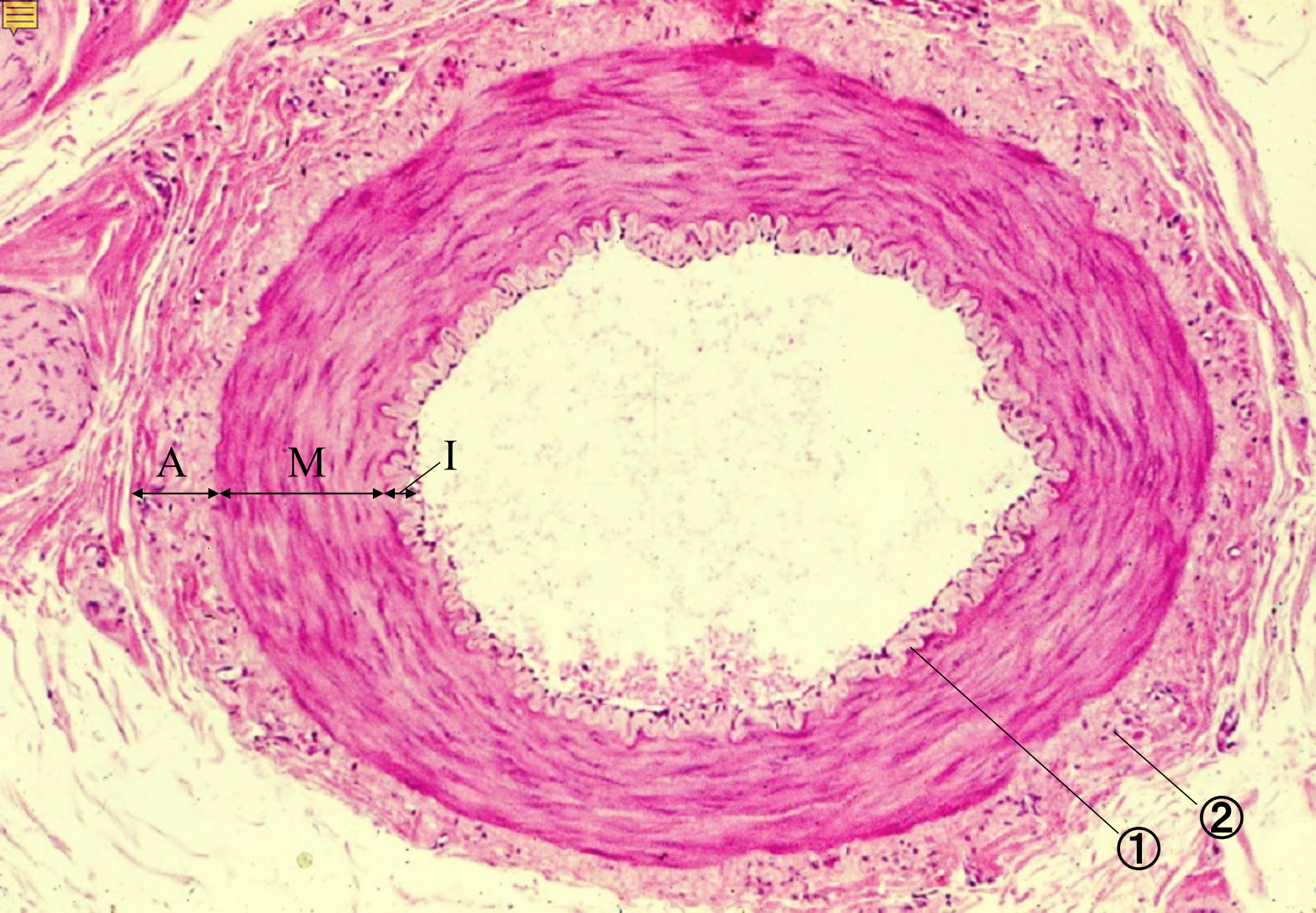


06-24. Valves of v. femoralis 2. Human, H-E stain, x 25.

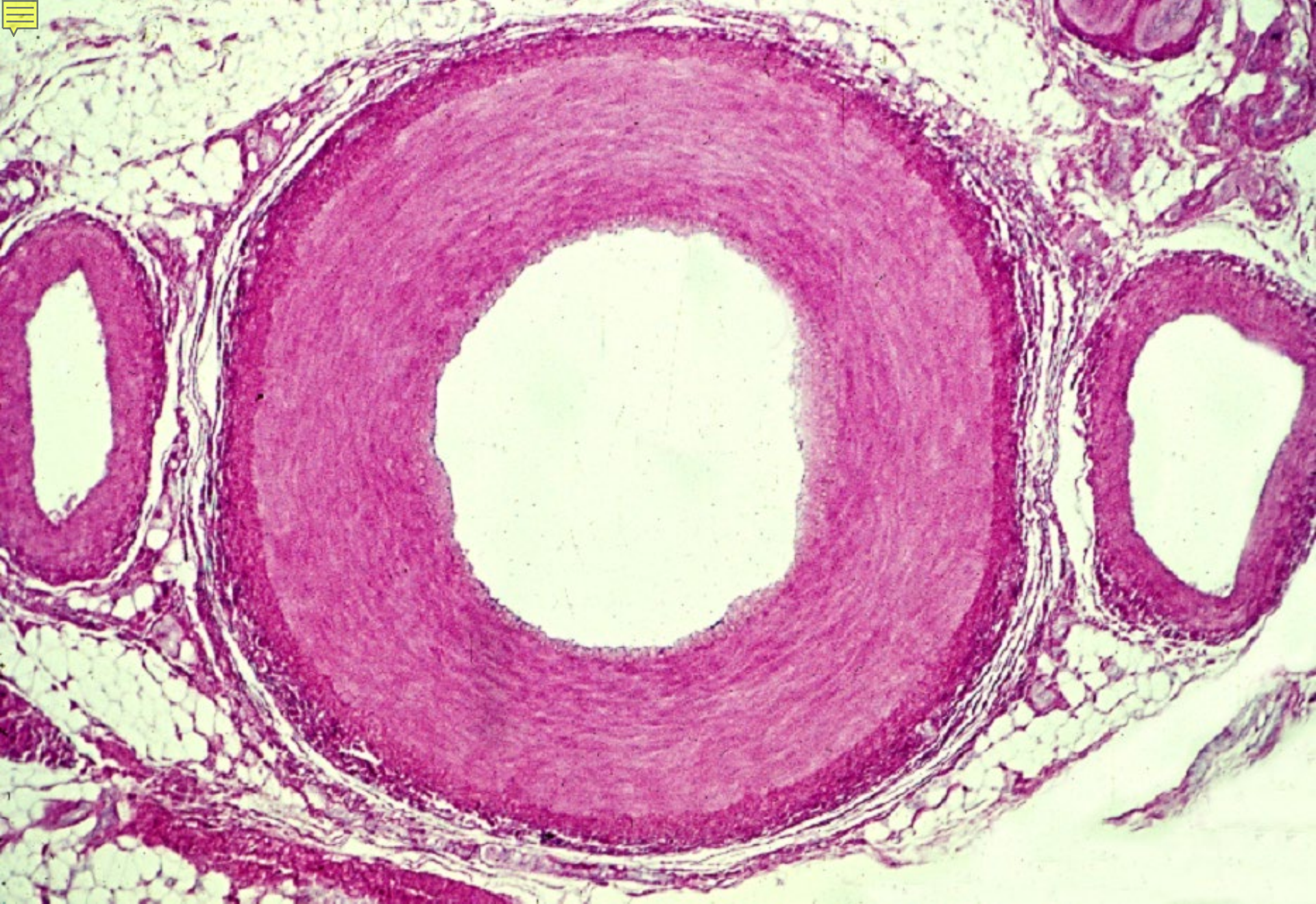


06-003

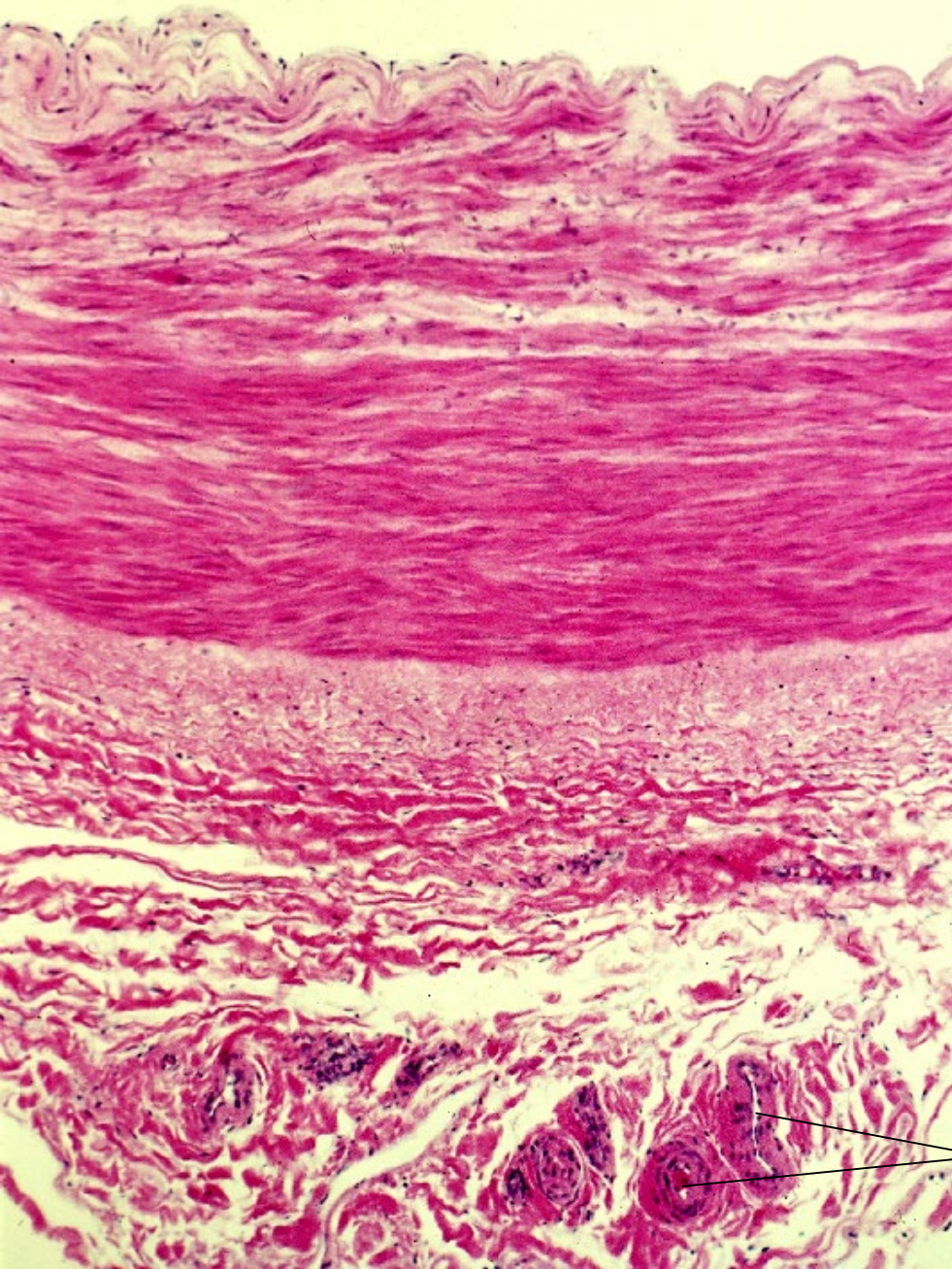
Arteries



06-25. Small artery, muscular type, transverse section. Monkey, H-E stain, x 30.



06-26. A. radialis, transverse section. Human, H-E stain, x10.



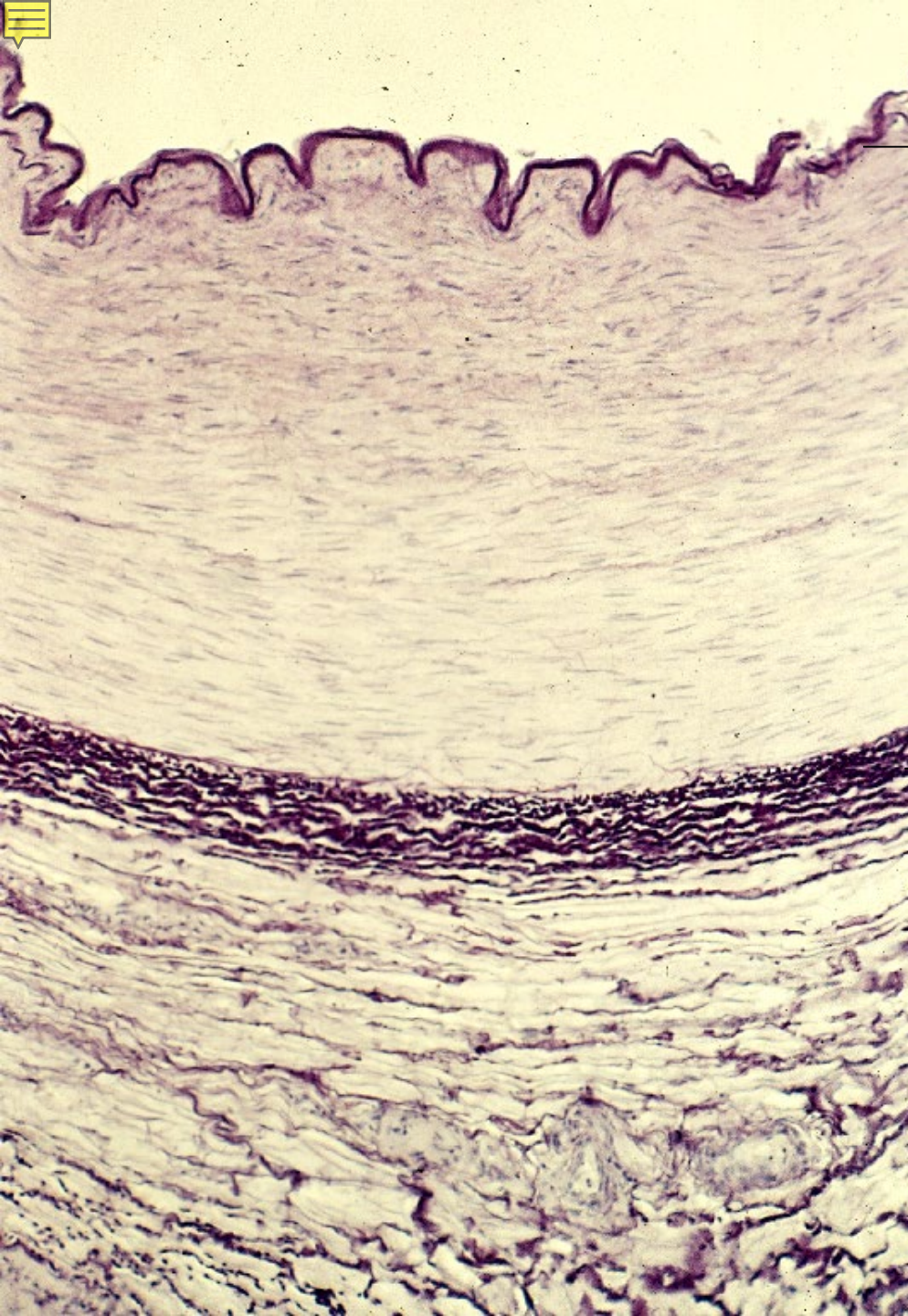
← Lamina elastica interna

↑ Tunica media

↓ Lamina elastica
externa

→ Vasa vasorum

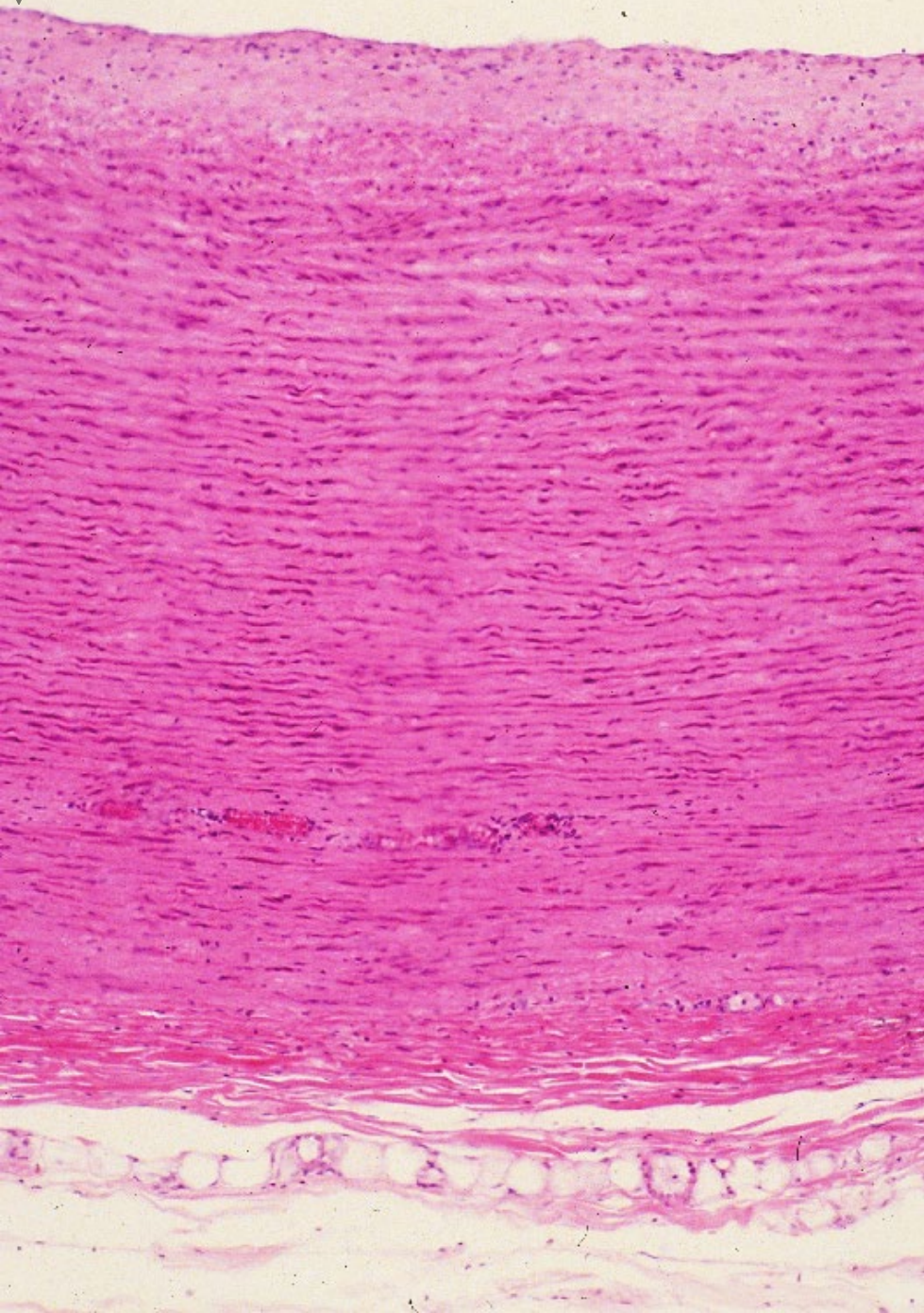
06-27.
A. femoralis,
transverse section 1.
Human,
H-E stain, x 30.



Lamina elastica interna

Lamina
elastica
externa

06-28.
A. femoralis,
transverse section 2.
Human,
resorcin-fuchsin stain,
x 30.




Tunica intima

Tunica media

Tunica adventitia

06-29.
Aorta,
transverse section 1.
Human,
H-E stain, x 25.



Tunica intima

Tunica media

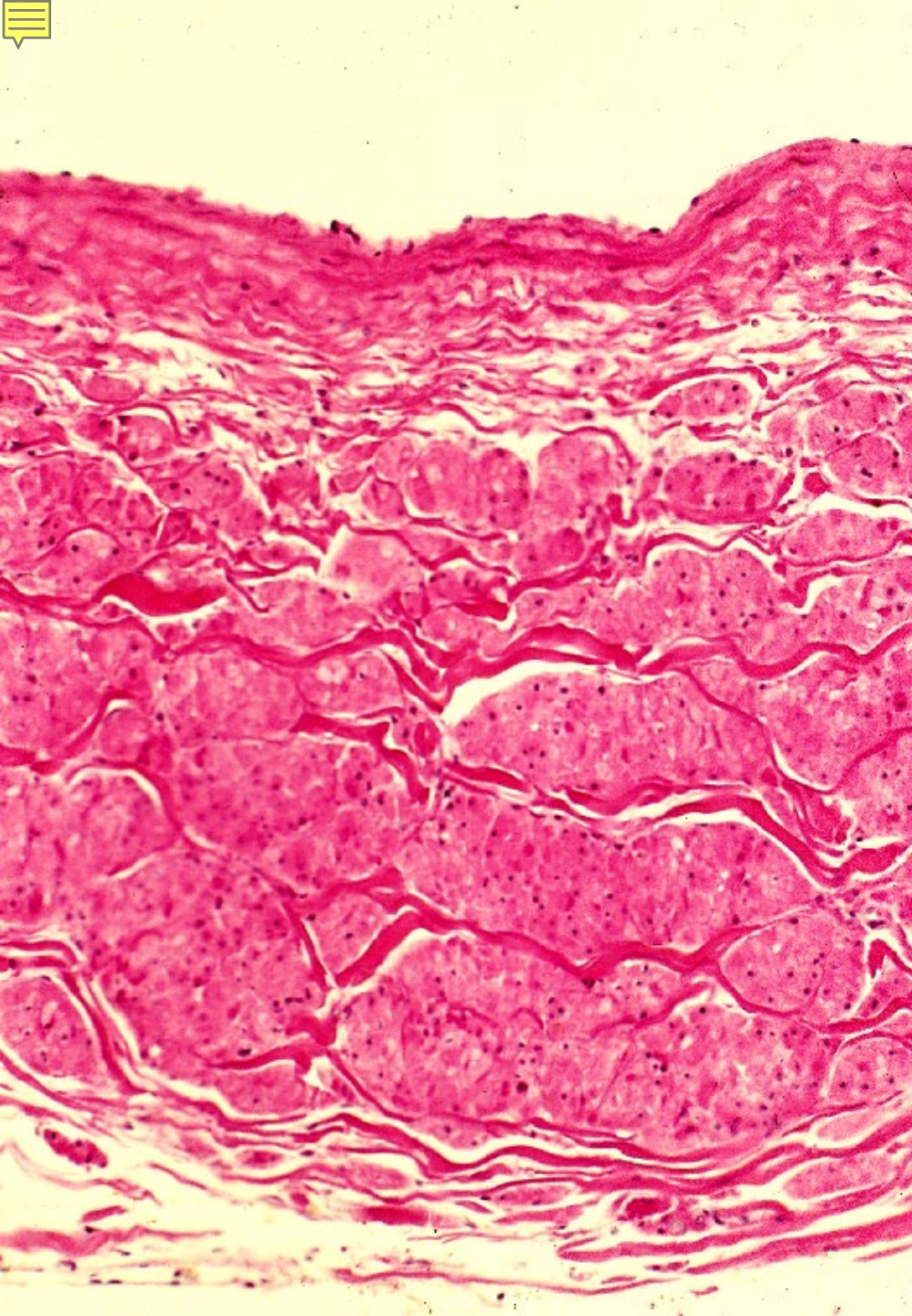
Tunica adventitia

06-30.
Aorta,
transverse section 2.
Human,
resorcin-fuchsin
stain,
x 25.



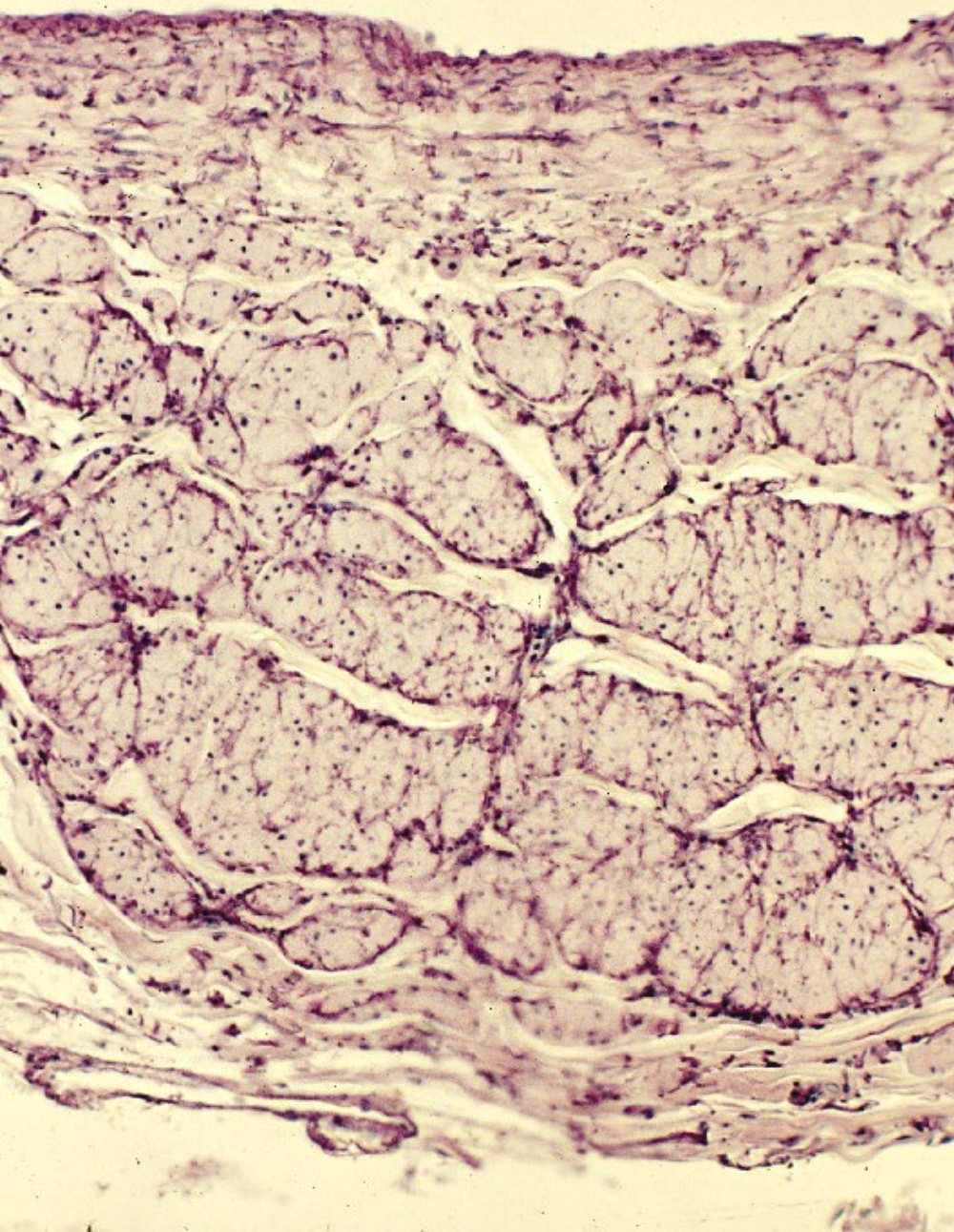
06-004

Veins



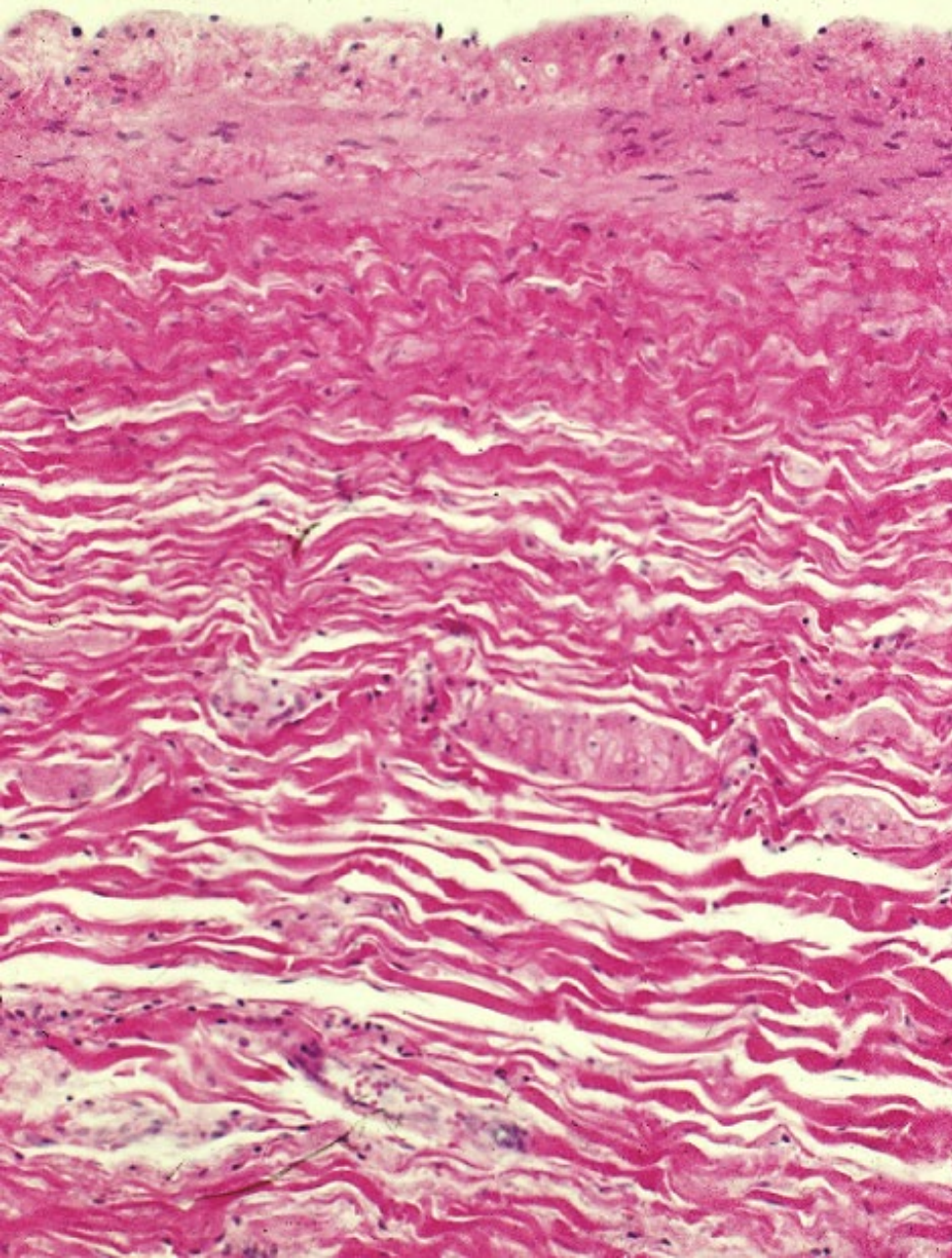
06-31.
V. cava inferior 1,
transverse section.
Human,
H-E stain,
x 40.

Tunica adventitia



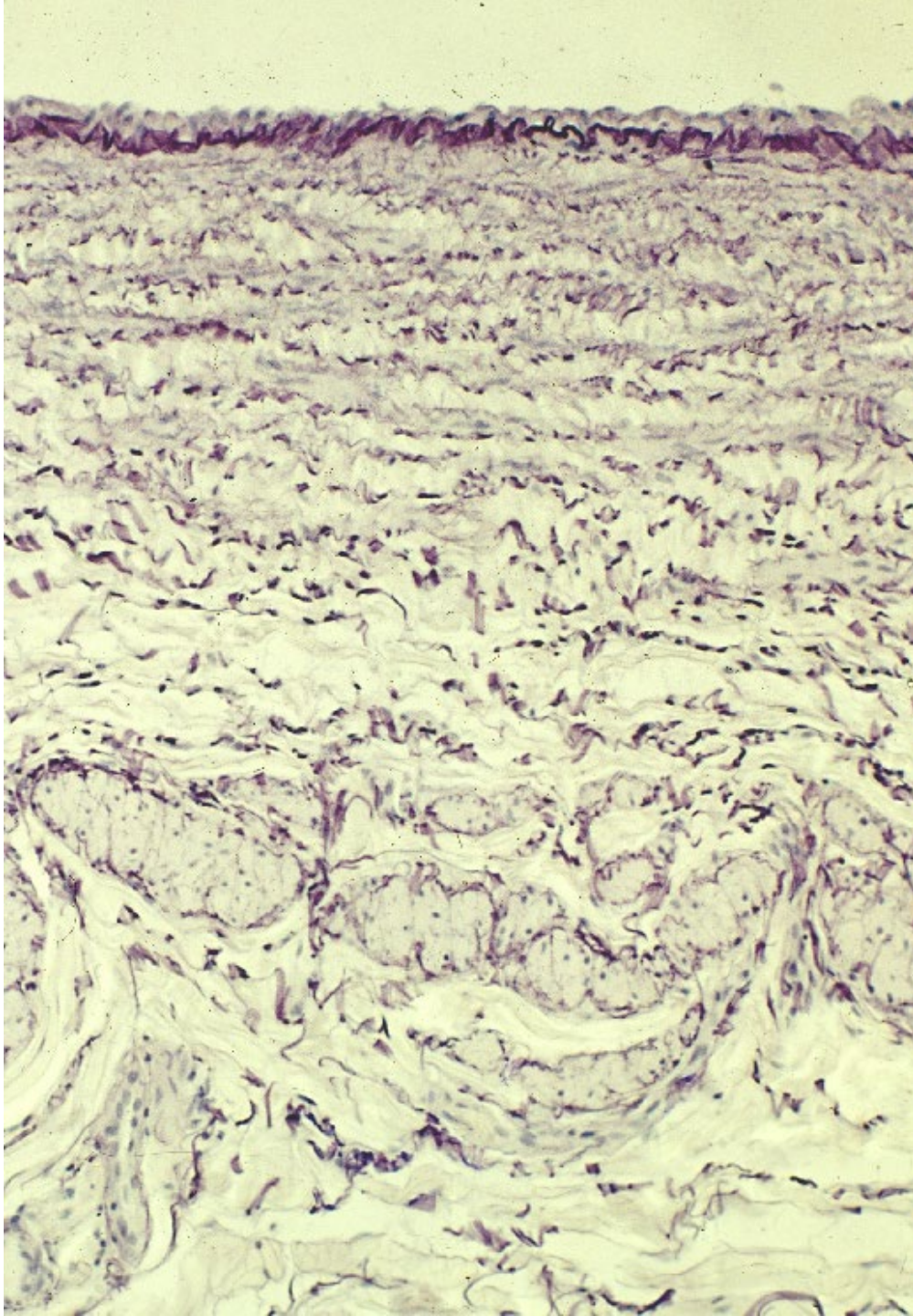
06-32.
V. cava inferior 2,
transverse section.
Human,
resorcin-fuchsin stain,
x 40.

Tunica adventitia

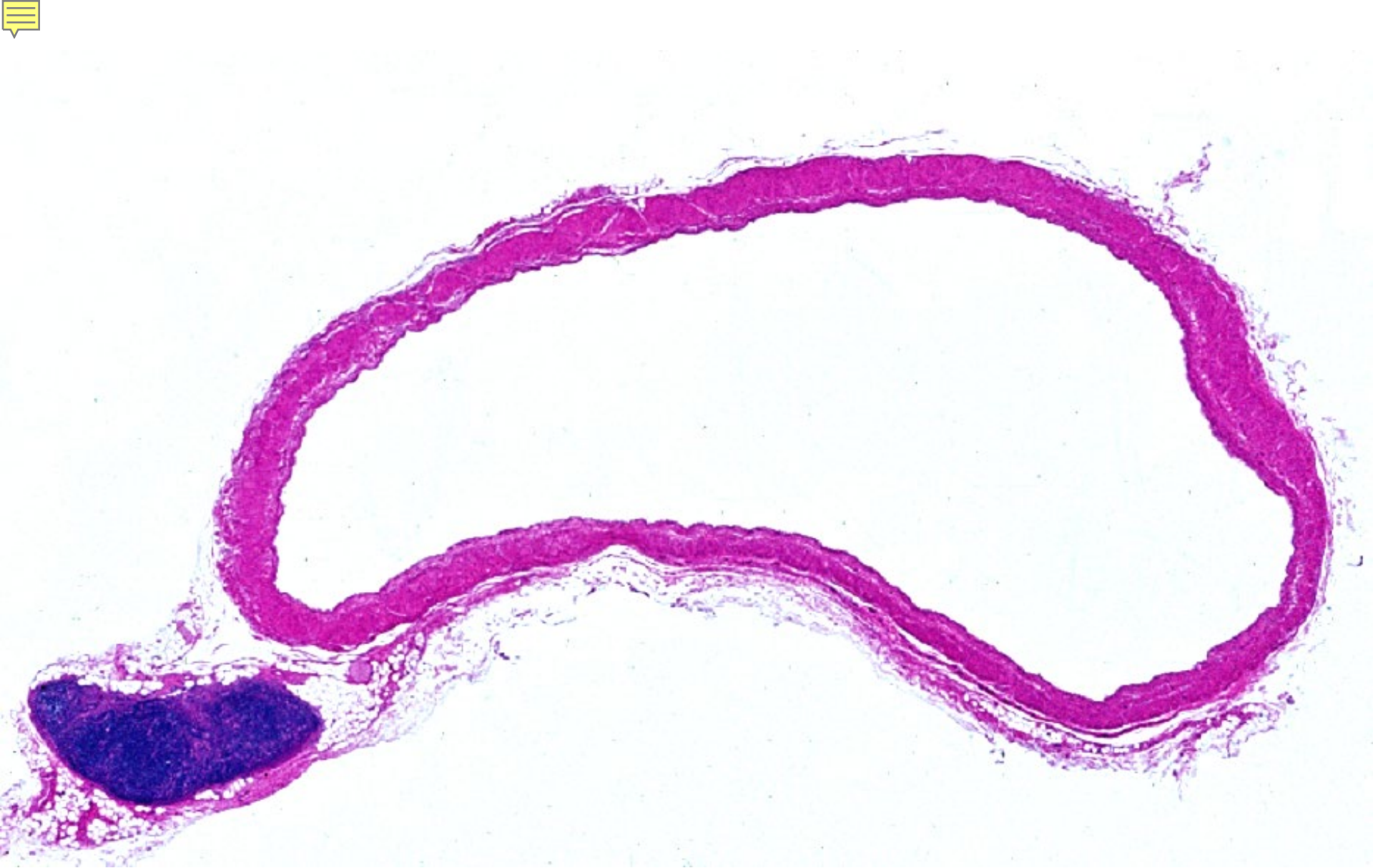

Tunica adventitia

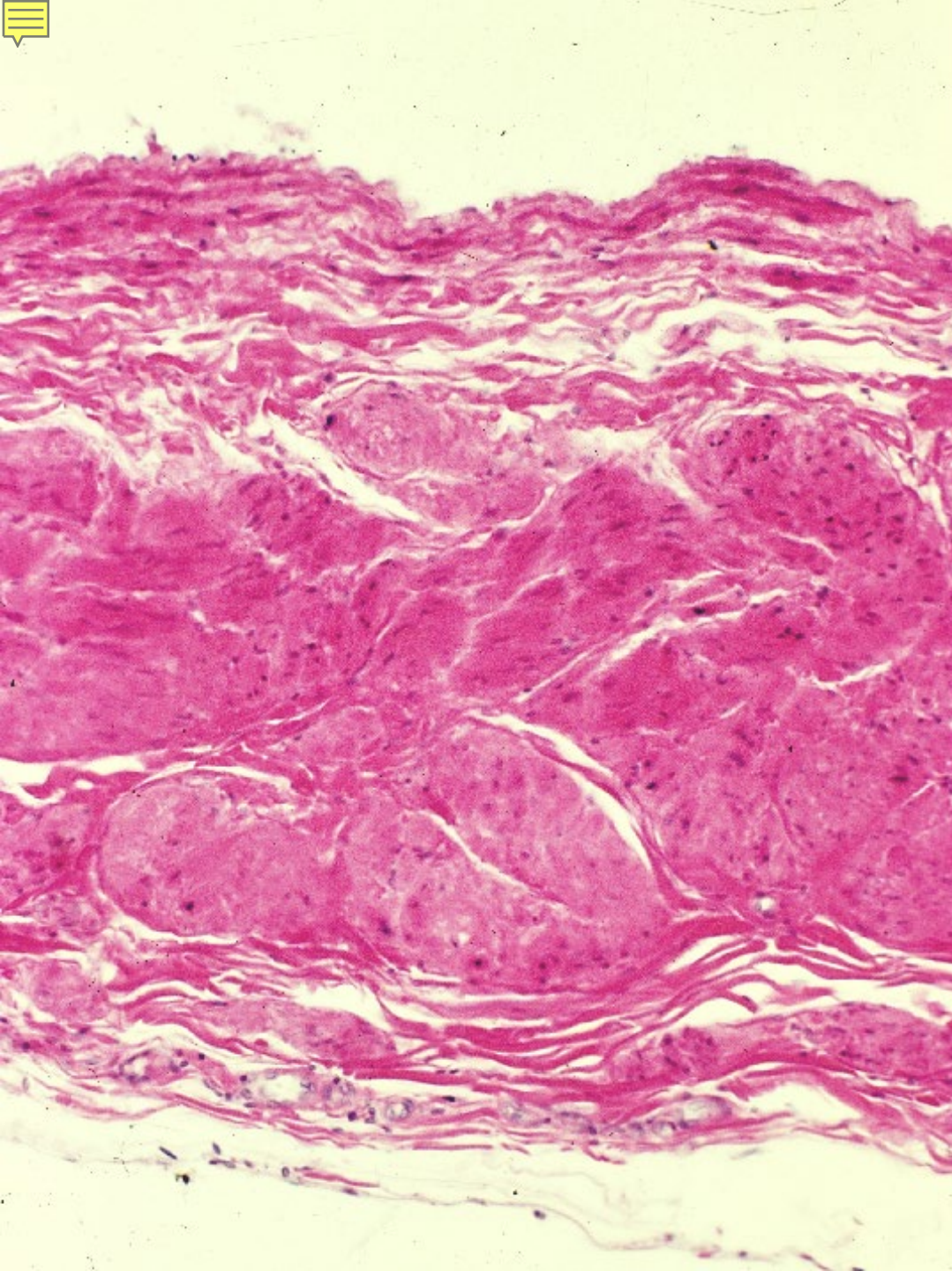
06-33.
V. cava superior 1,
transverse section.
Human,
H-E stain, x 40.



06-34.
V. cava superior 2,
transverse section,
Human
resorcin-fuchsin stain,
x 40.

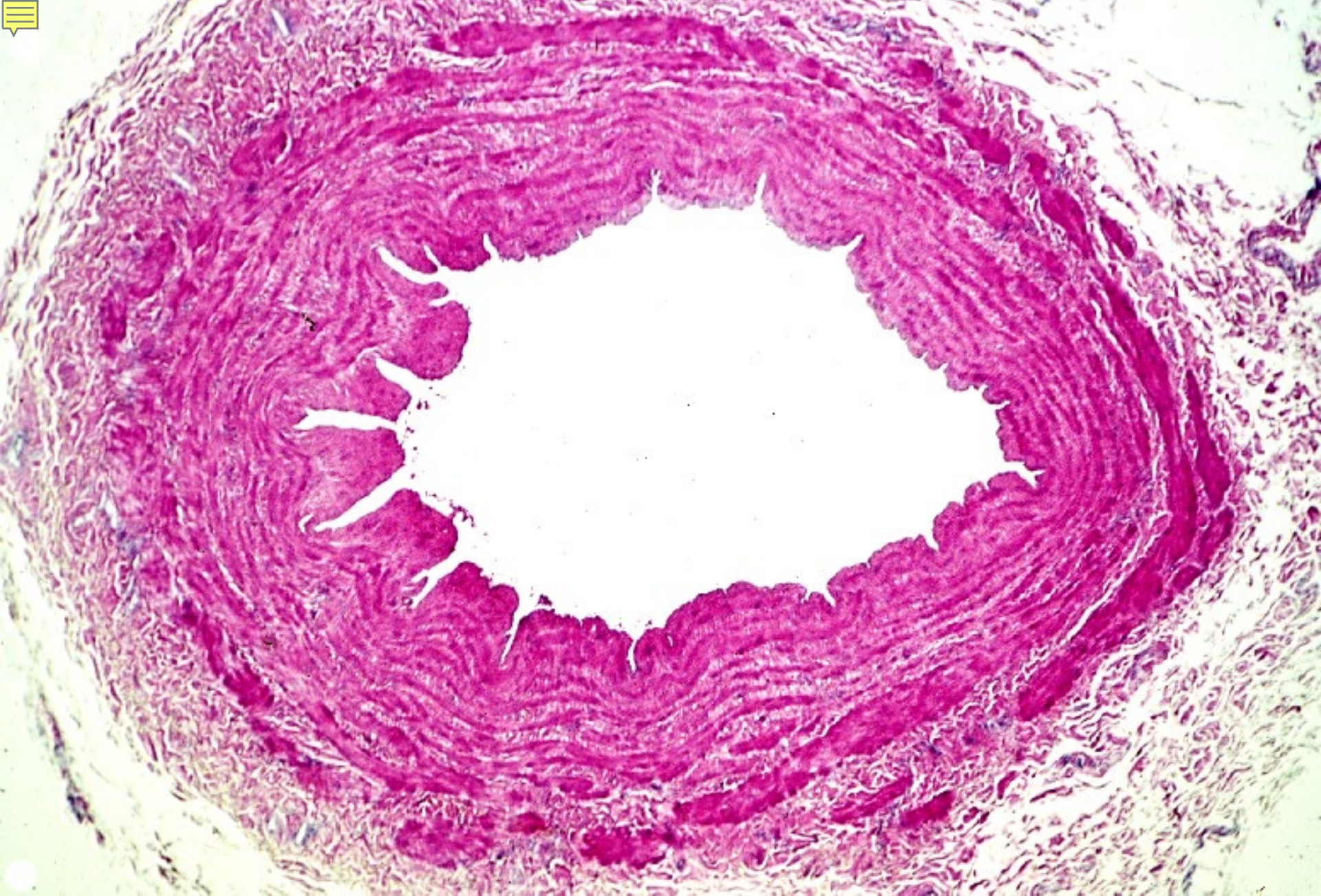


06-35. *V. portae* 1, transverse section. Human, H-E stain, x 2.6.

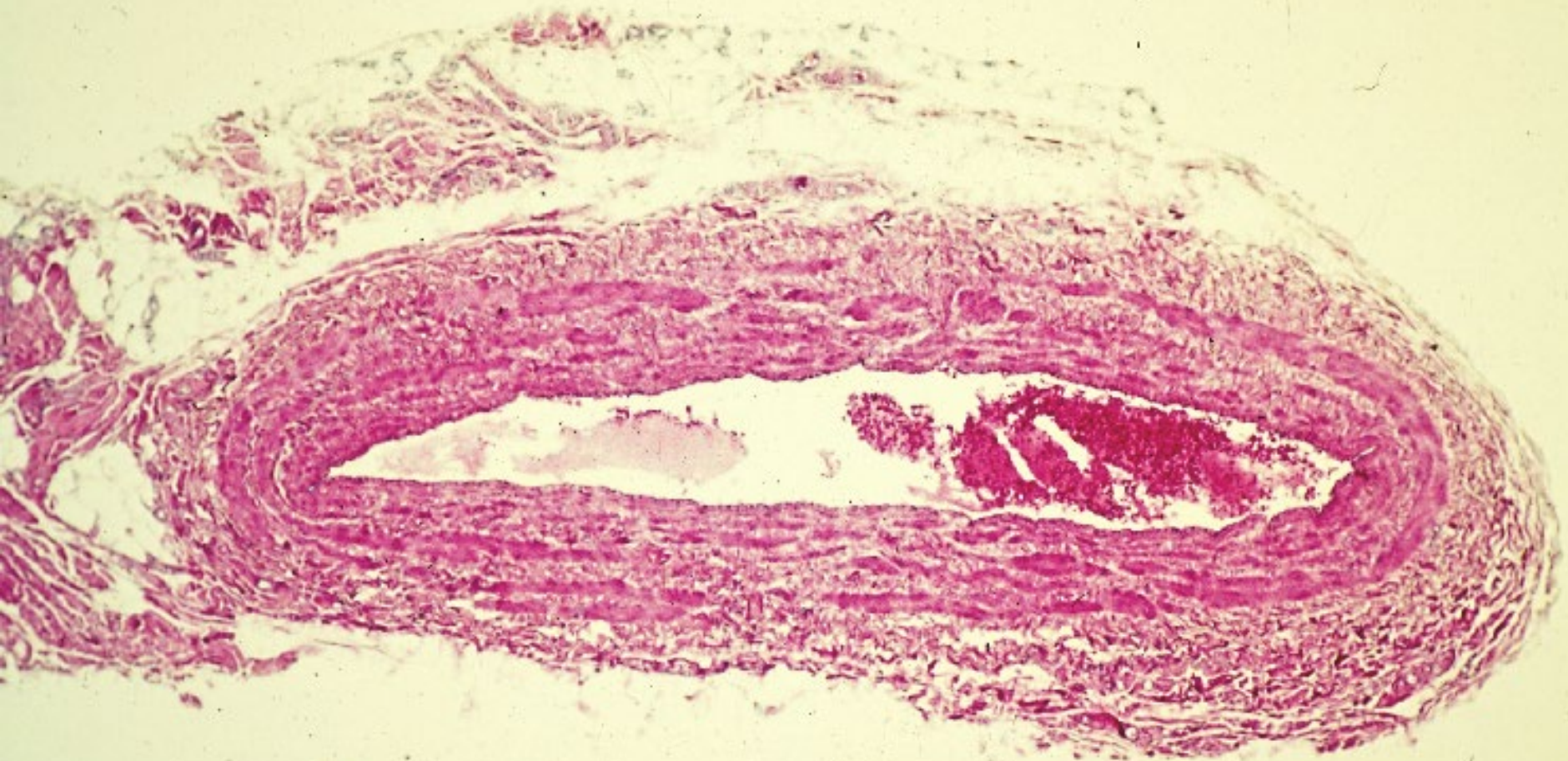


Tunica adventitia

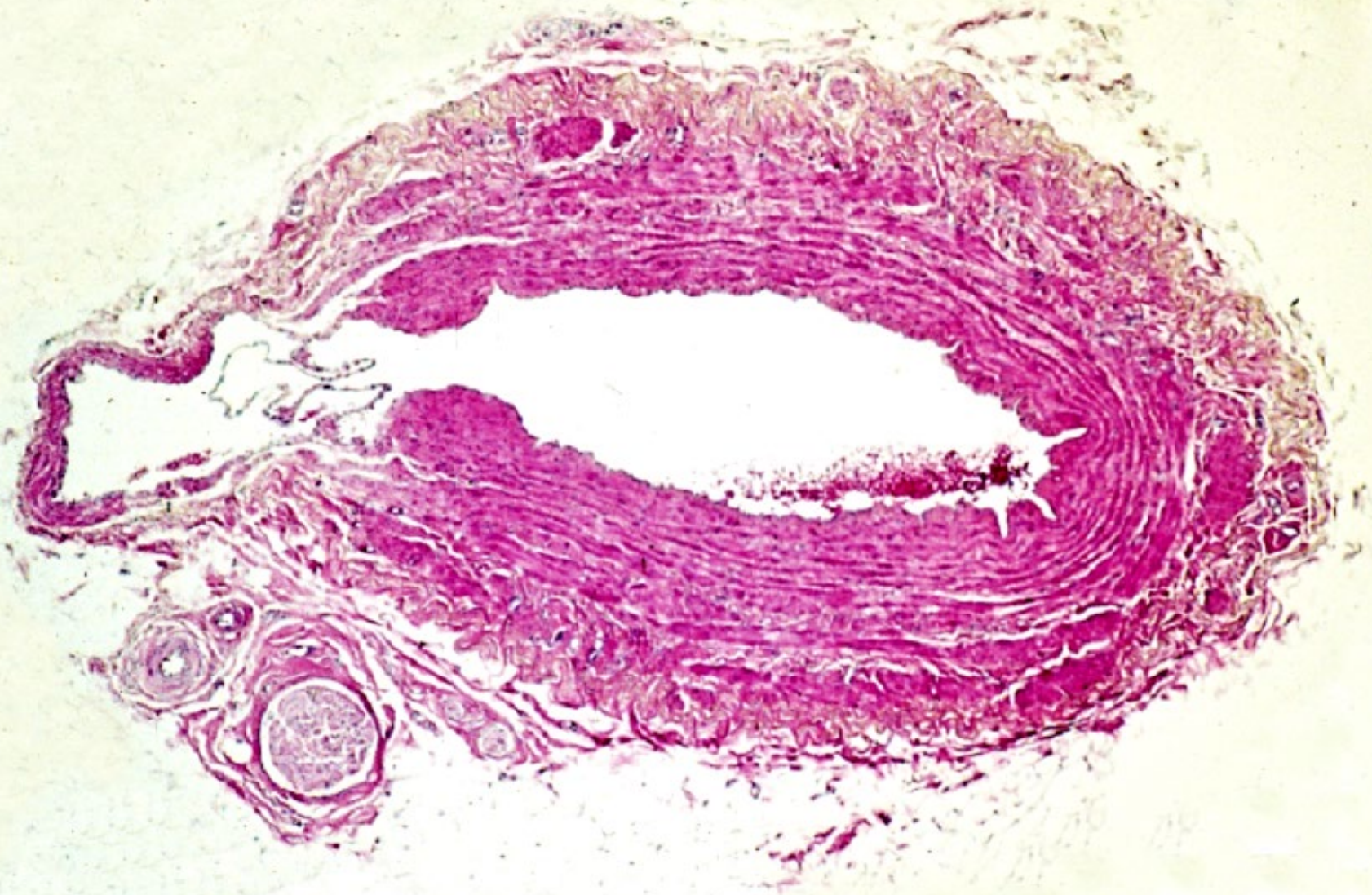
06-36.
V. portae 2,
transverse section.
Human,
H-E stain,
x 40.



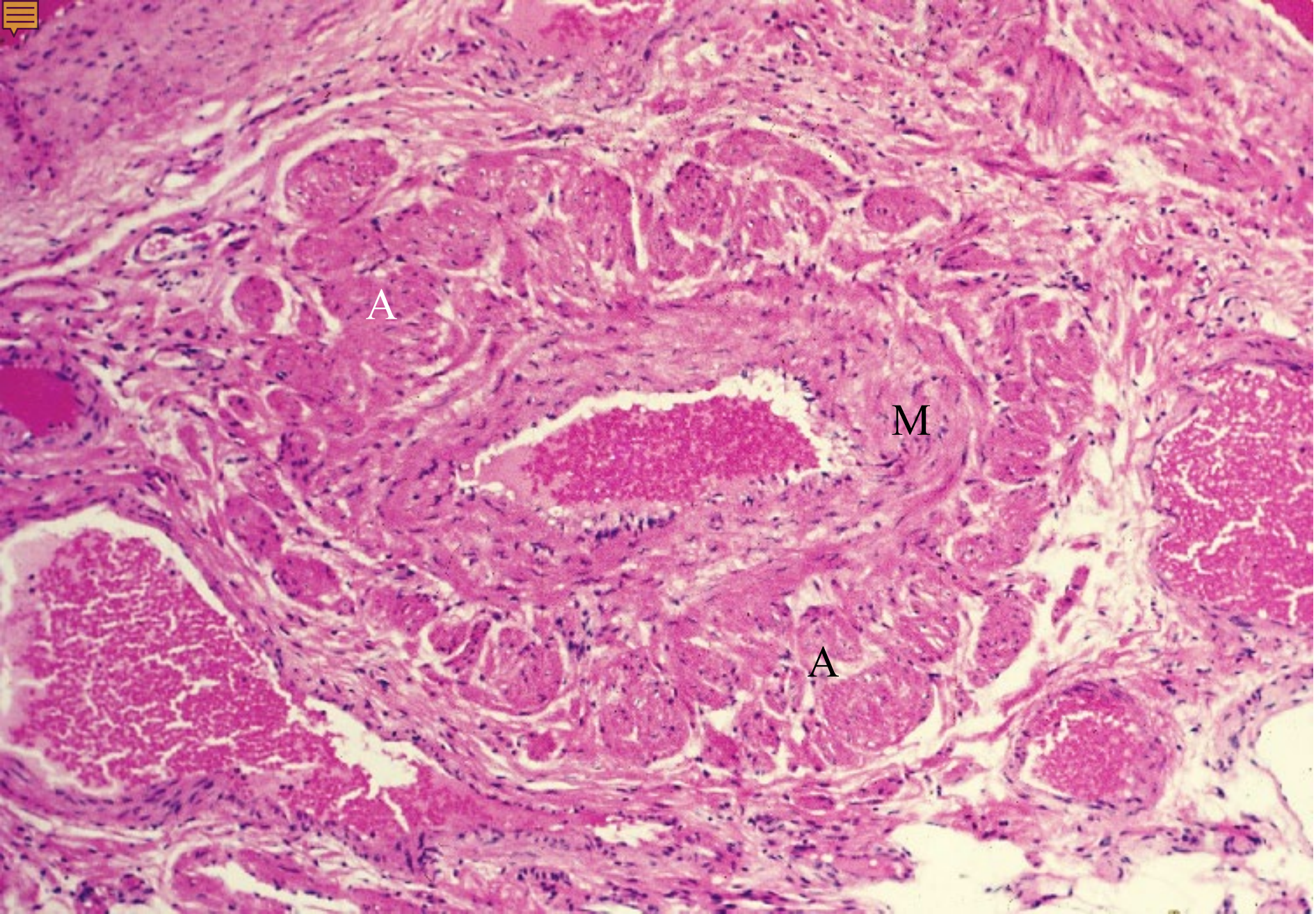
06-37. V. basilica, transverse section. Human, H-E stain, x 10.



06-38. *V. cephalica*, transverse section. Human, H-E stain, x 10.



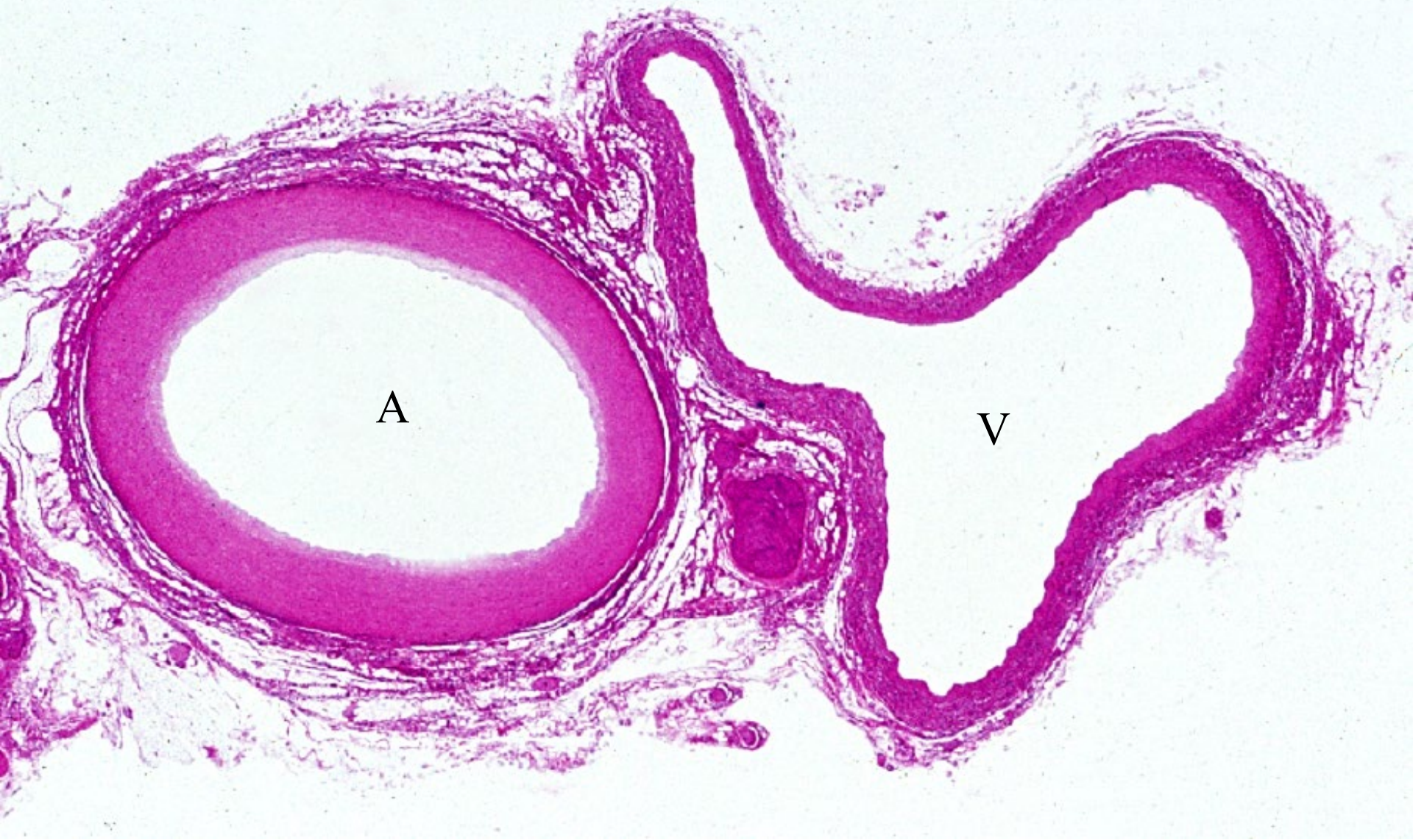
06-39. V. saphena magna, transverse section. Human, H-E stain, x 10.



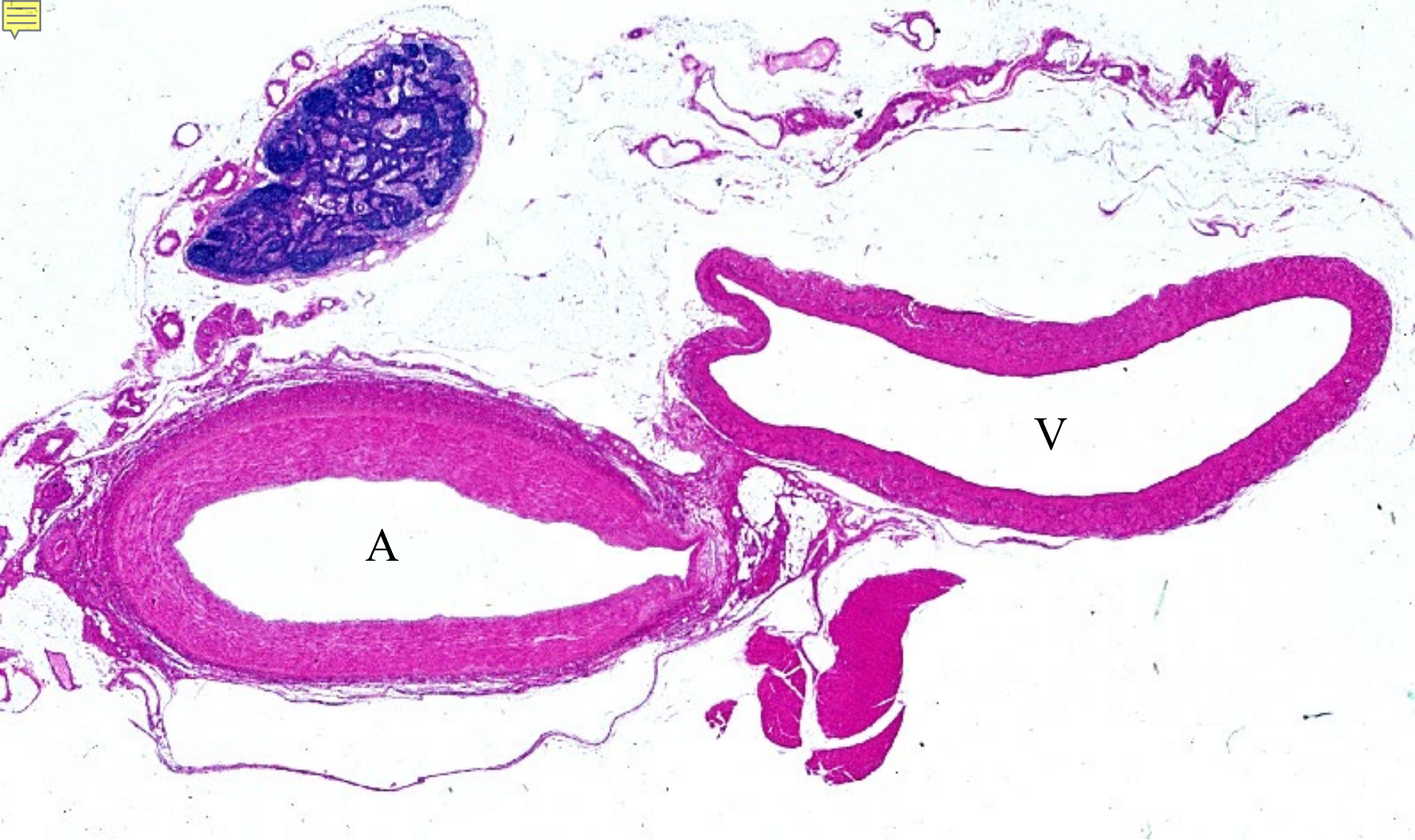06-40. Vein in spermatic cord, transverse section. Human, H-E stain, x 25

06-005

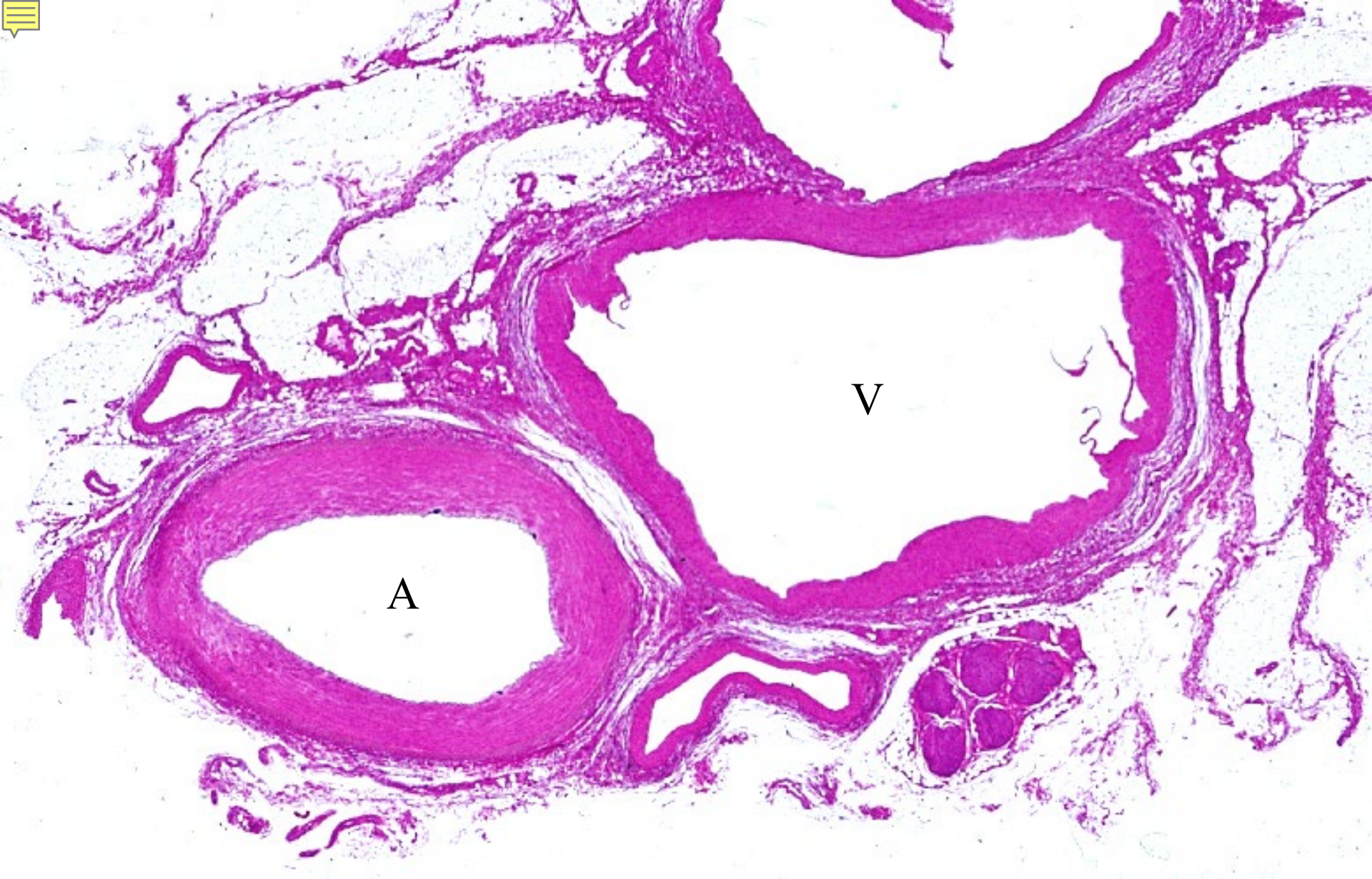
Large Arteries & Veins



06-41. A. carotis interna & V. jugularis interna. Human, H-E stain, x 2.3.



06-42. A. iliaca externa & V. iliaca externa.
Human, H-E stain, x 2.3.

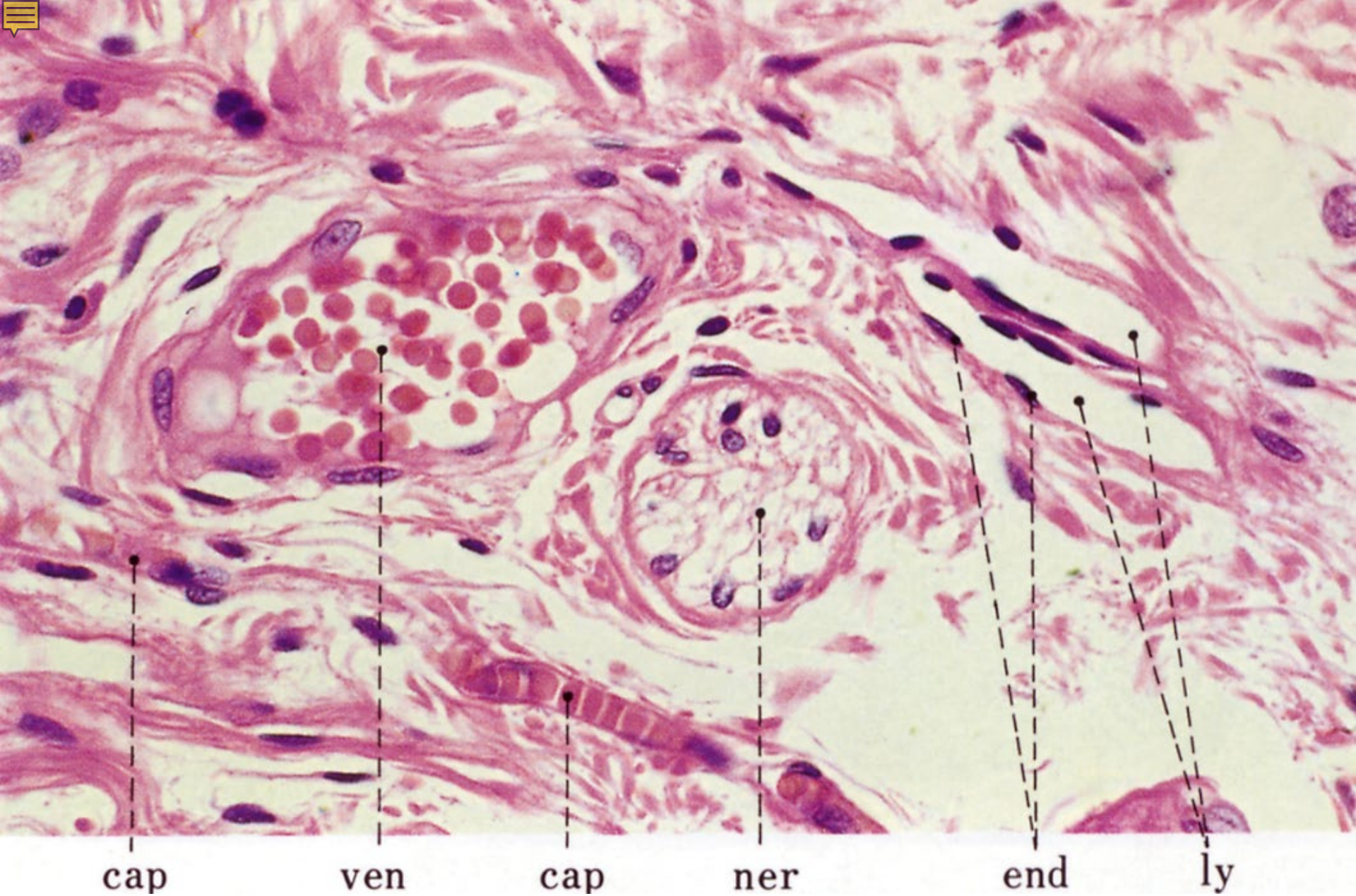


06-43. A. femoralis & V. femoralis. Human, H-E stain, x 2.3.

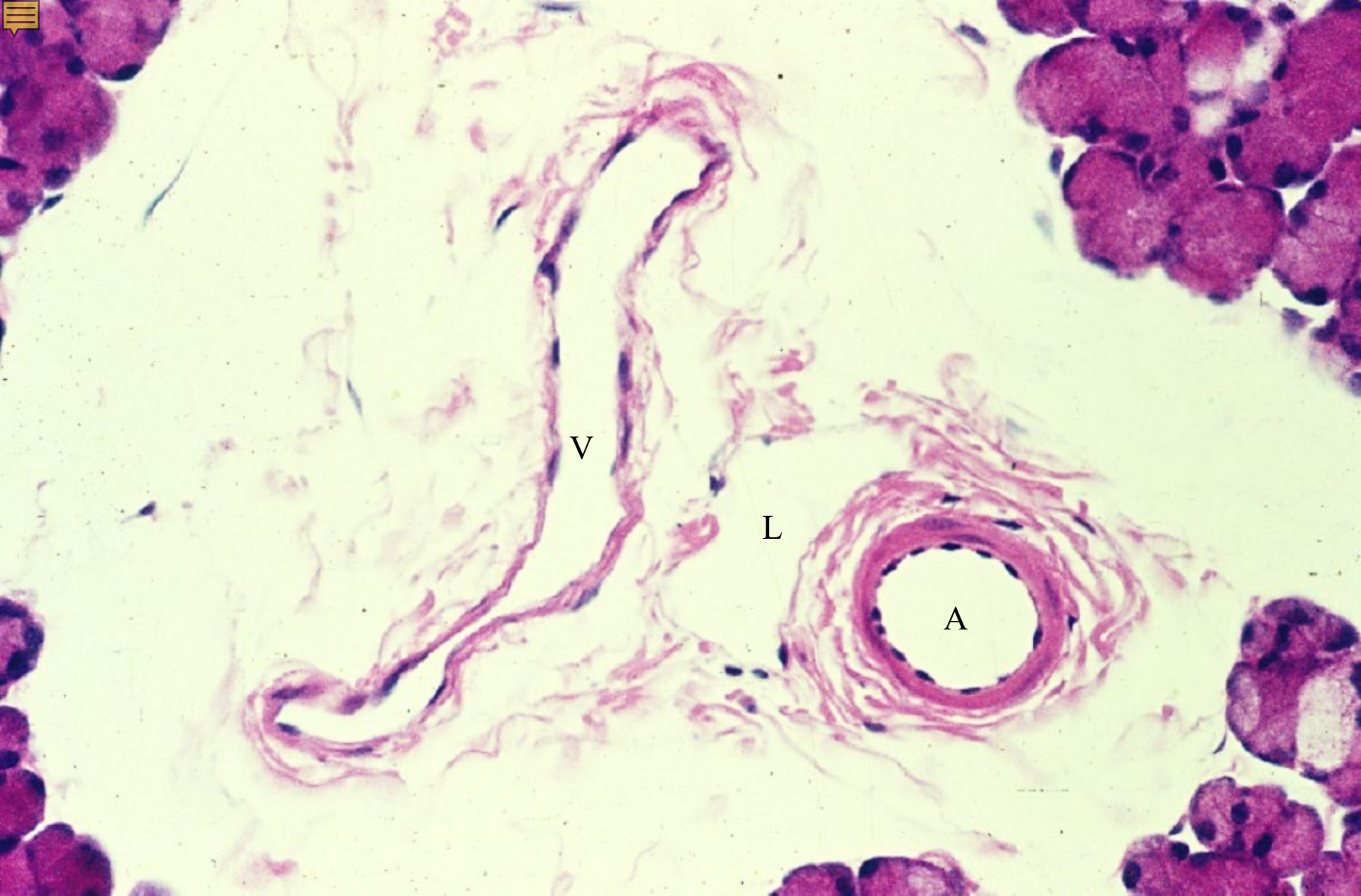


06-006

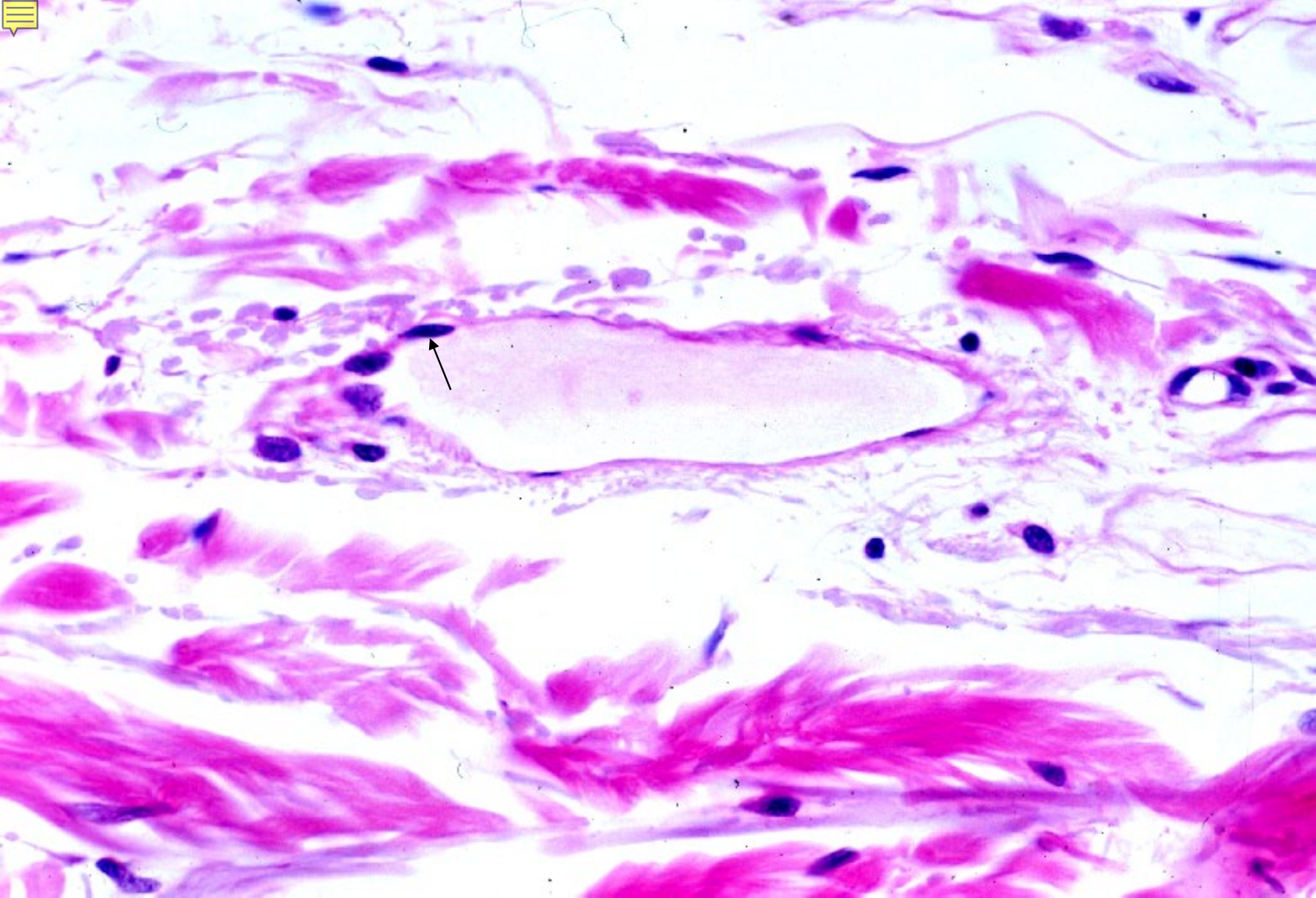
Lymphatics



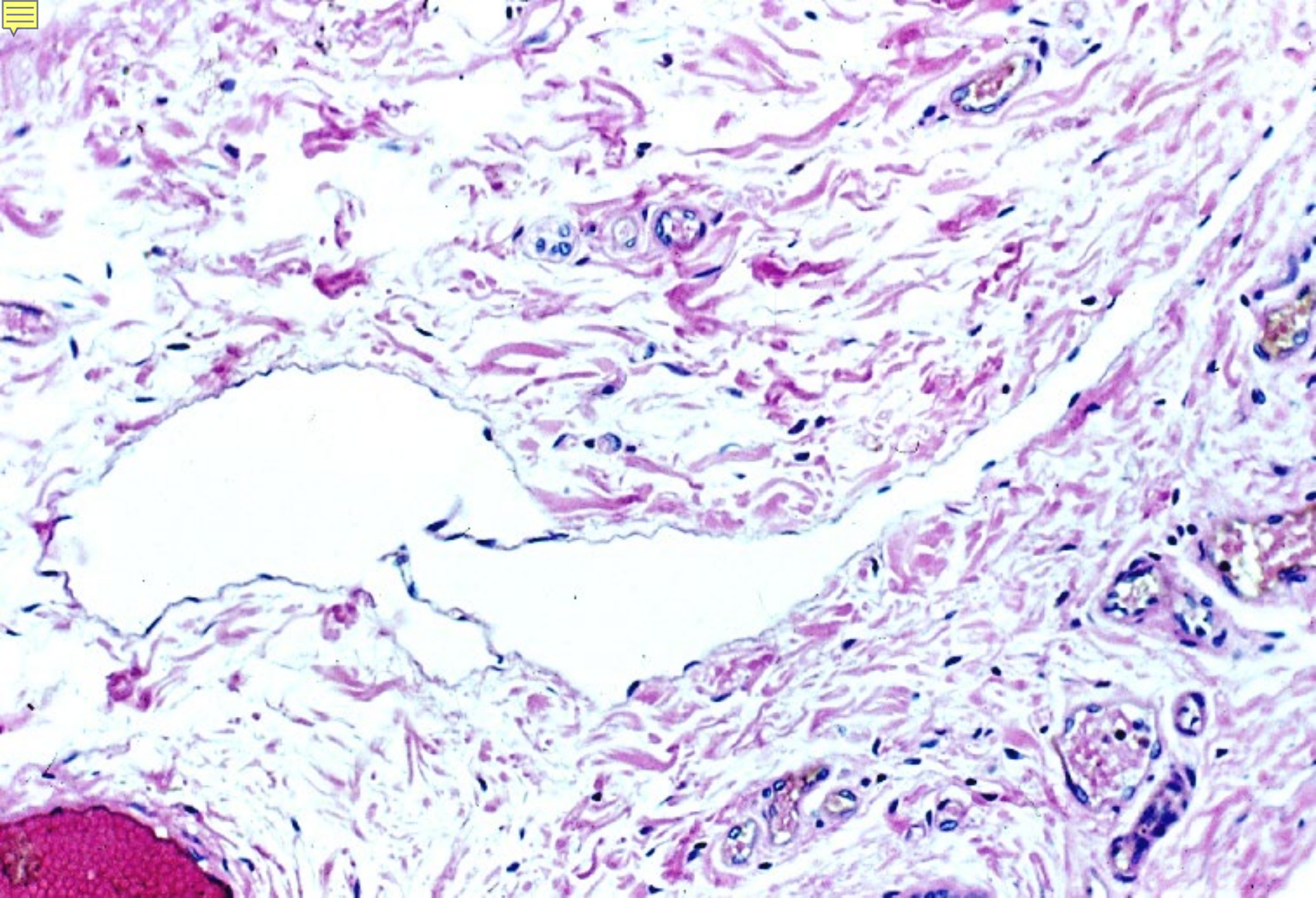
06-44. Lymph capillaries. Human, H-E stain, x 160.



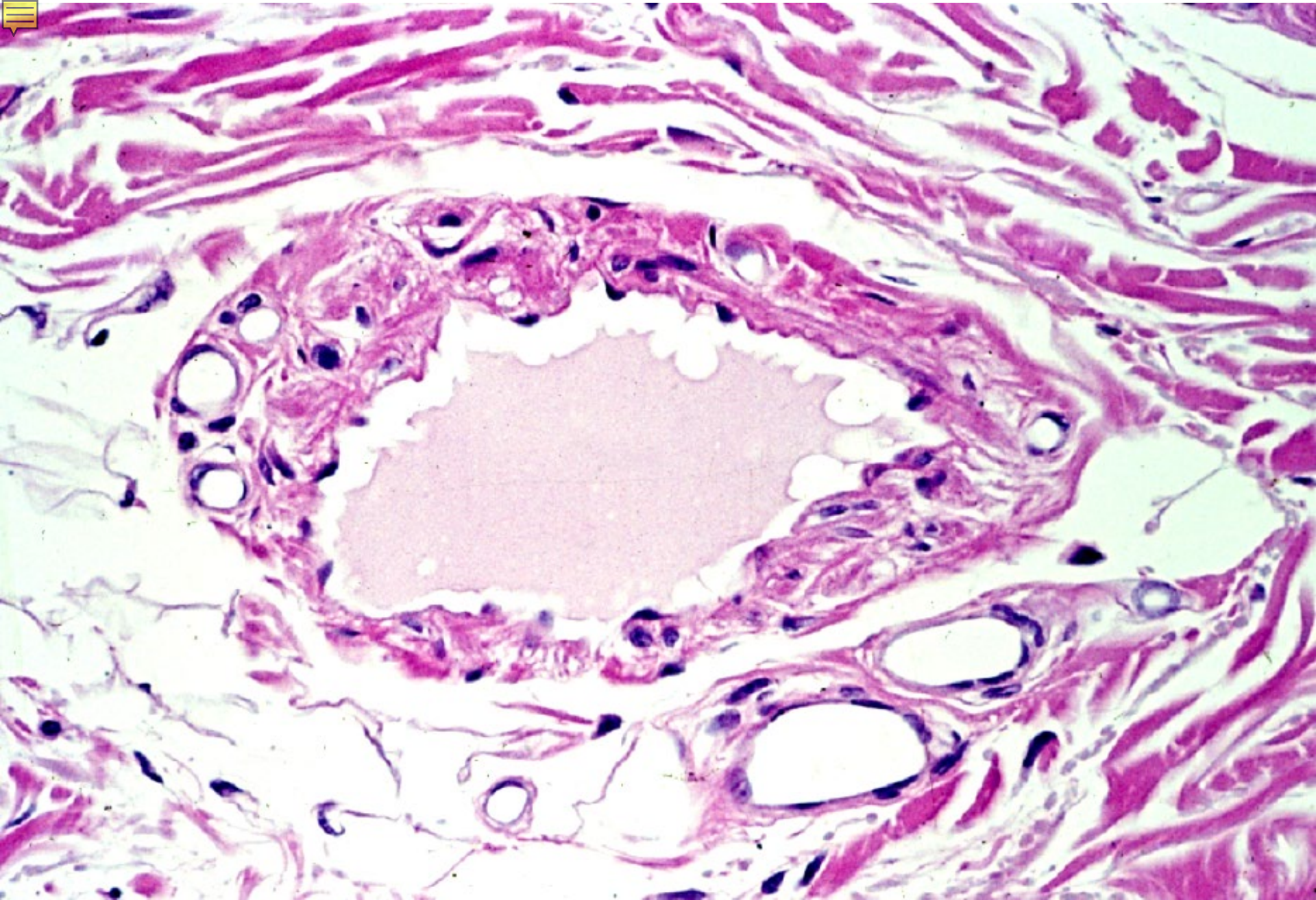
06-45. Artery, vein & lymphatics. Monkey, H-E stain, x 100.



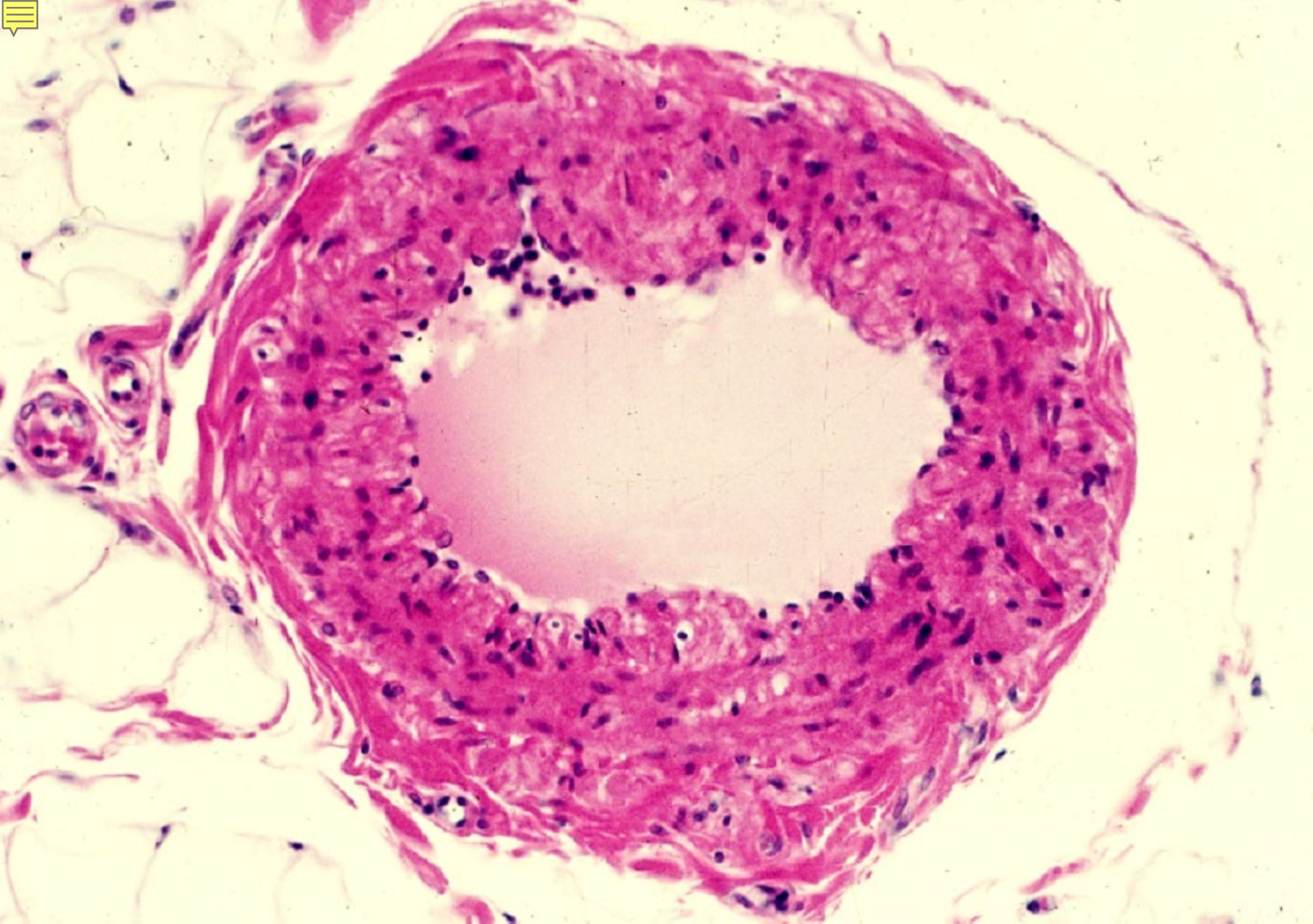
06-46. Small lymphatics. Human, H-E stain, x 160.



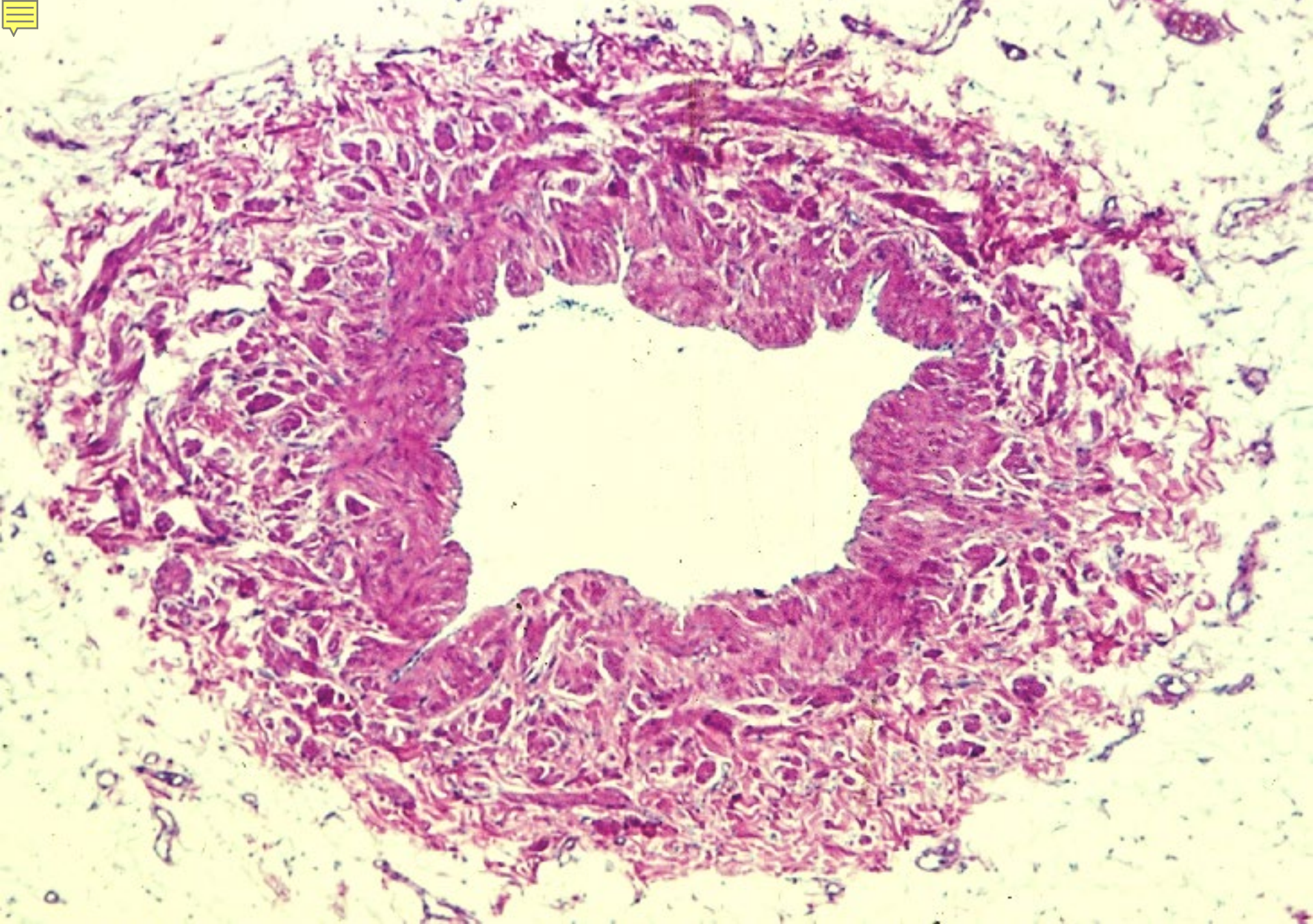
06-47. Valves of lymphatics. Human, H-E stain, x 64.



06-48. Lymphatics, transverse section 1. Human, H-E stain, x 100.



06-49. Lymphatics, transverse section 2. Human, H-E stain, x 64.

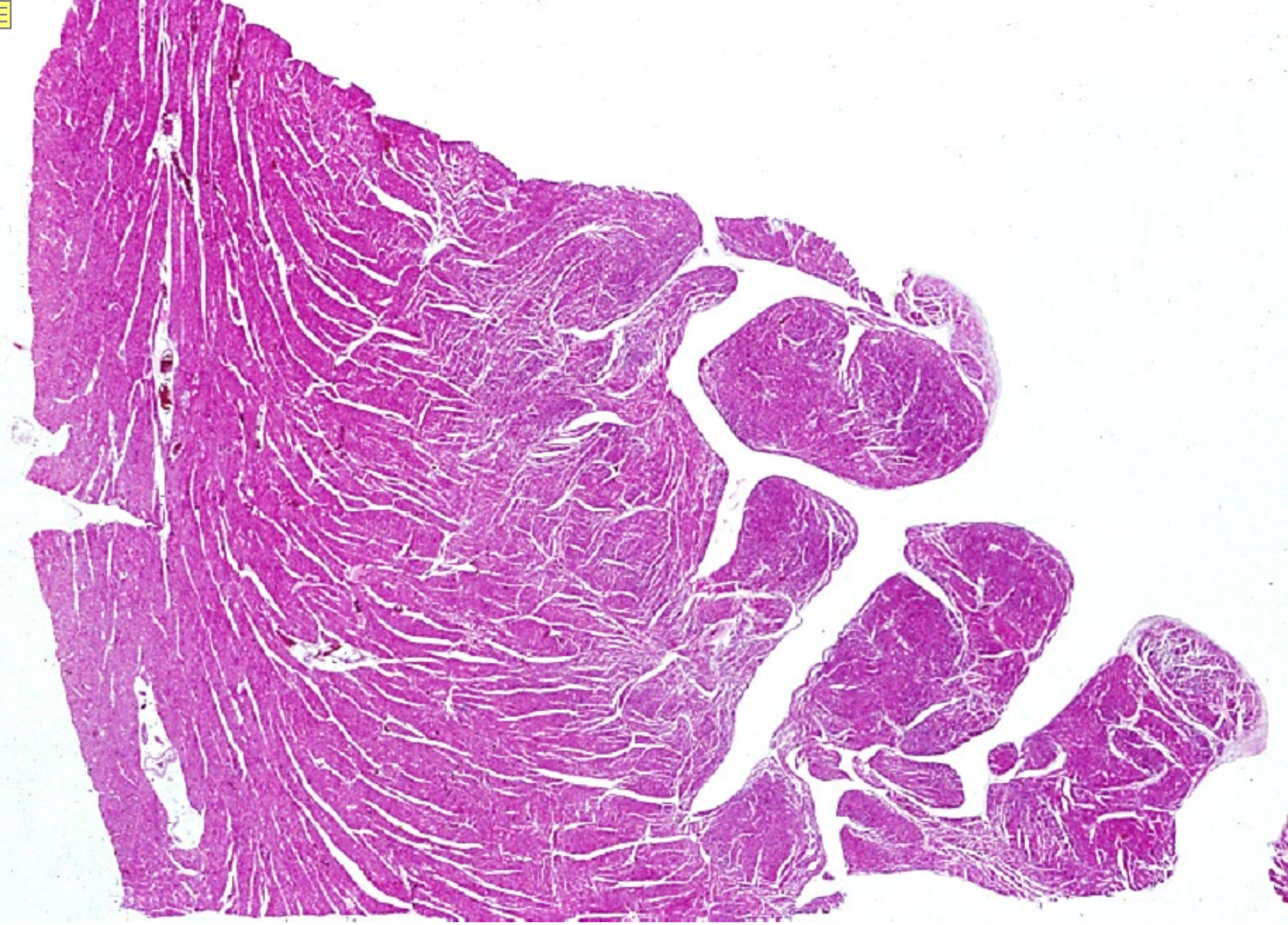


06-50. Ductus thoracicus, transverse section. Human, H-E stain, x 15.

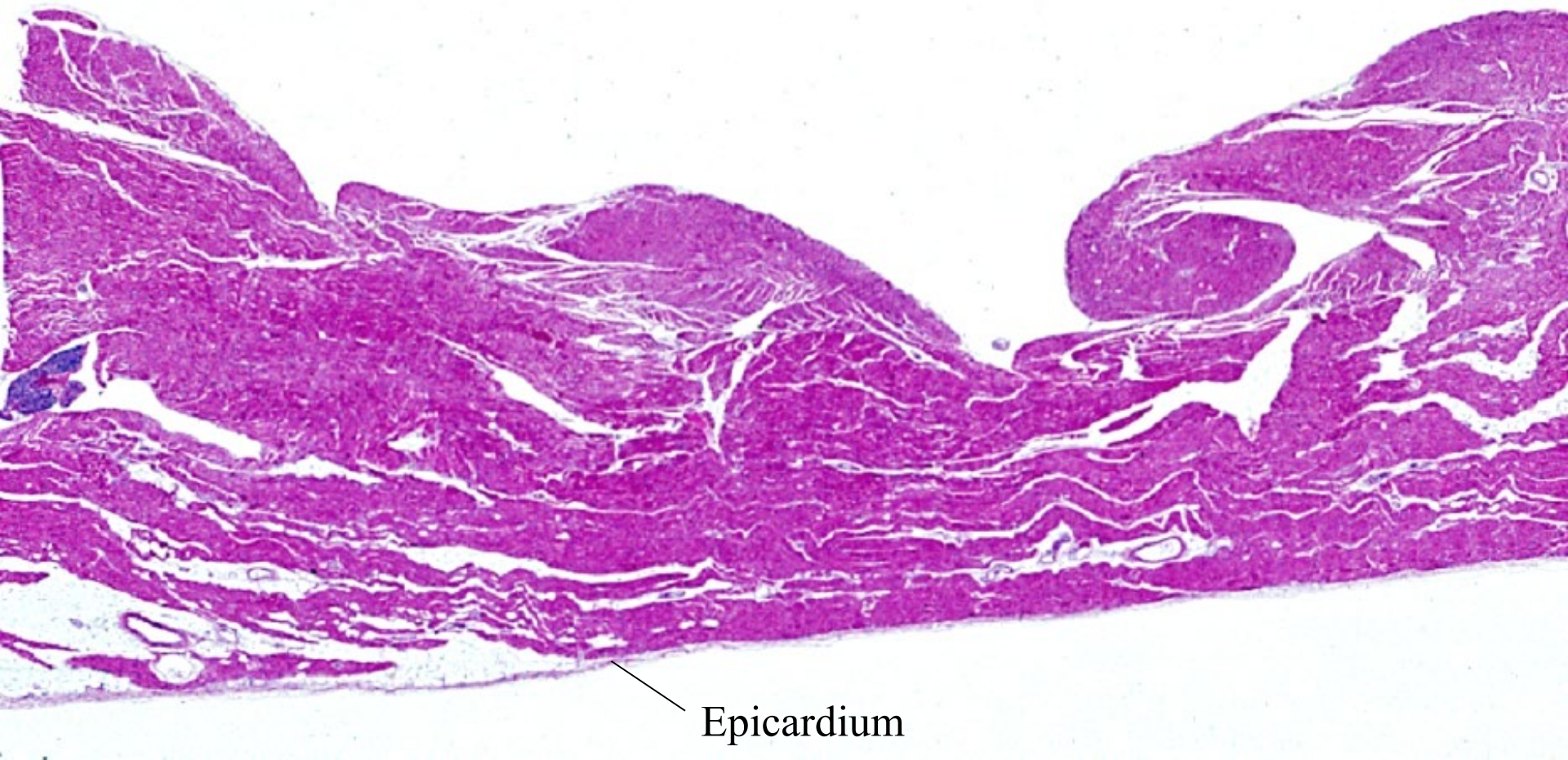

06-006

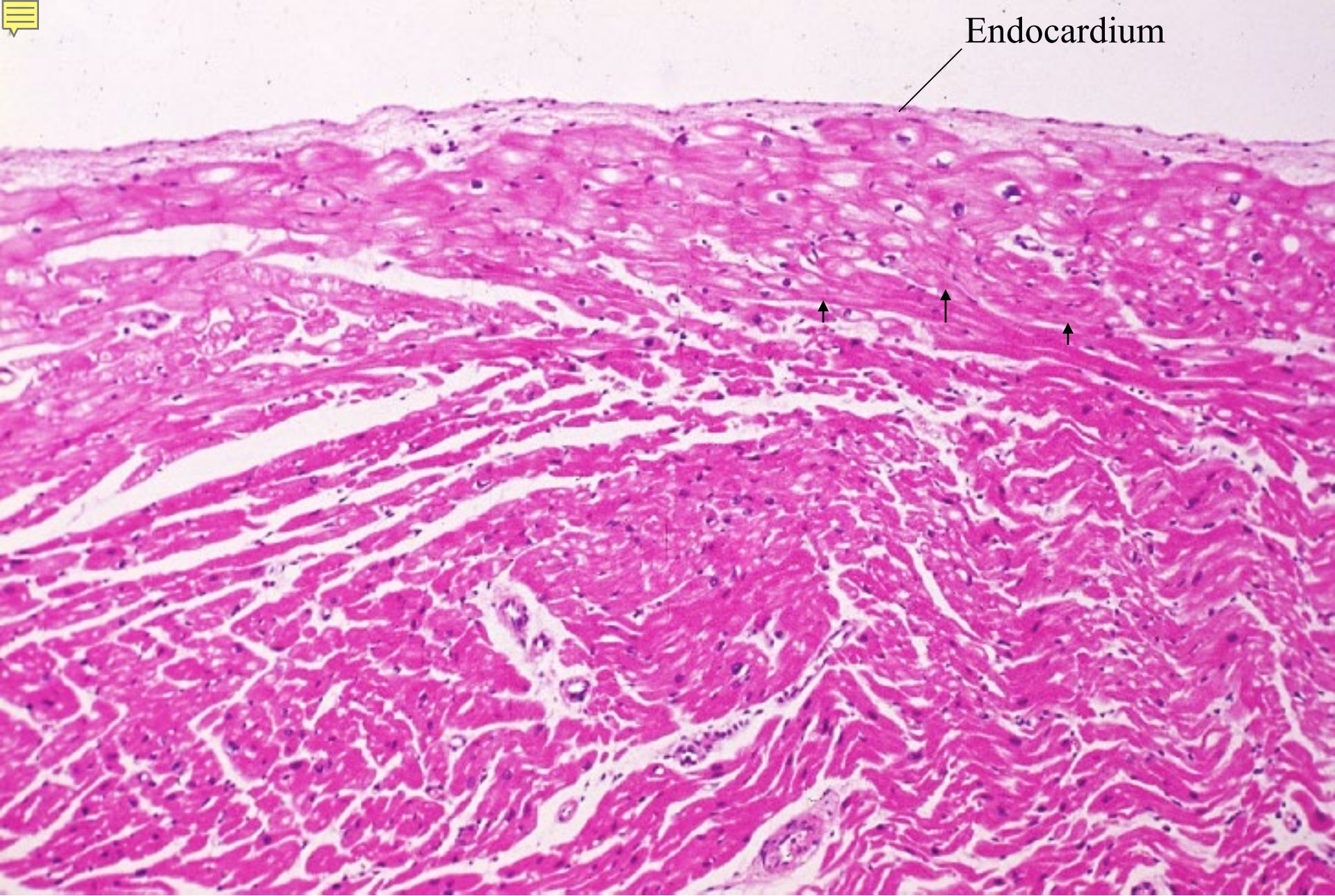
Heart



06-51. Wall of ventriculus, transverse section. Human, H-E stain, x 1.5.

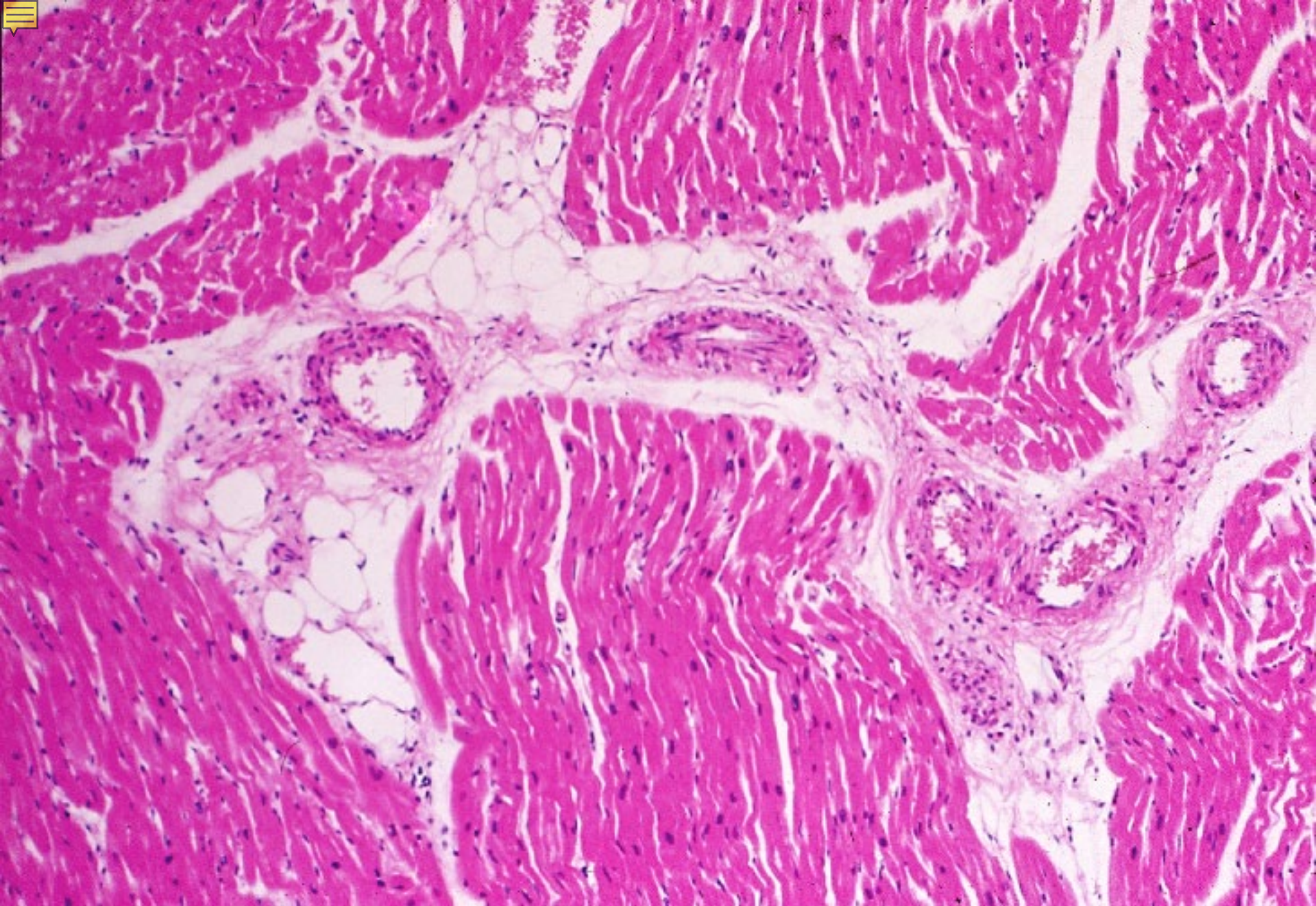


06-52. Wall of atrium, transverse section. Human, H-E stain, x 2.5.

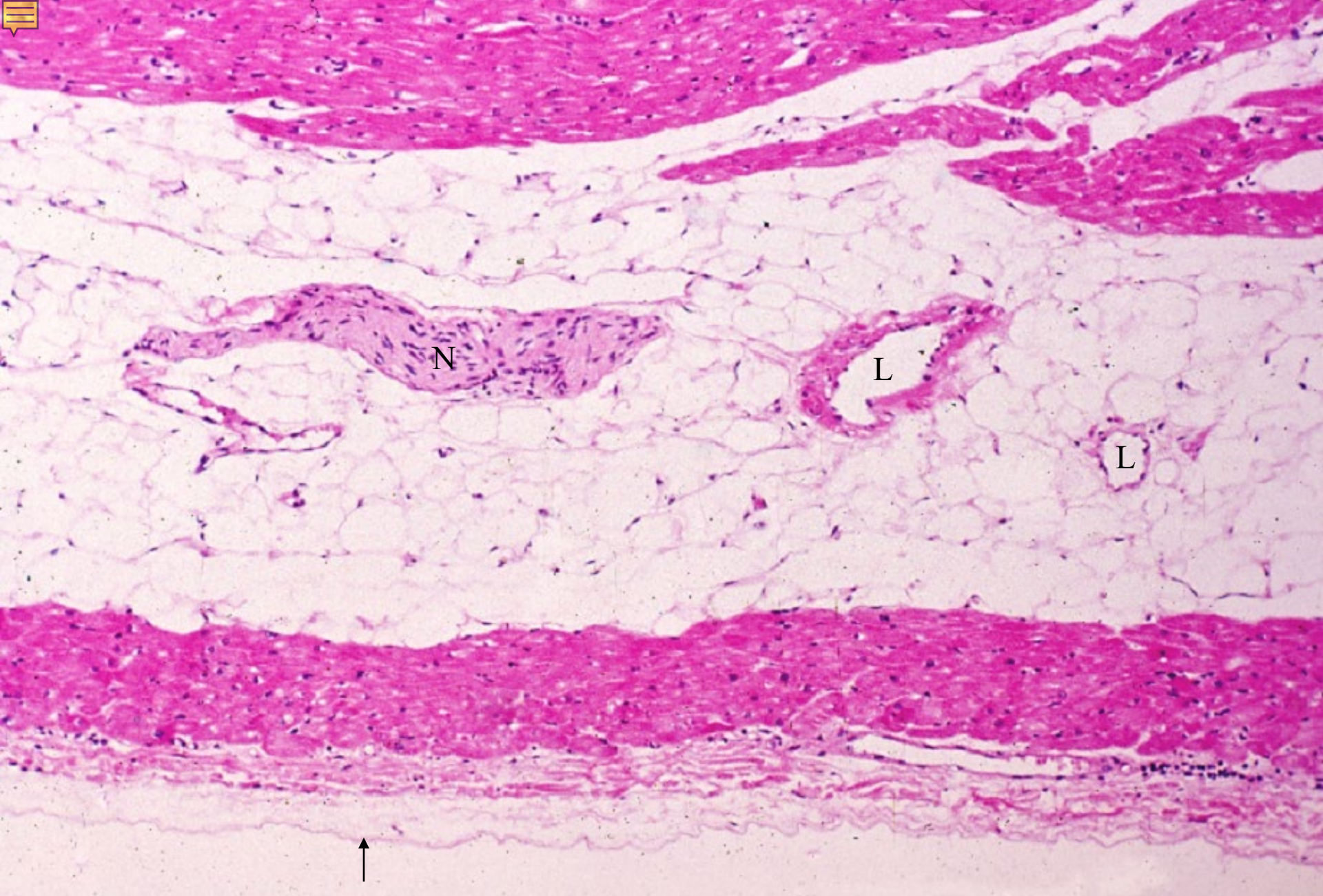


Endocardium

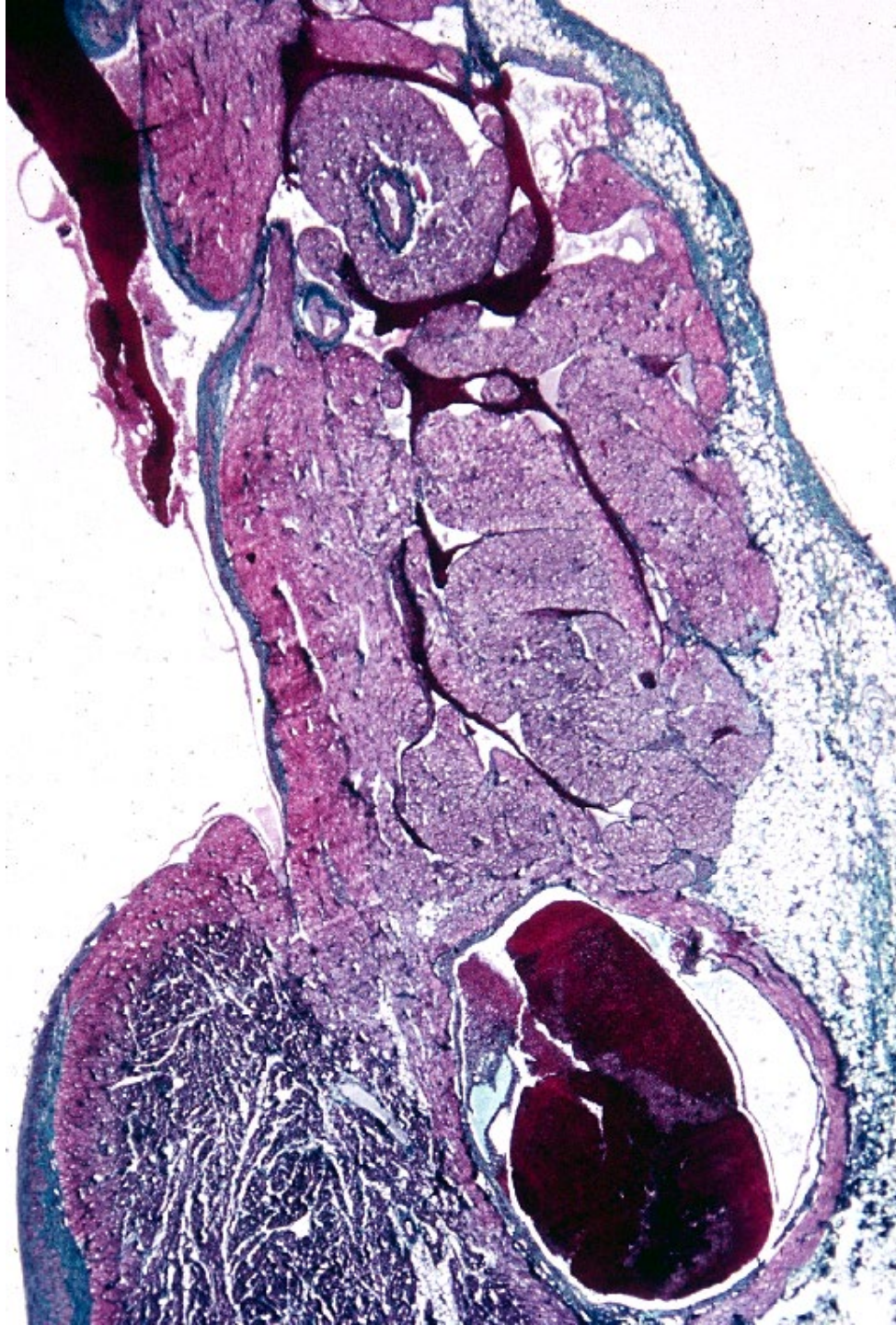
06-53. Endocardium & myocardium. Human, H-E stain, x 25.



06-54. Myocardium. Human, H-E stain, x 25.



06-55. Epicardium. Human, H-E stain, x 25.



06-56.
Sinus node.
Human,
Azan stain,
x 4.