



Data base of Histology Color slides

Mizoguchi, Fumio

(Issue Date)

2015-05-04

(Resource Type)

learning object

(Version)

Version of Record

(Rights)

1. 利用者による利用の範囲は、著作権法に定める私的利用の範囲とする。2. 研究成果を利用者が利用した結果について、許諾者はその責任を負わない。
私的利用の範囲を超える二次利用（印刷物、ウェブサイト、発表資料等への転載など）については、利用希望者は附属図書館（<https://lib.kobe-u.ac.jp/da/secondaryuse/#secondaryuse-...>）

(URL)

<https://hdl.handle.net/20.500.14094/90009617>

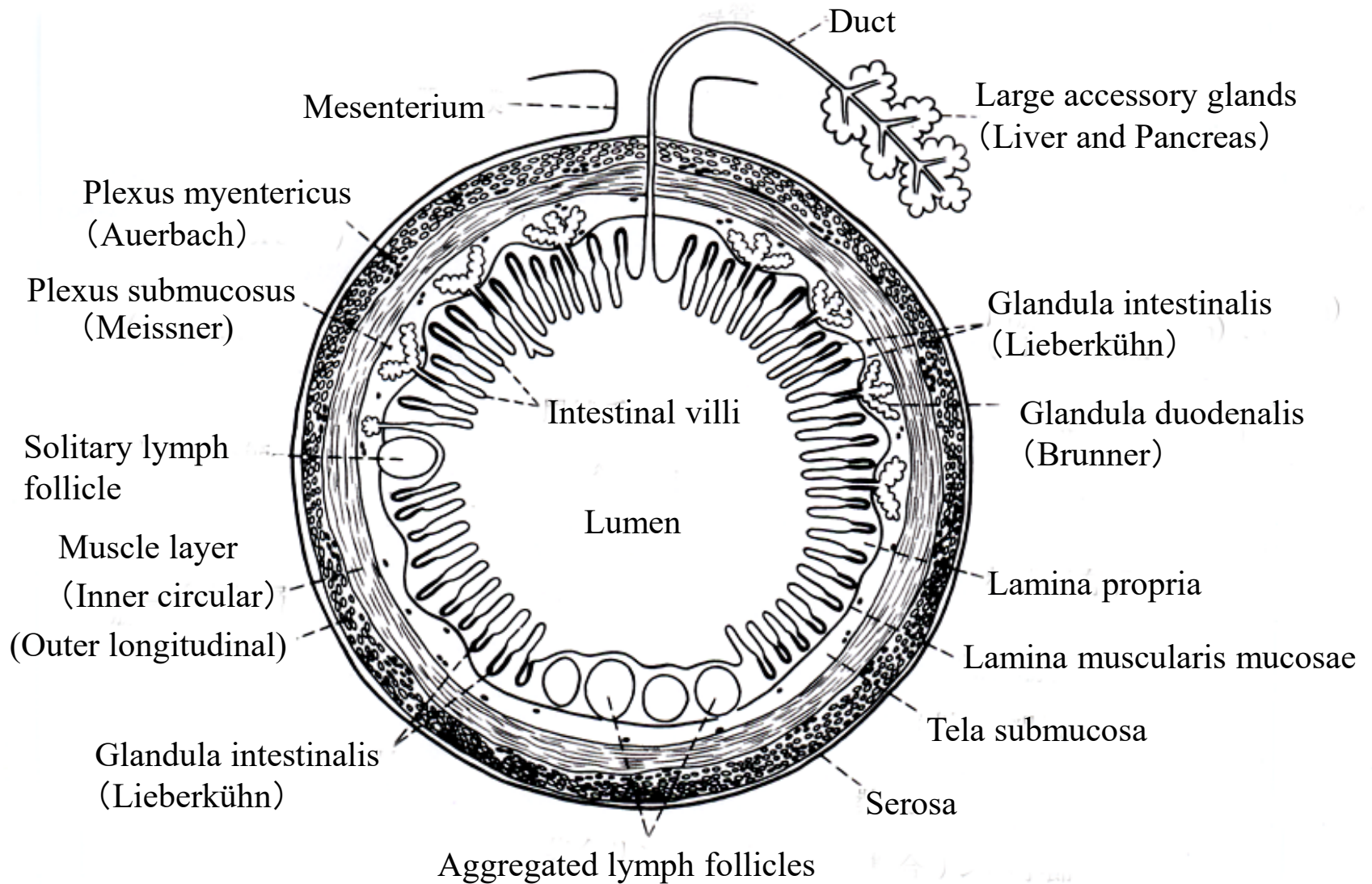




09

Digestive system 1

Oral cavity & Salivary Glands

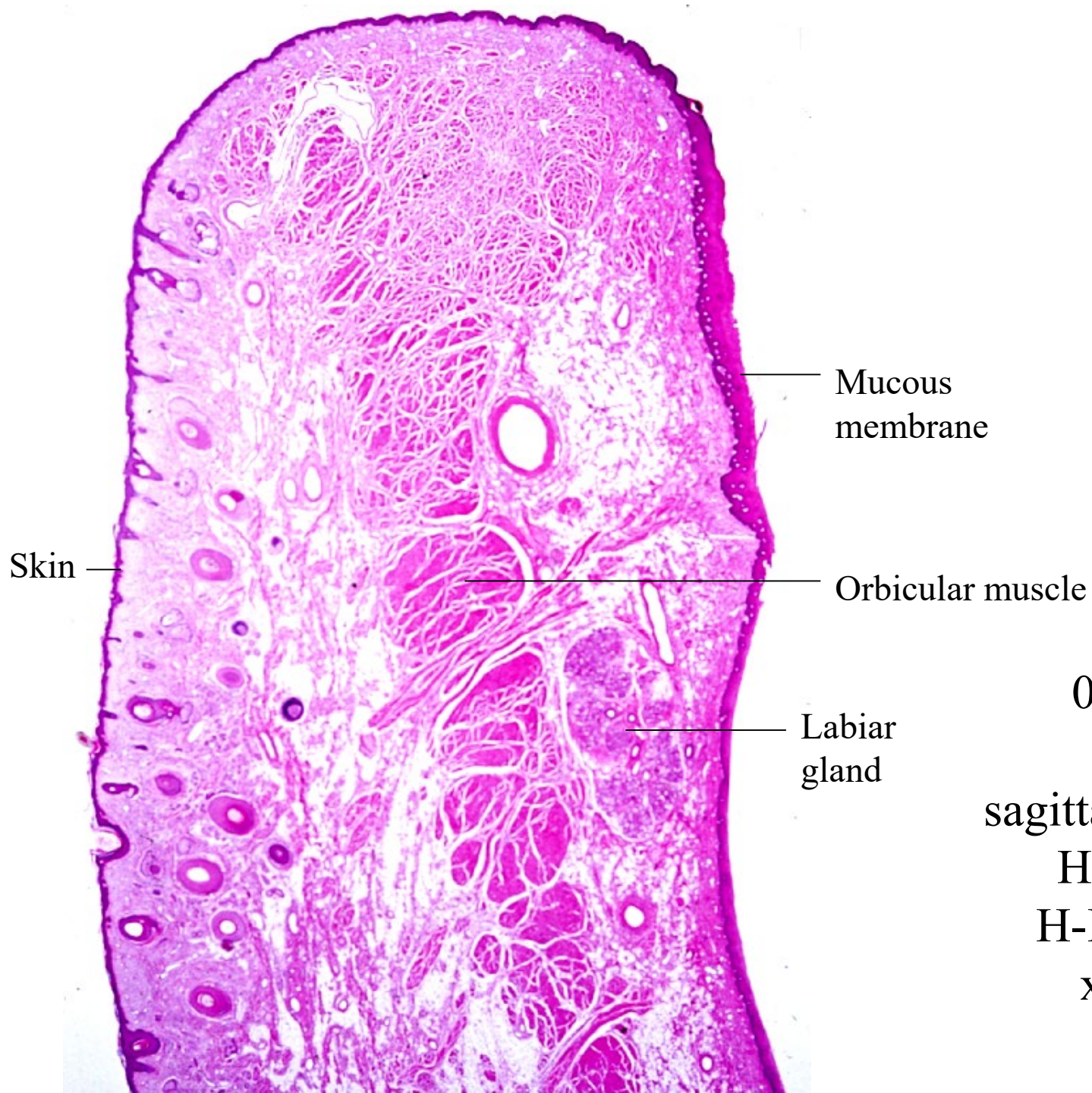


09-01. General structure of digestive organs (Scheme).

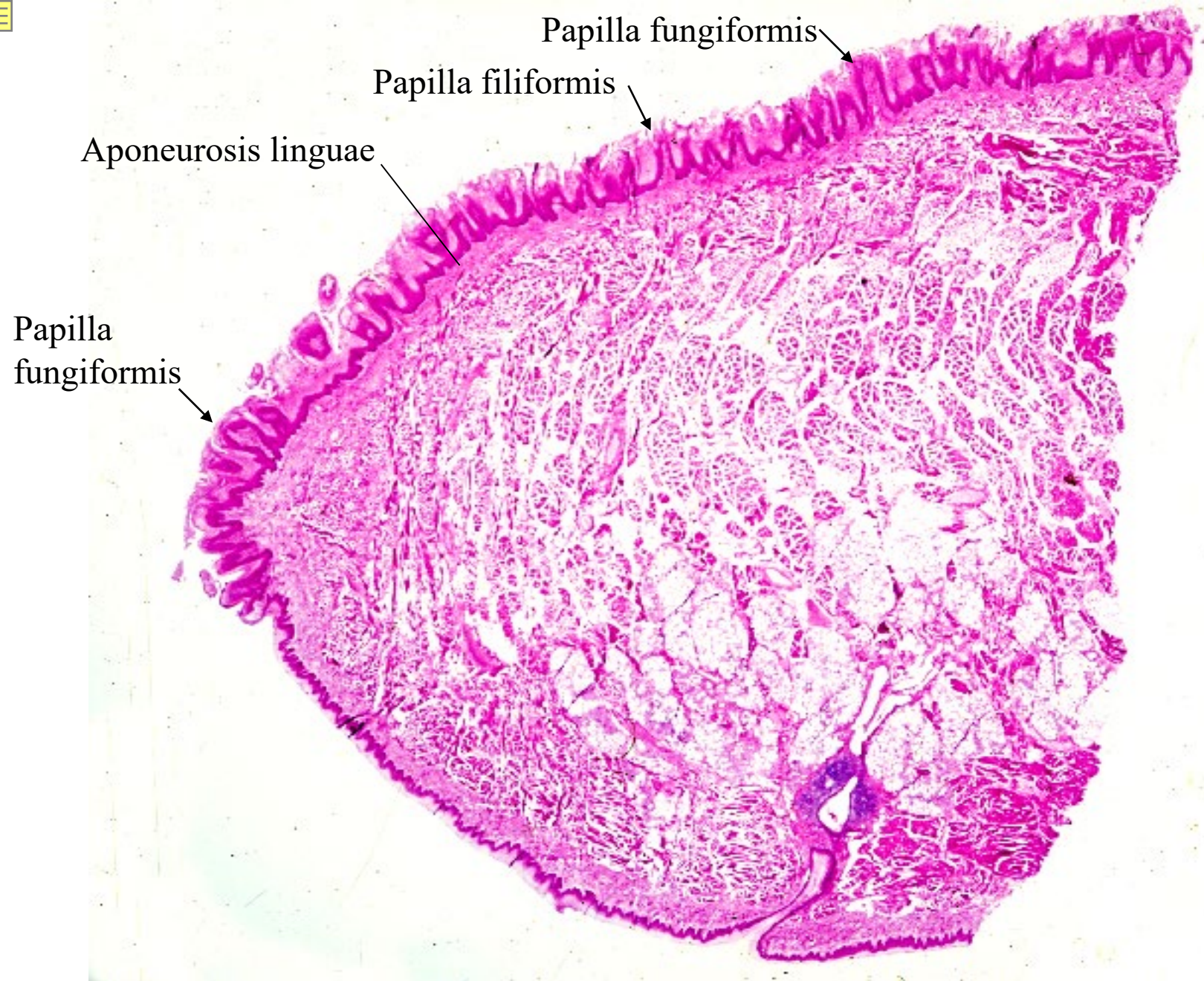


09-001

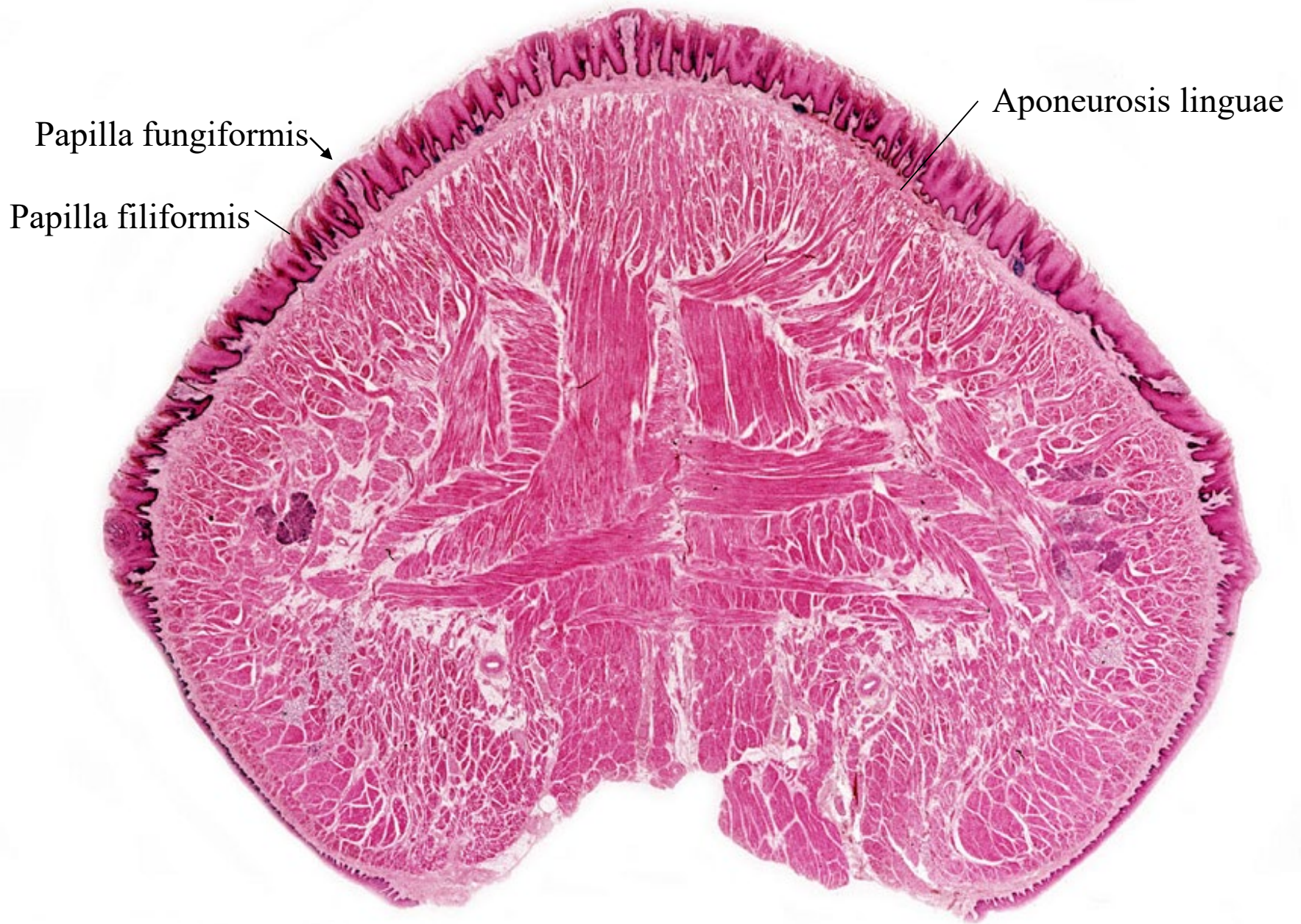
Oral Cavity



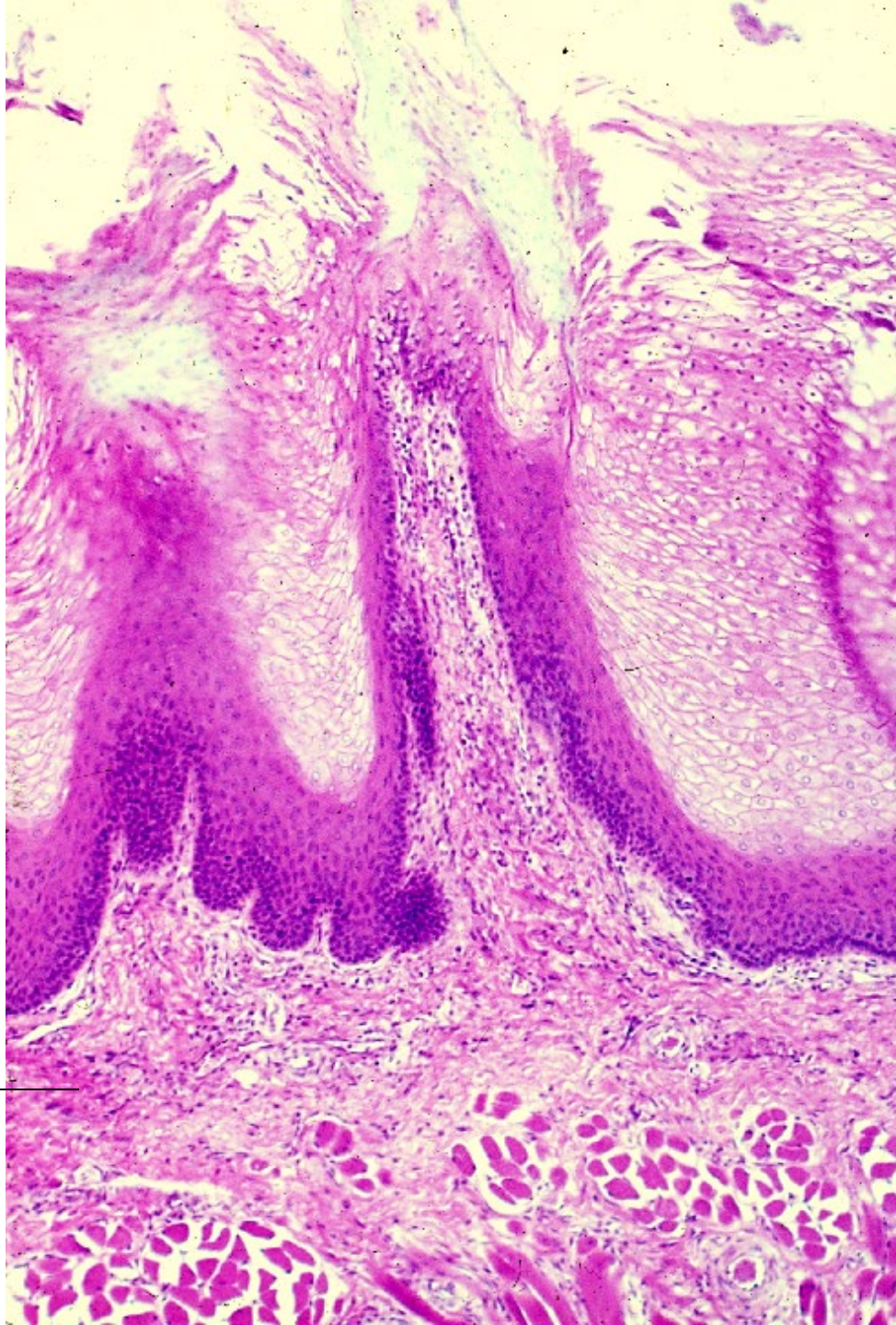
09-02.
Lip,
sagittal section.
Human,
H-E stain,
x 1.2.



09-03. Apex linguae, sagittal section. Human, H-E stain, x 1.7.

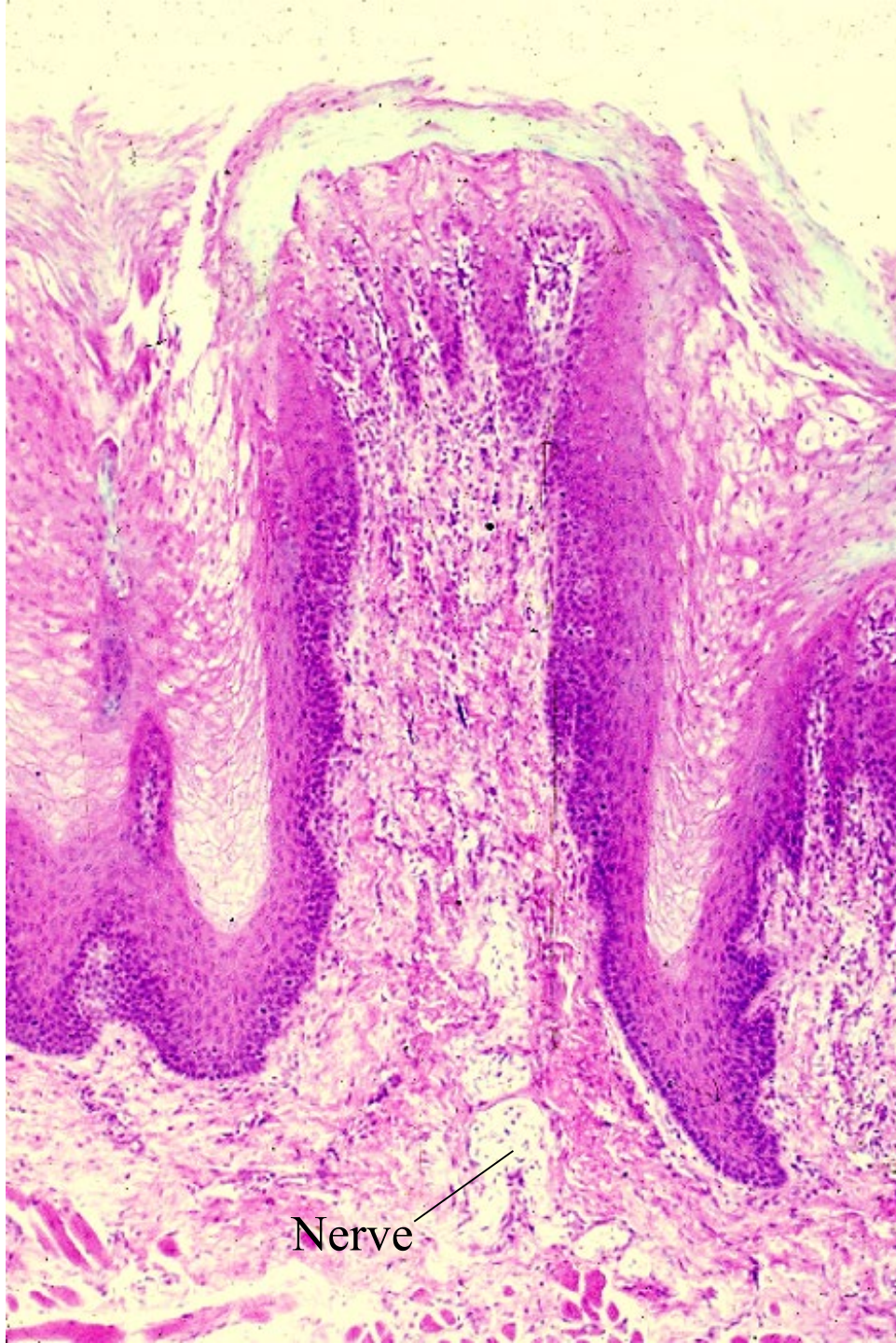


09-04. Corpus linguae, transverse section. Monkey, H-E stain, x 1.3.

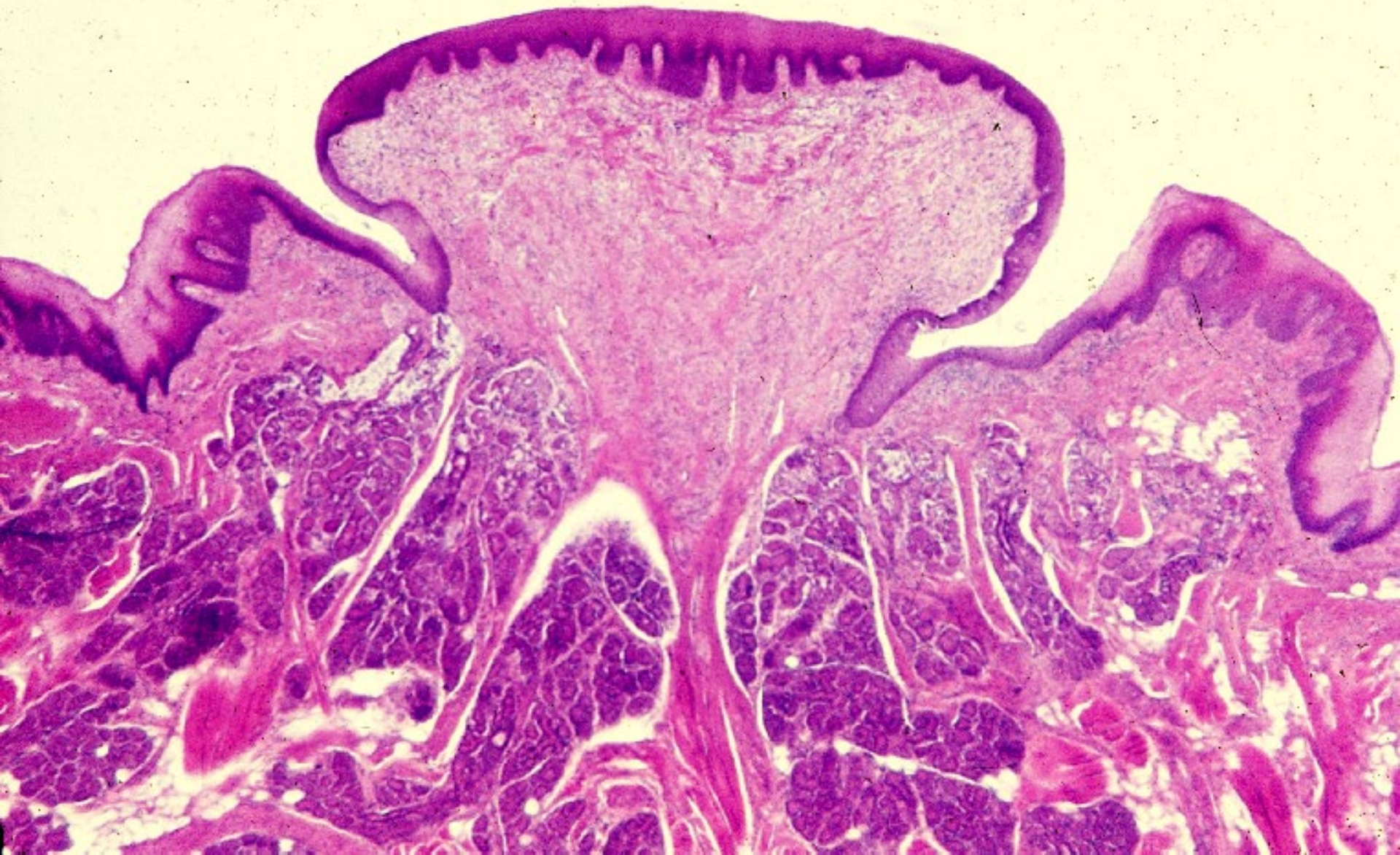


Aponeurosis
linguae

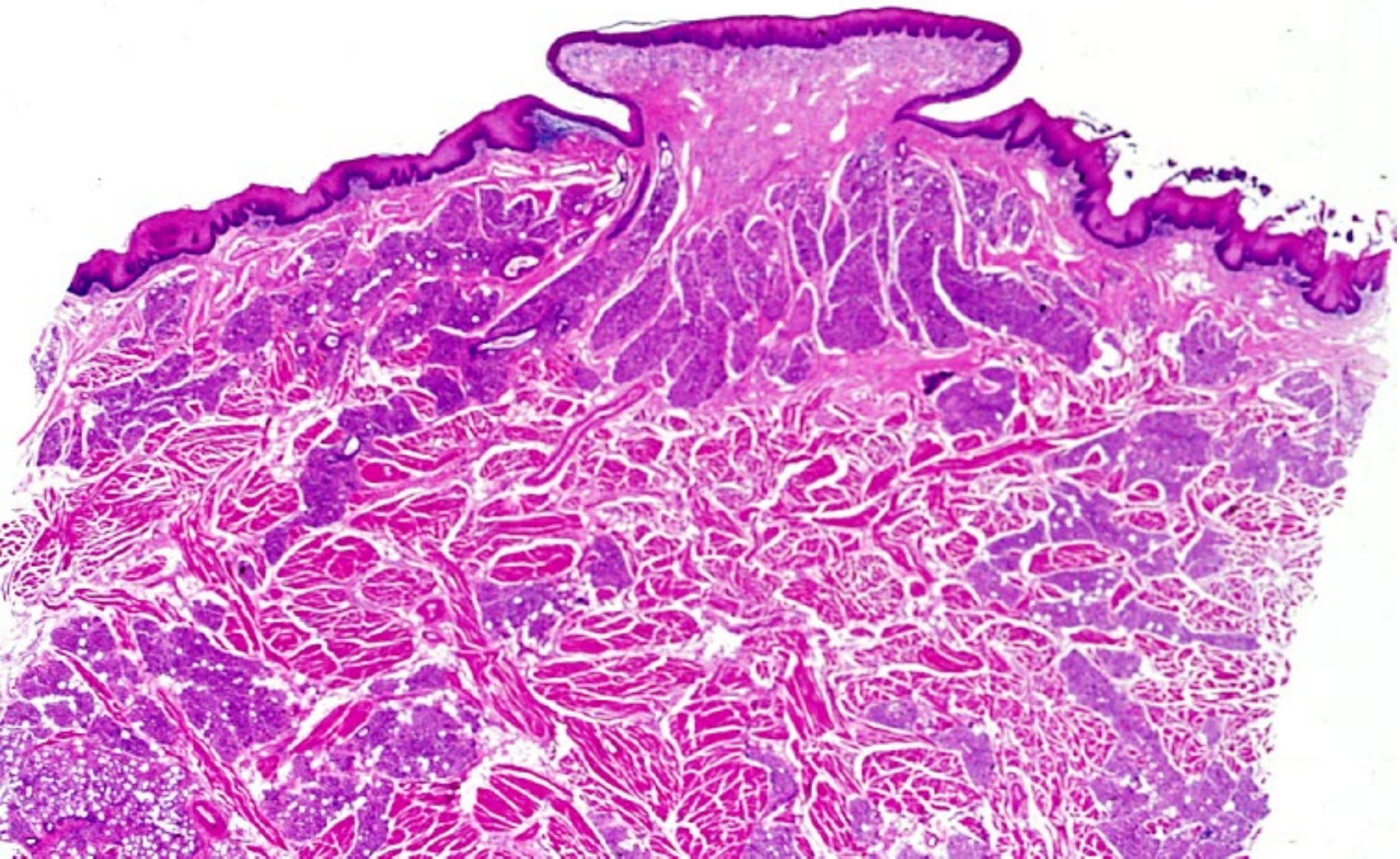
09-05.
Papilla filiformis
Human,
H-E stain,
x 25.



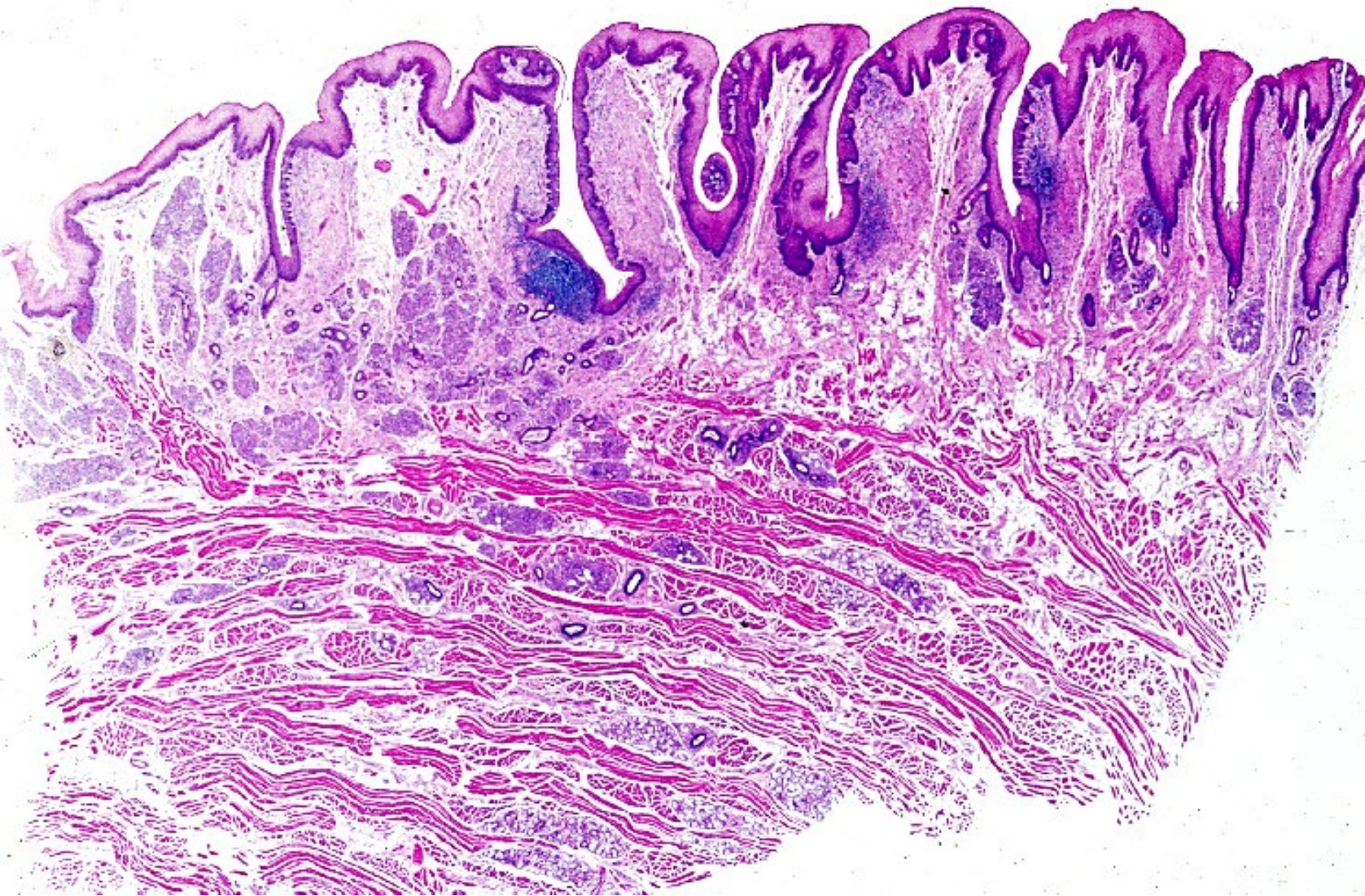
09-06.
Papilla fungiformis.
Human,
H-E stain,
x 25.



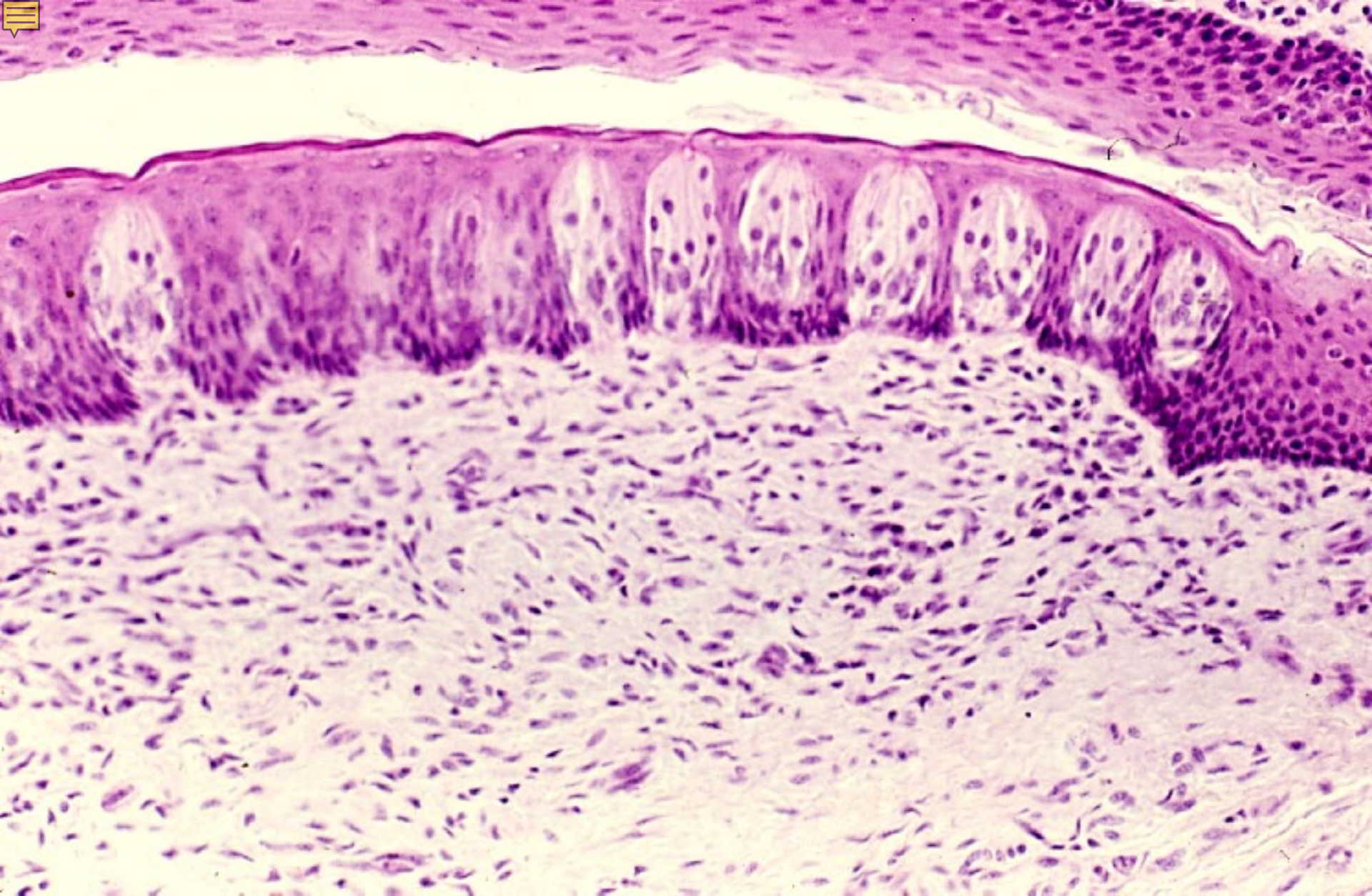
09-07. Papilla vallata 1. Human, H-E stain, x 4.



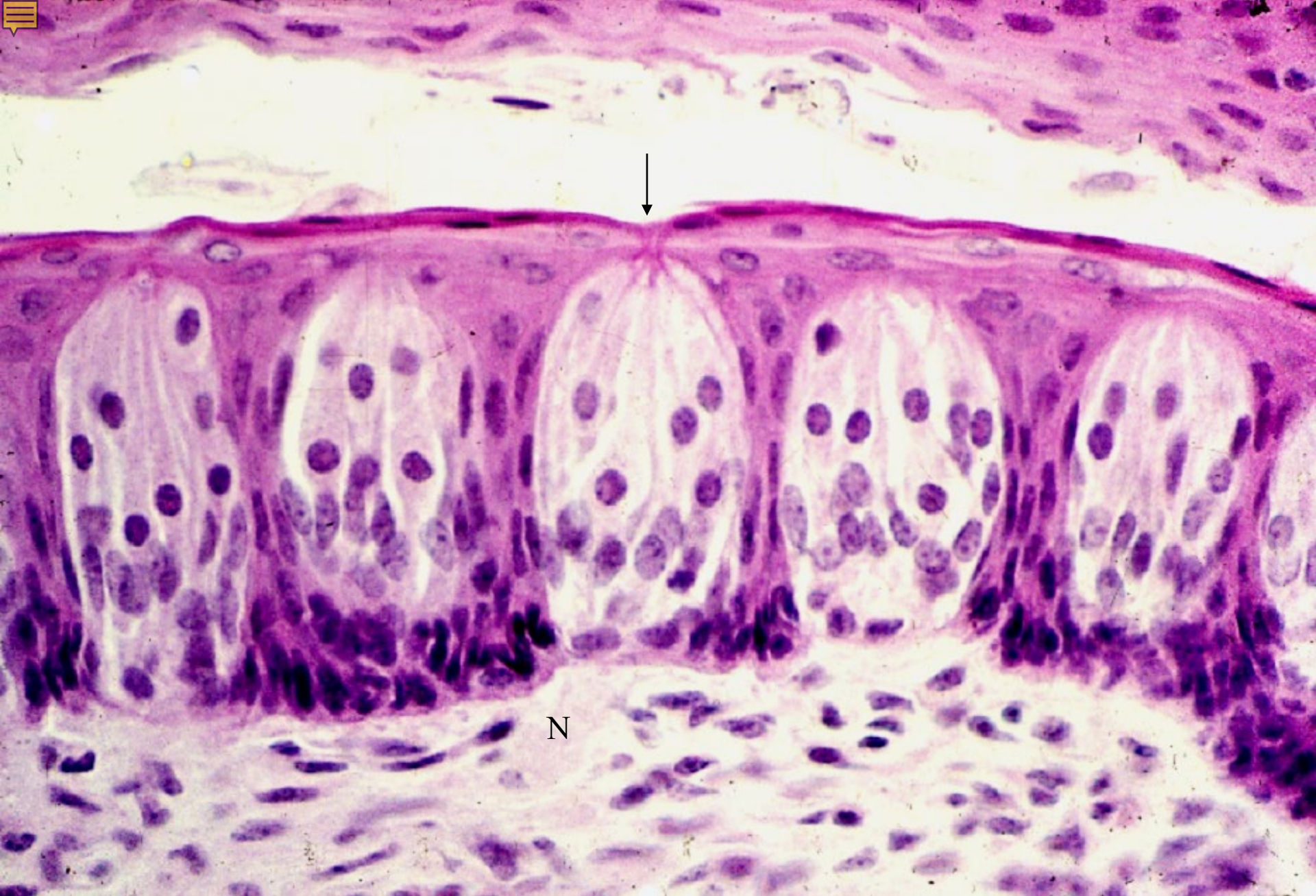
09-08. Papilla vallata 2. Human, H-E stain, x 3.



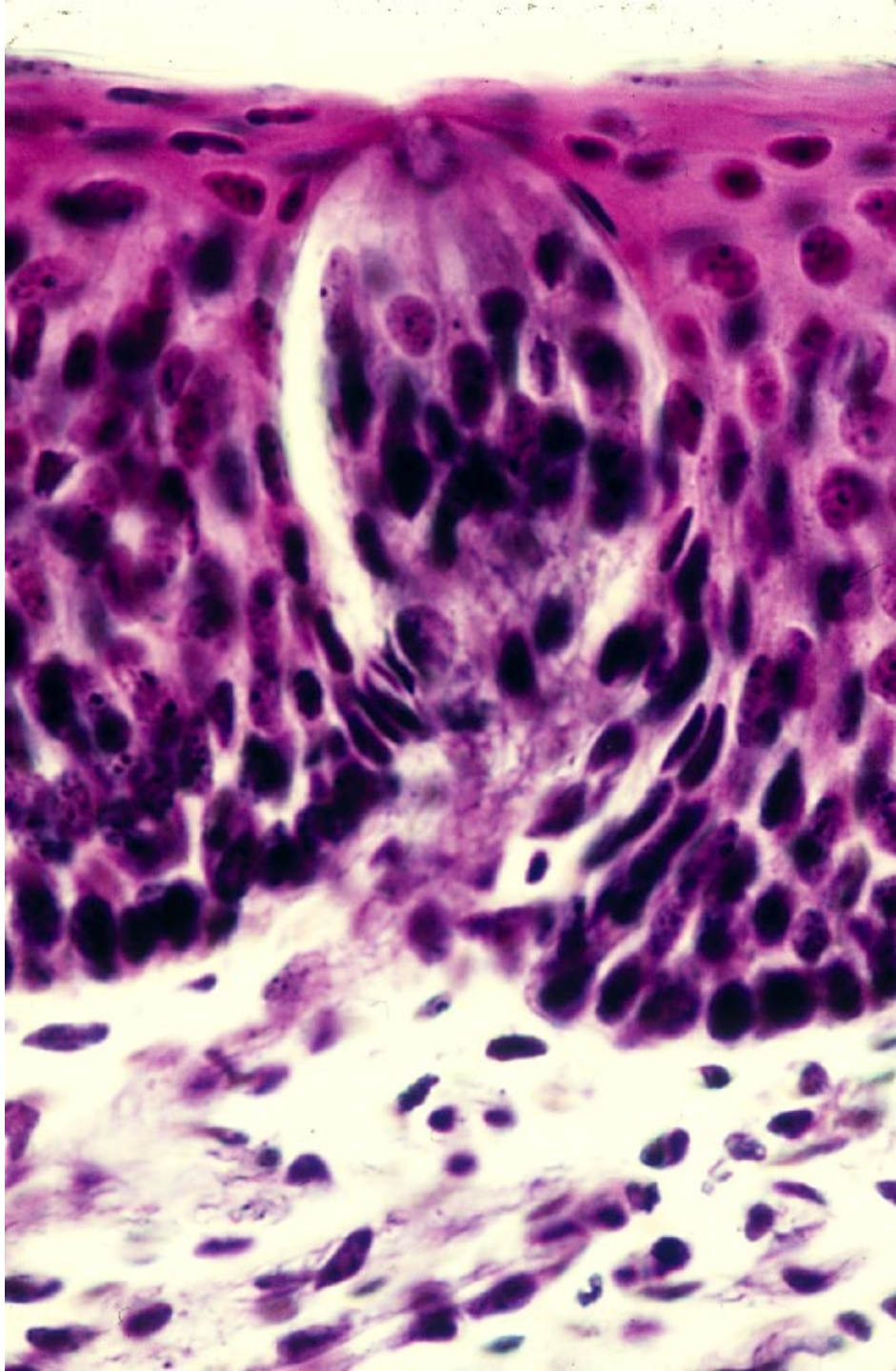
09-09. Papillae foliatae. Human, H-E stain, x 3.



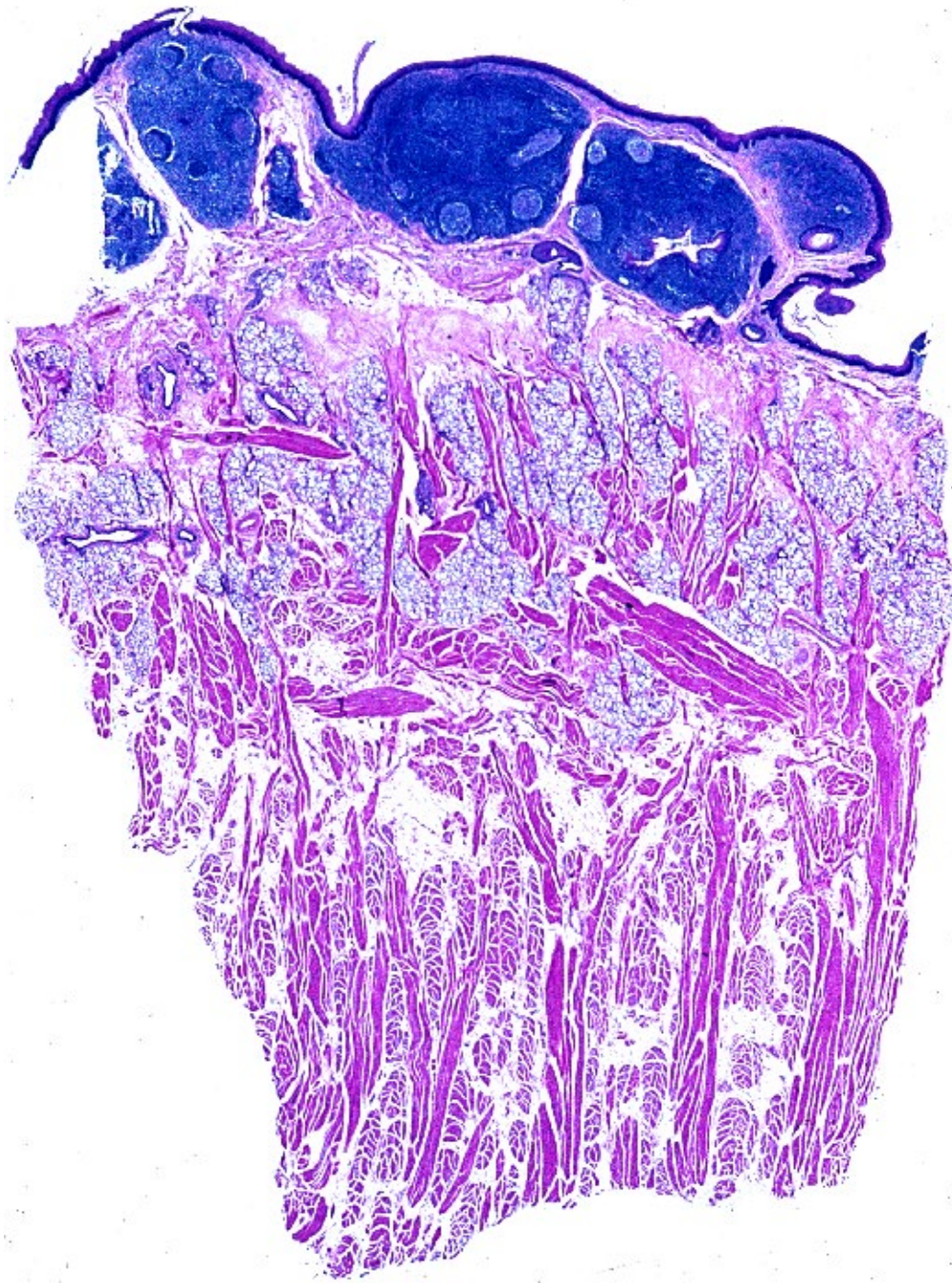
09-10. Taste buds 1. Monkey, H-E stain, x 64.



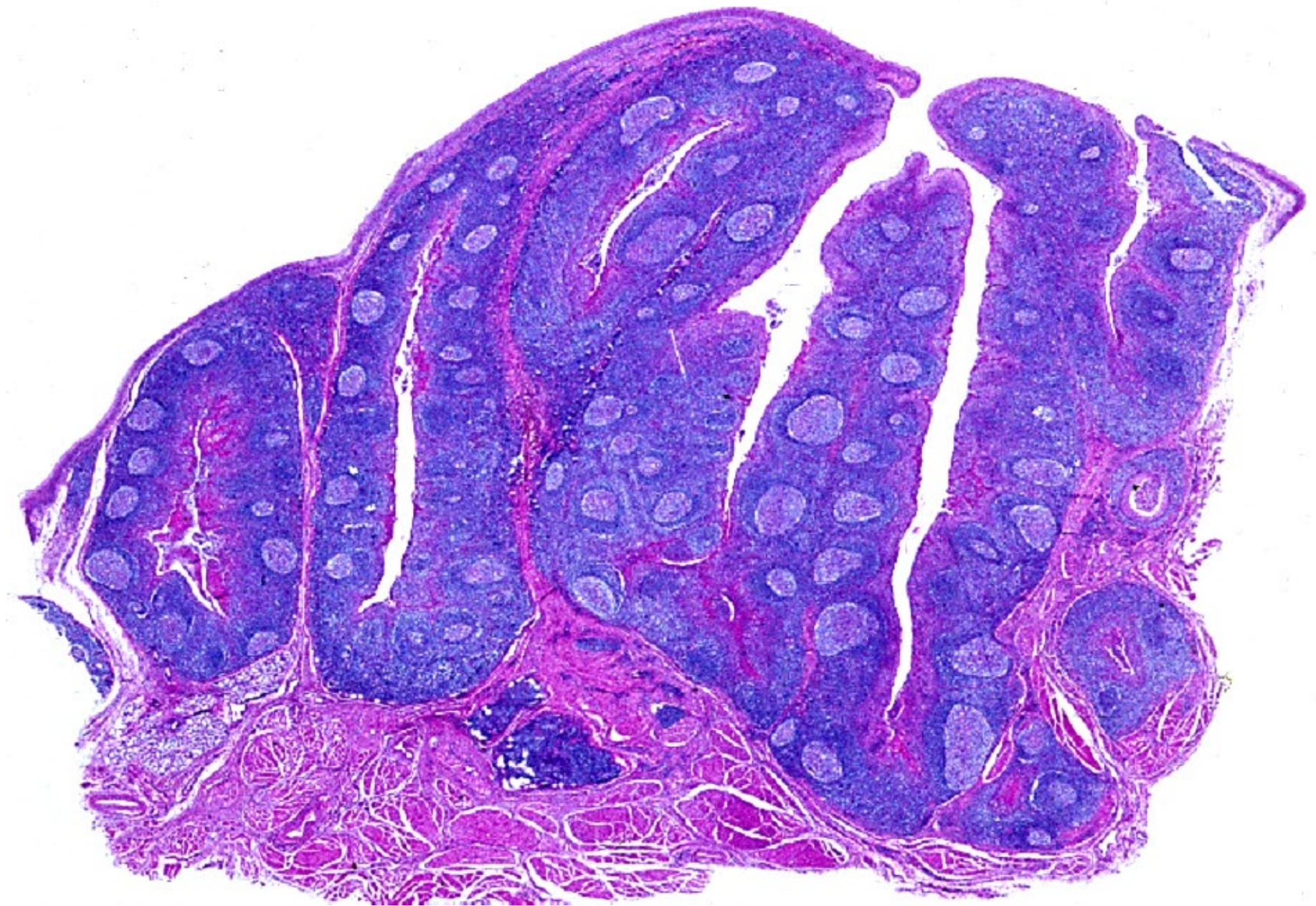
09-11. Taste buds 2. Monkey, H-E stain, x 160.



09-12.
Taste bud 3.
Human,
Silver impregnation,
x 200.



09-13.
Radix
linguae,
tonsilla
lingualis.
Human,
H-E stain,
x 2.



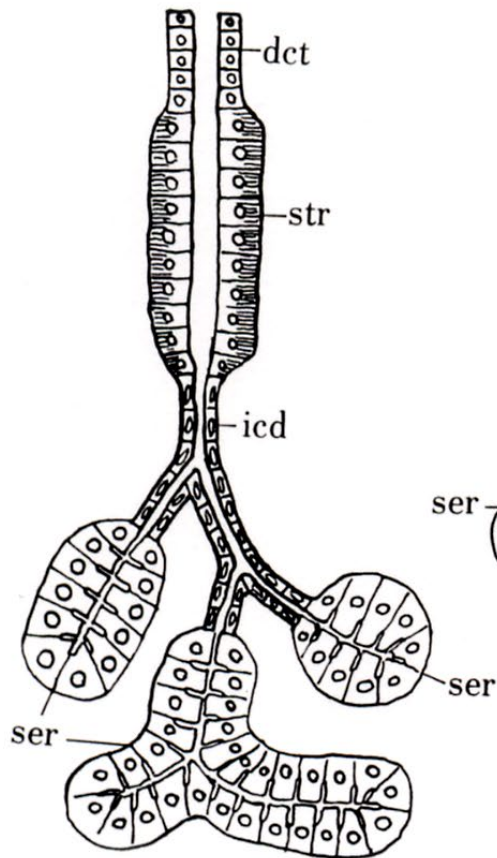
09-14. Tonsilla palatina. Human, H-E stain, x 2.



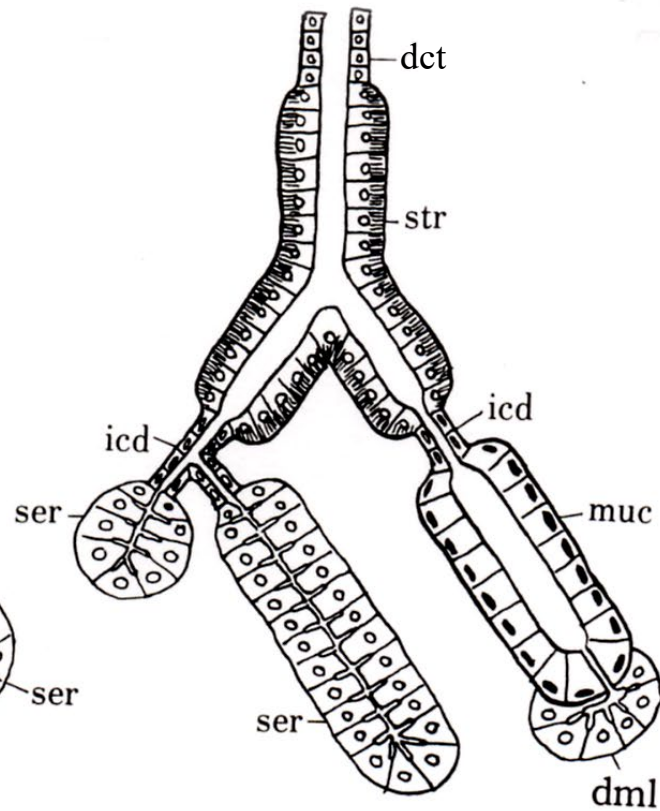
09-002

Salivary Glands

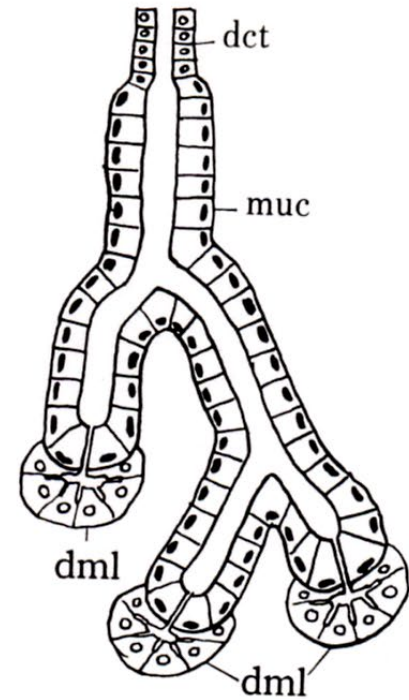
Gl. parotis



Gl. submandibularis



Gl. sublingualis

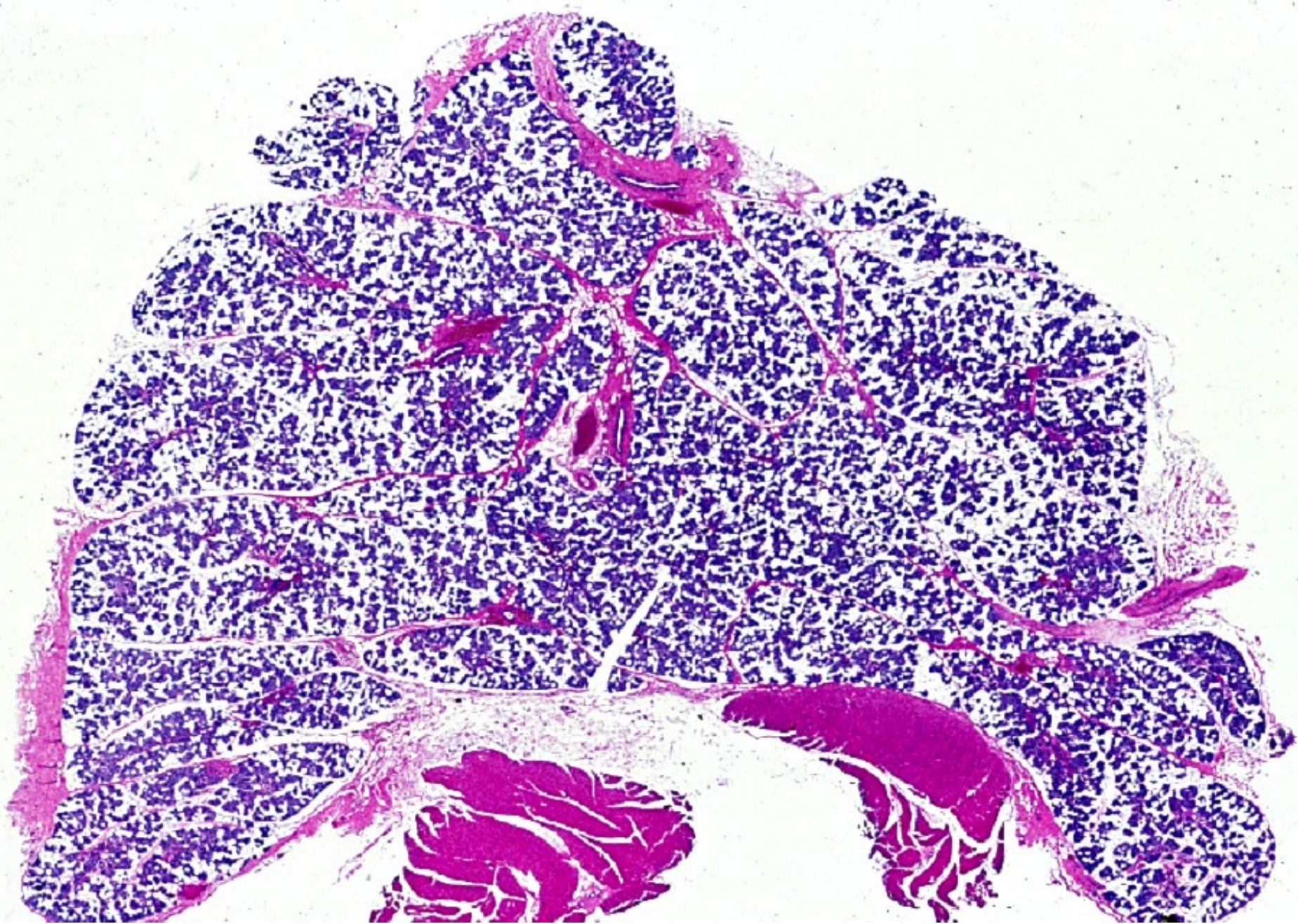


09-15. Structure of 3 large salivary glands (Scheme).

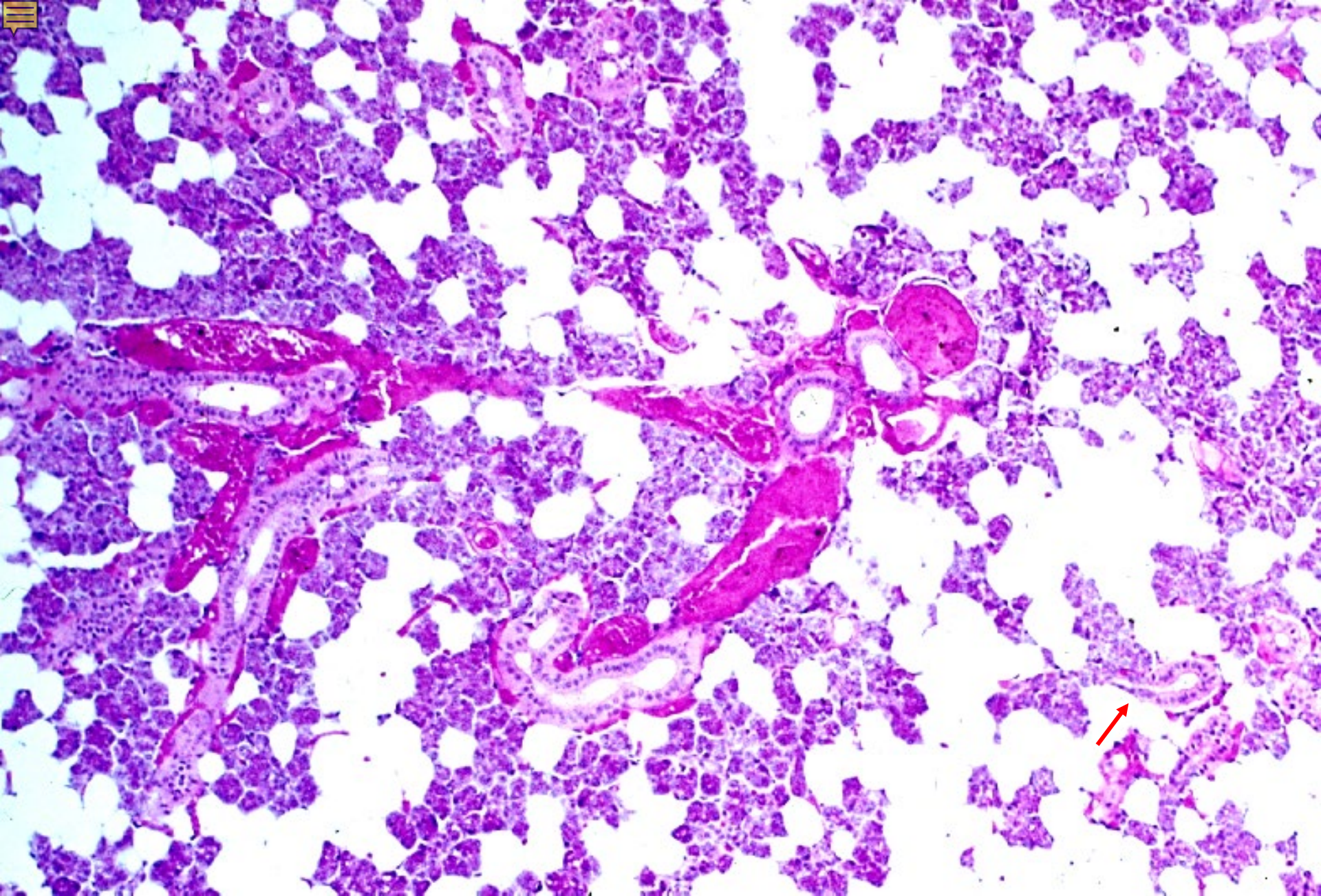


09-0021

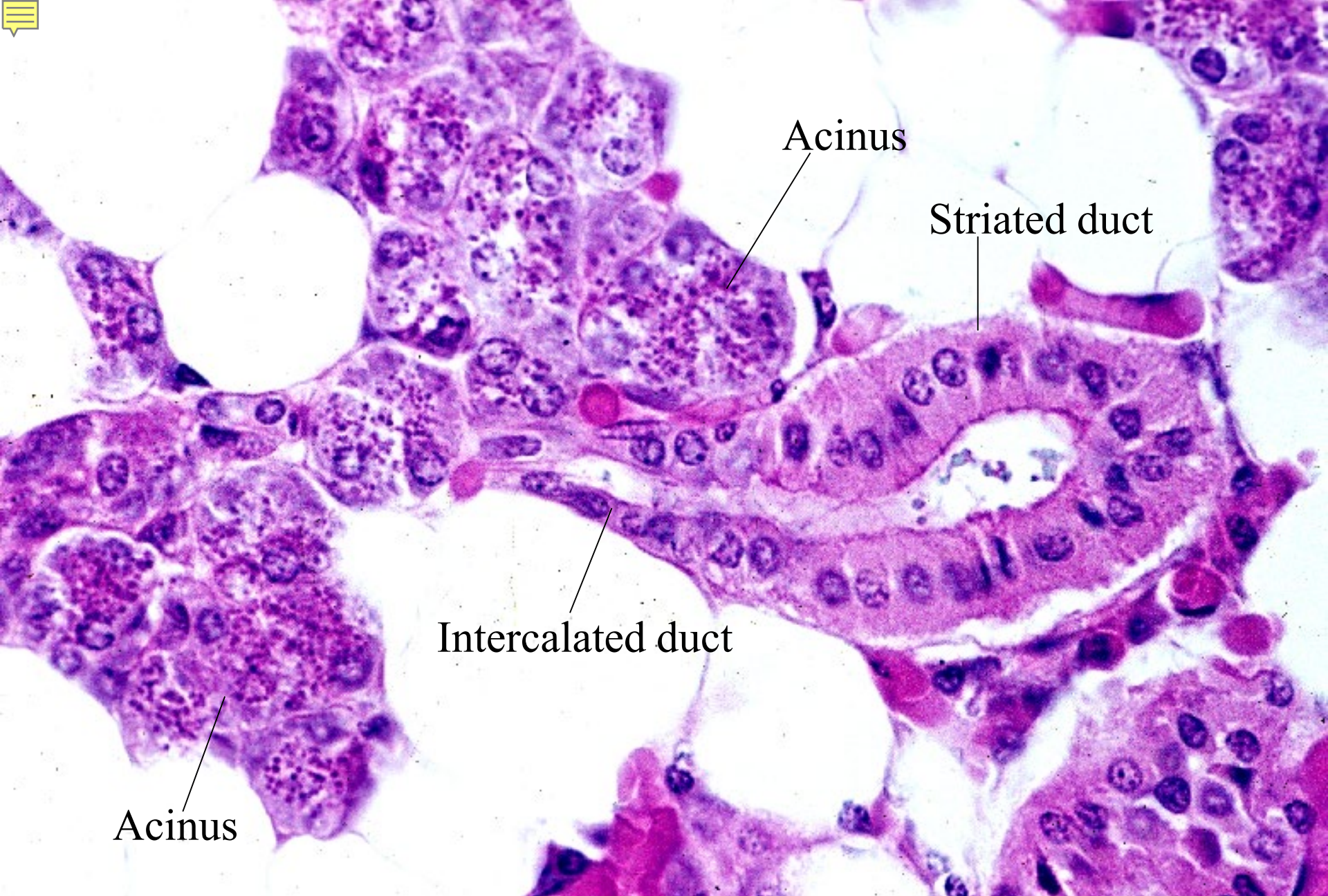
Gl. parotis



09-16. Gl. parotis 1. General view. Human, H-E stain, x 2.2.



09-17. Gl. parotis 2. Human, H-E stain, x 25.



Acinus

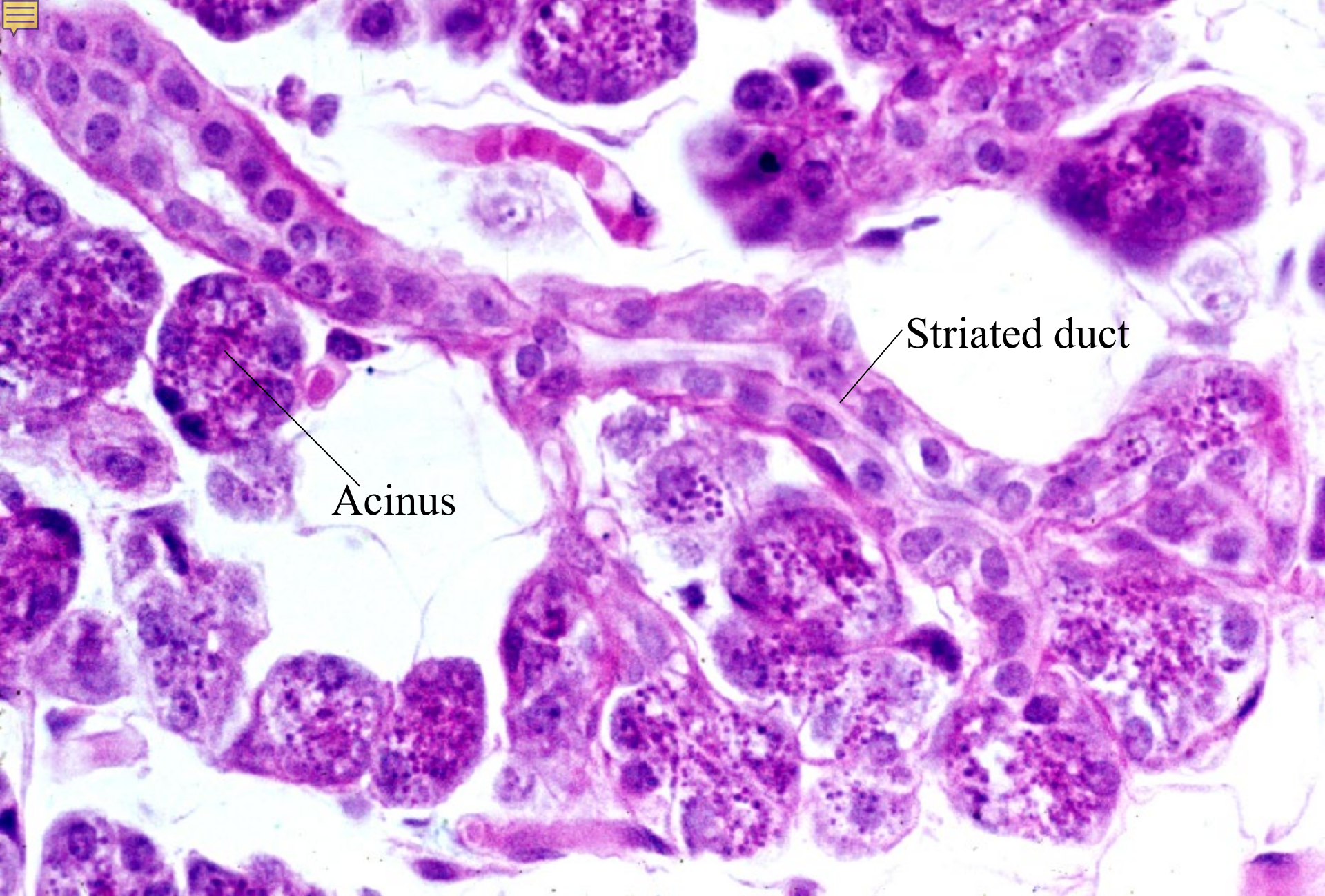
Striated duct

Intercalated duct

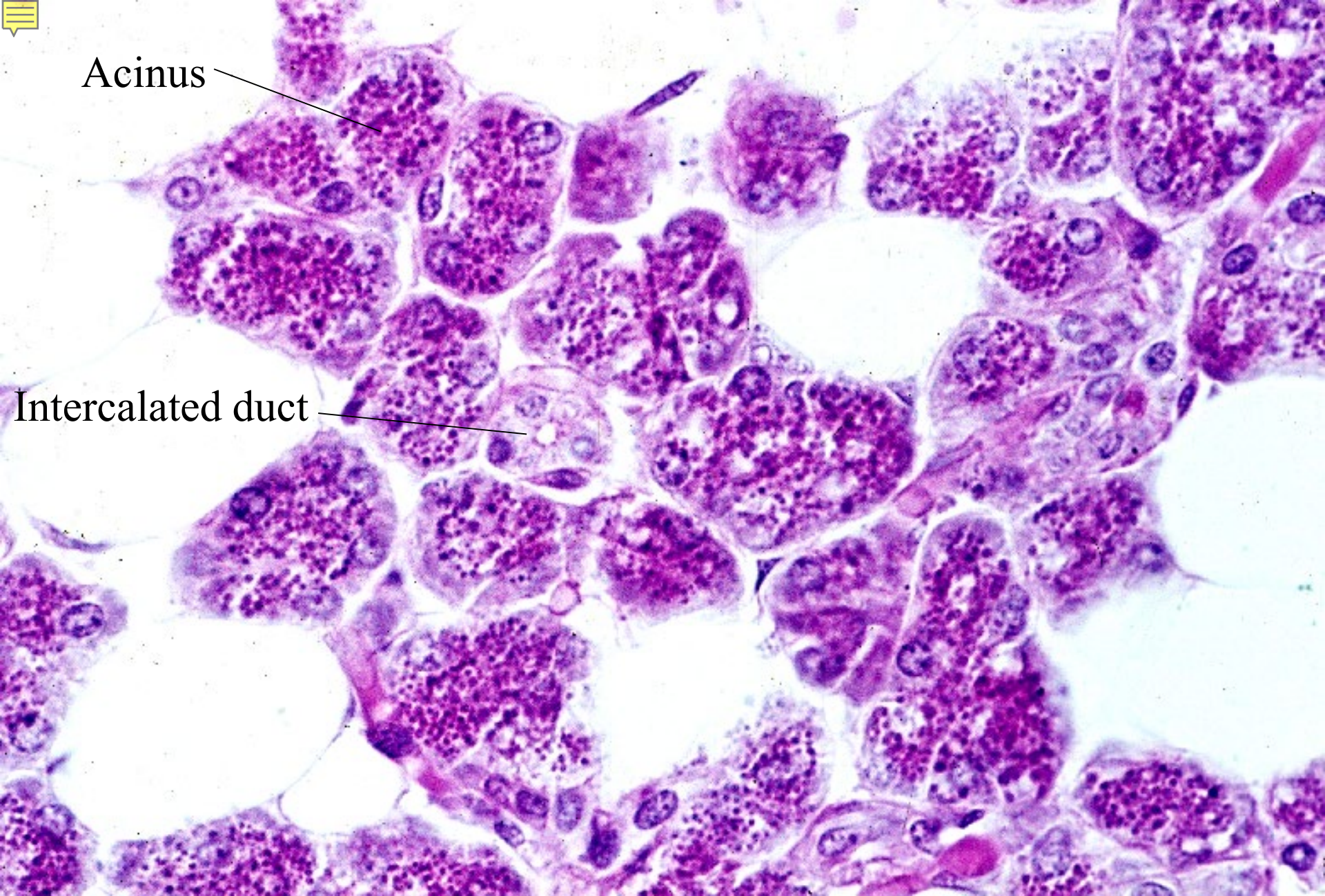
Acinus

09-18. Gl. parotis 3. Intercalated duct and striated duct.

Human, H-E stain, x 160.



09-19. Gl. parotis 4. Intercalated duct, longitudinal section.
Human. H-E stain. x 160.

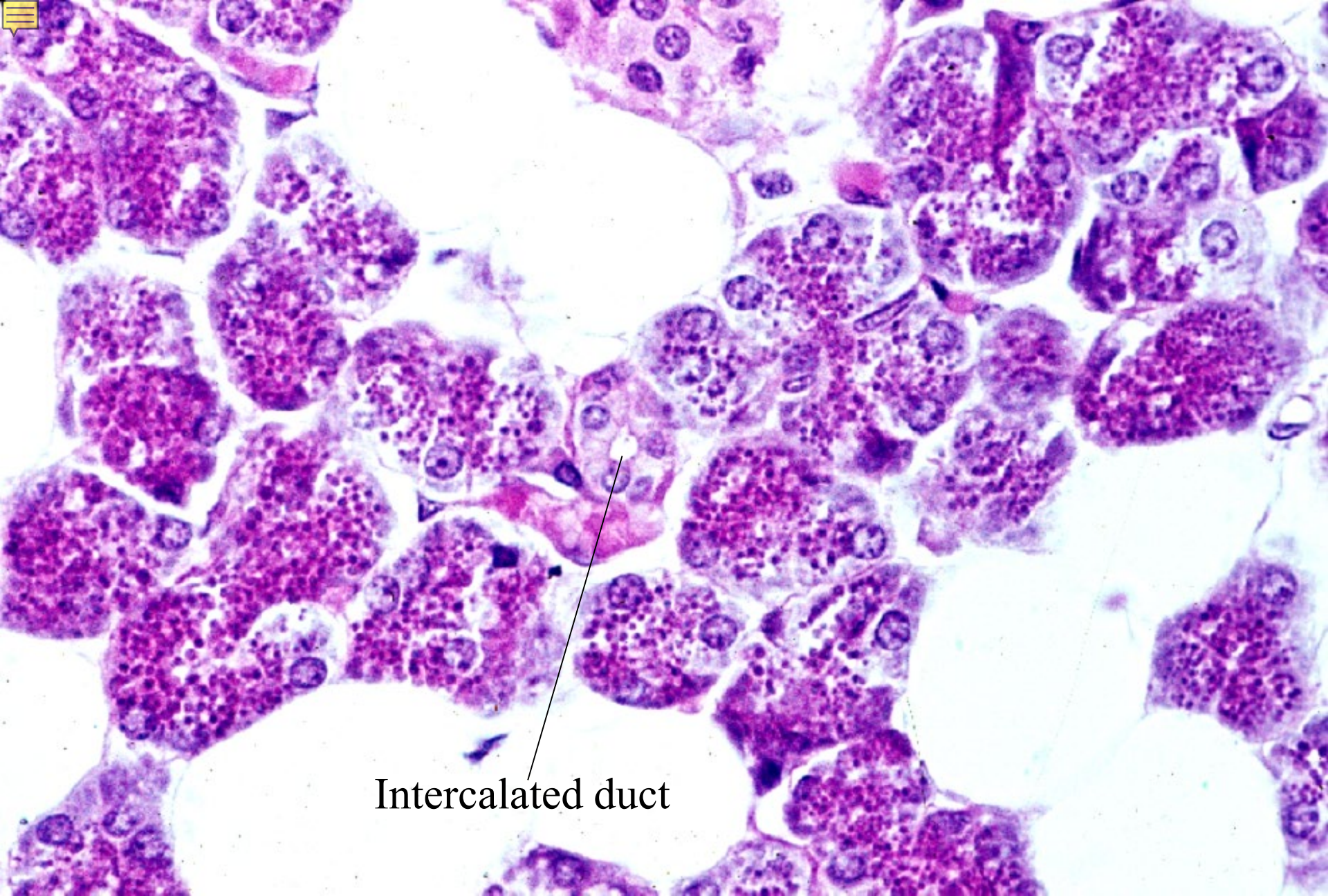


Acinus

Intercalated duct

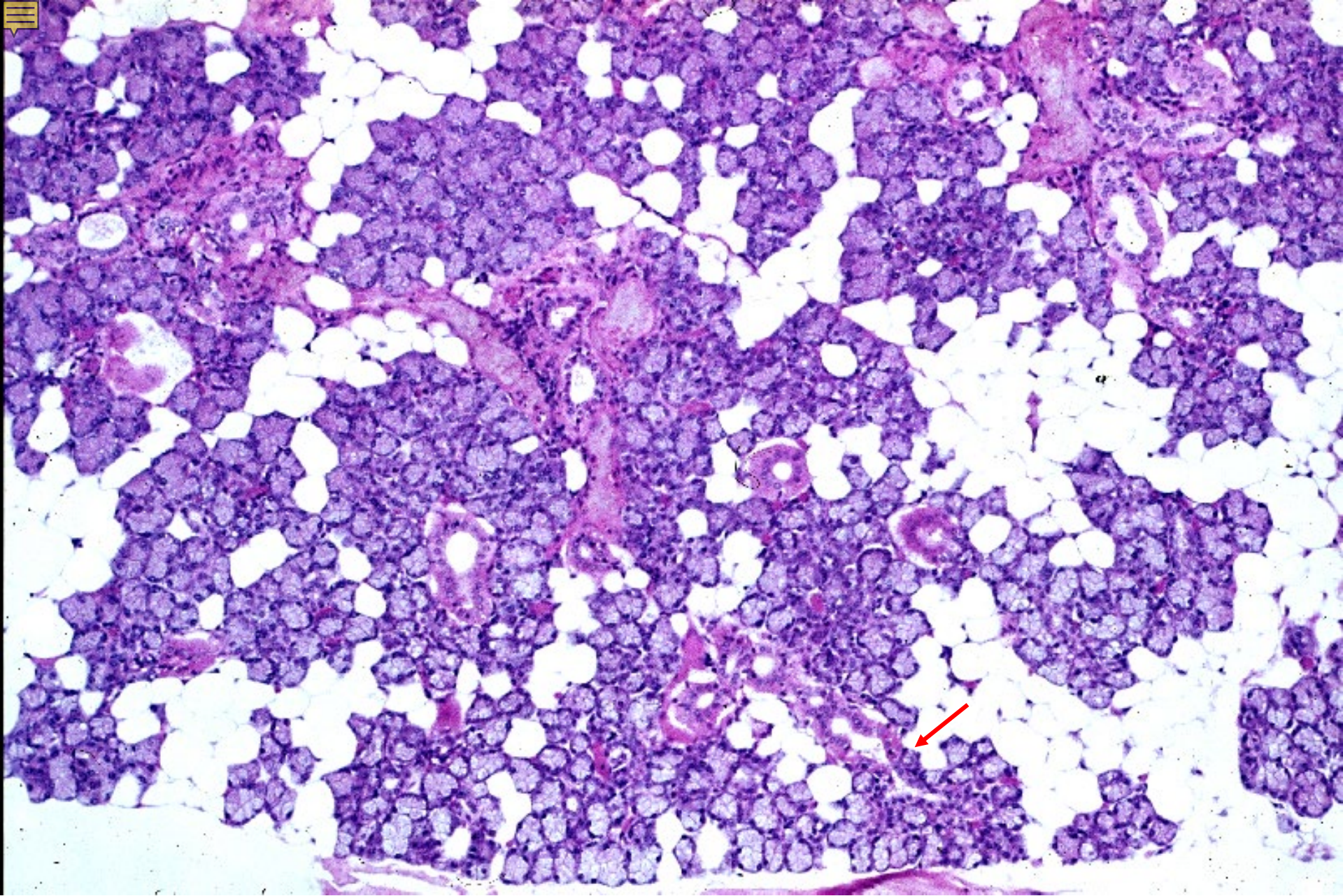
09-20. Gl. parotis 5. Intercalated duct, transverse section.

Human. H-E stain. x 160.

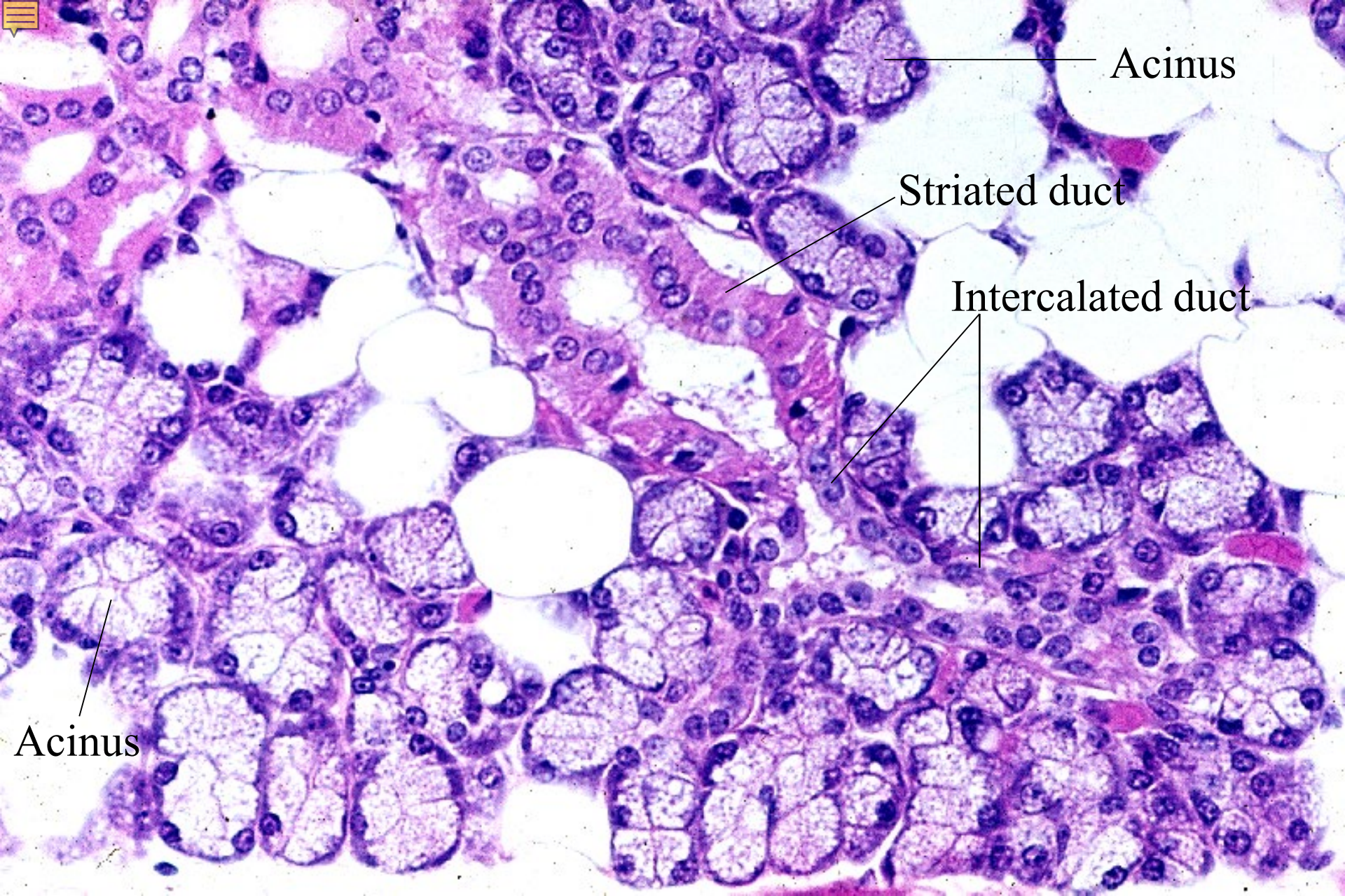


Intercalated duct

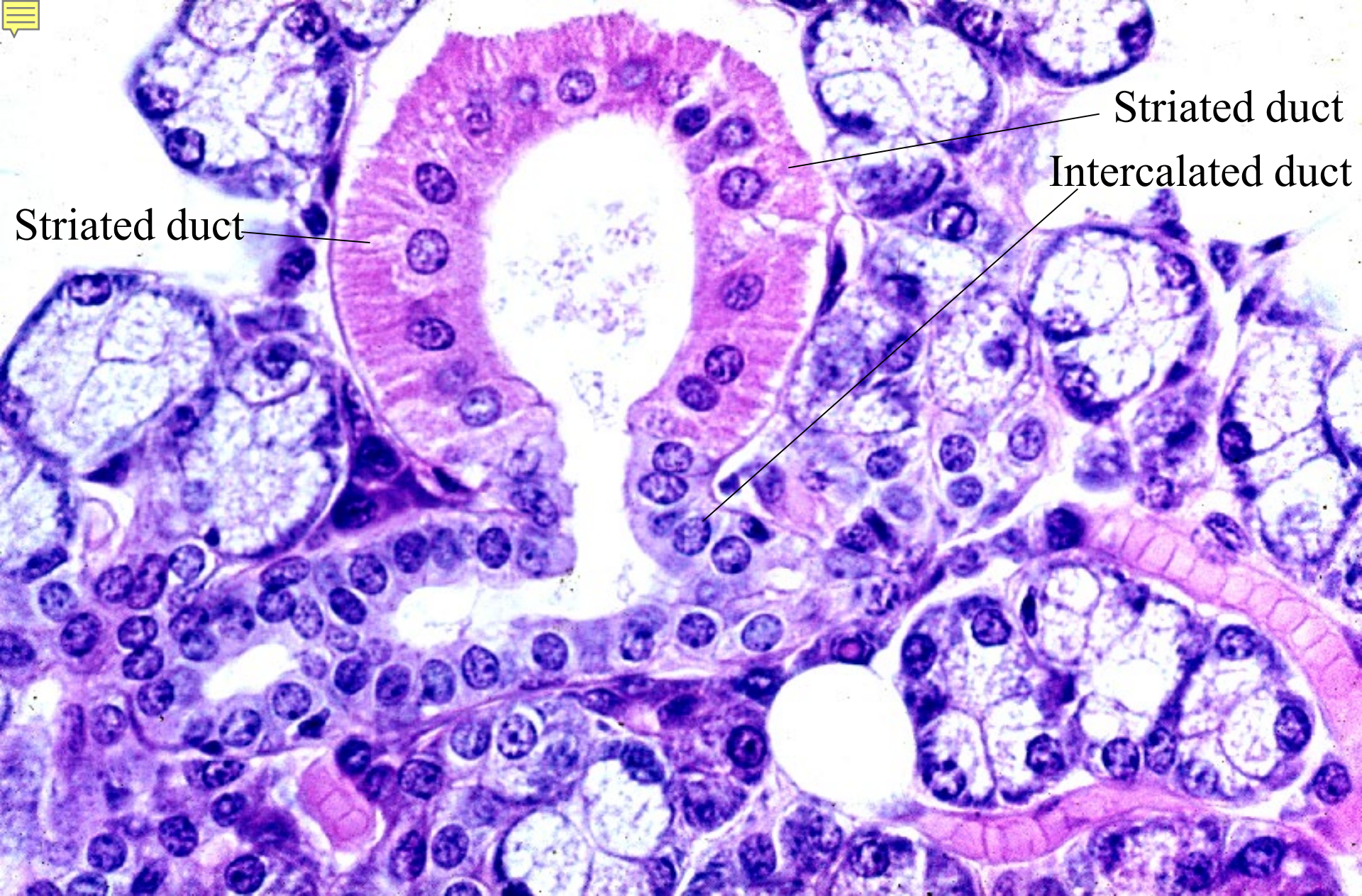
09-21. Gl. parotis 6. Intercalated duct, transverse section.
Human, H-E stain, x 160.



09-22. Gl. parotis 7. General view. Human, H-E stain, x 25.

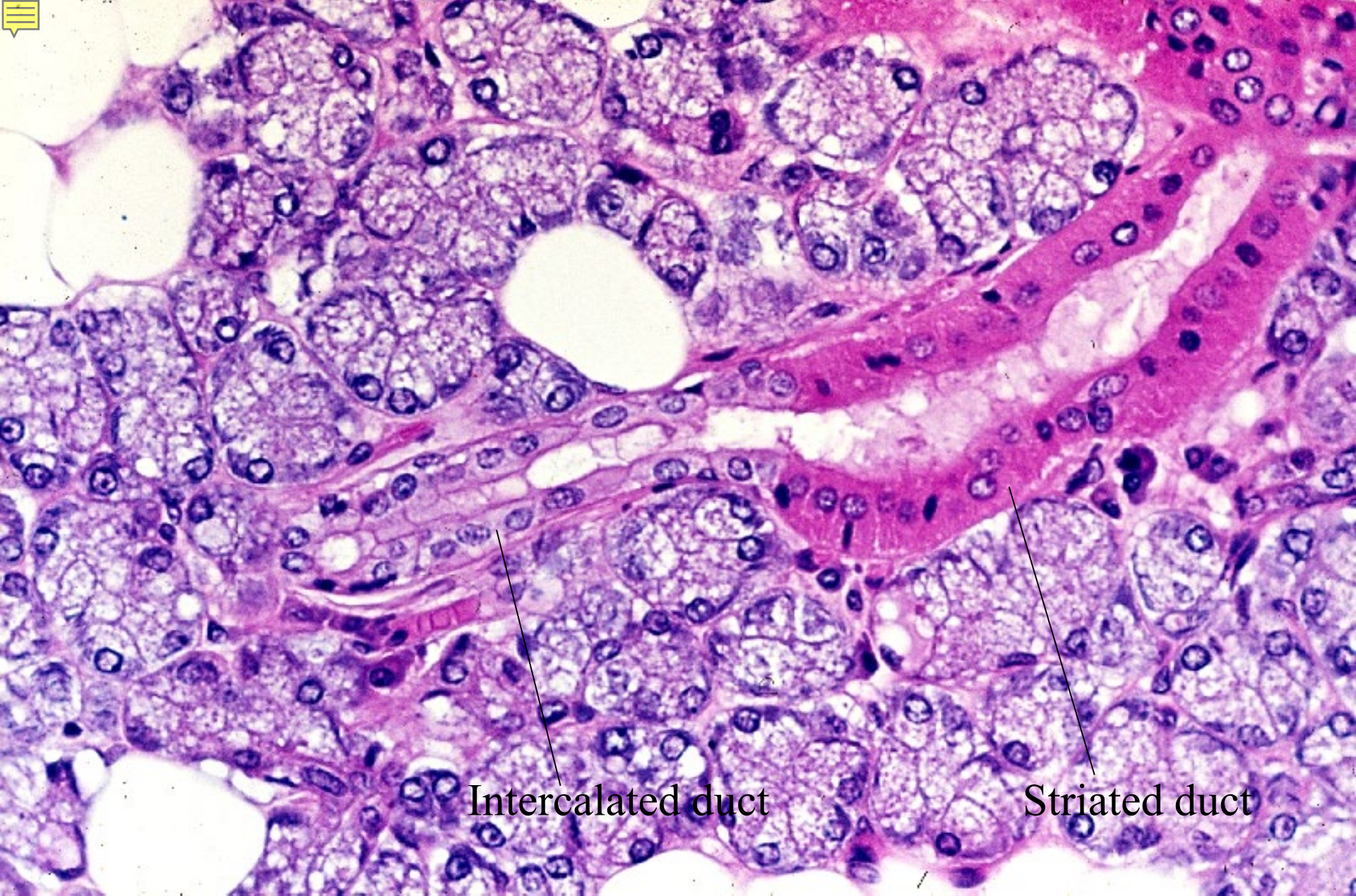


09-23. Gl. parotis 8. Intercalated duct & striated duct.
Human, H-E stain, x 100.

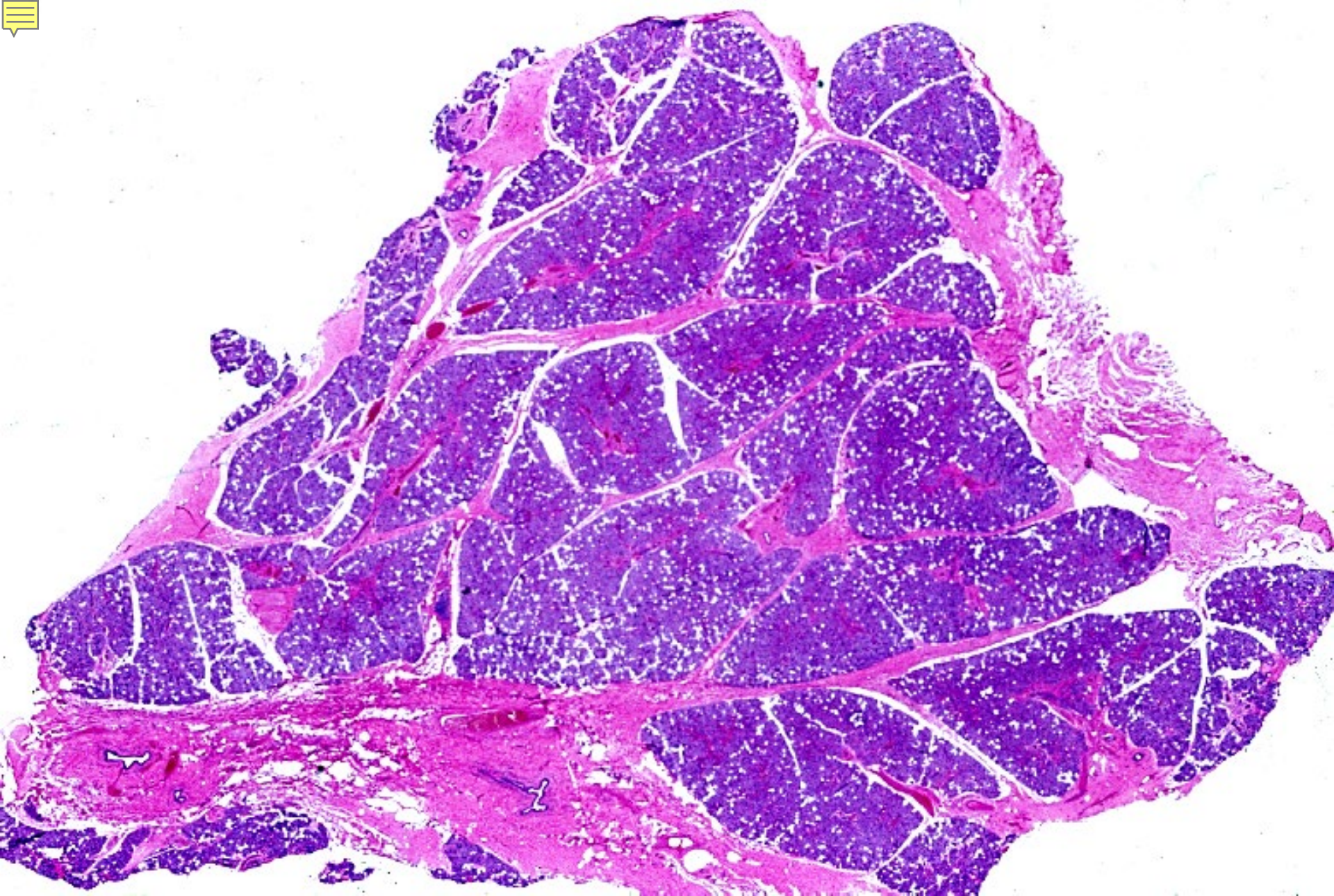


09-24. Gl. parotis 9. Intercalated duct and striated duct.

Human, H-E stain, x 160.



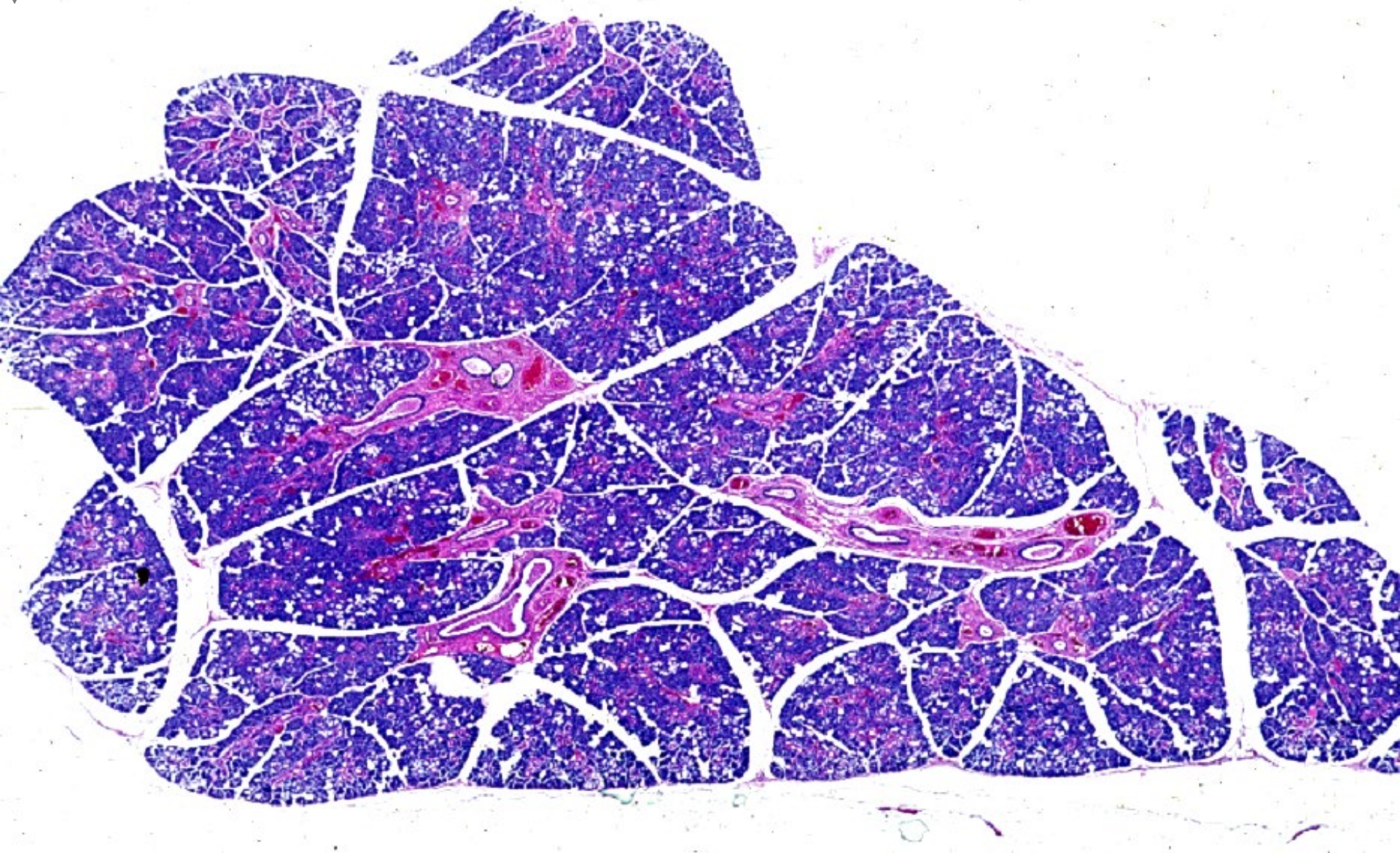
09-25. Gl. parotis 10. Intercalated duct and striated duct.
Human, H-E stain, x 100.



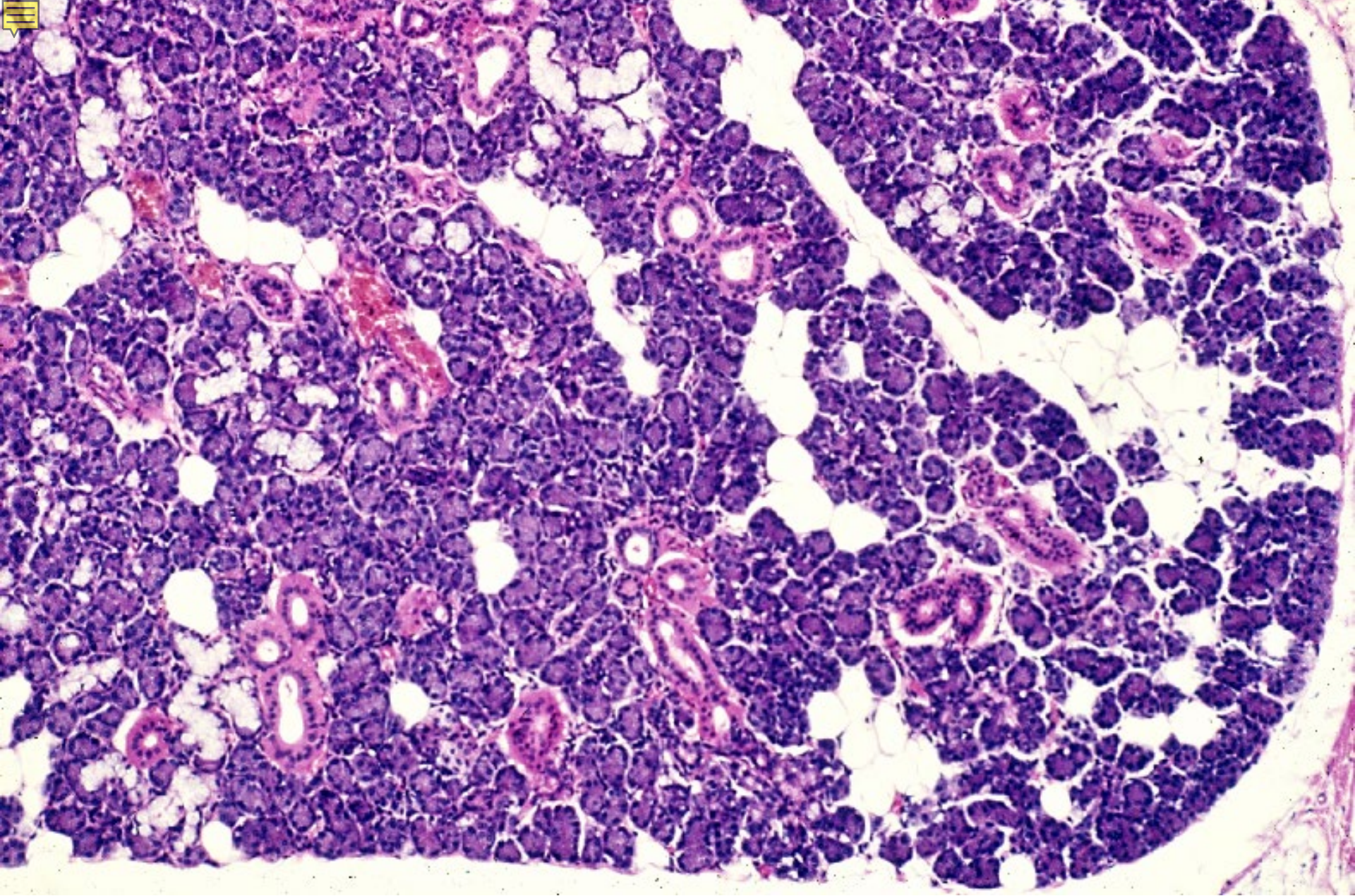
09-26. Gl. parotis 11, containing less fat cells.
Human, H-E stain, x 2.2.

09-0022

Gl. submandibularis

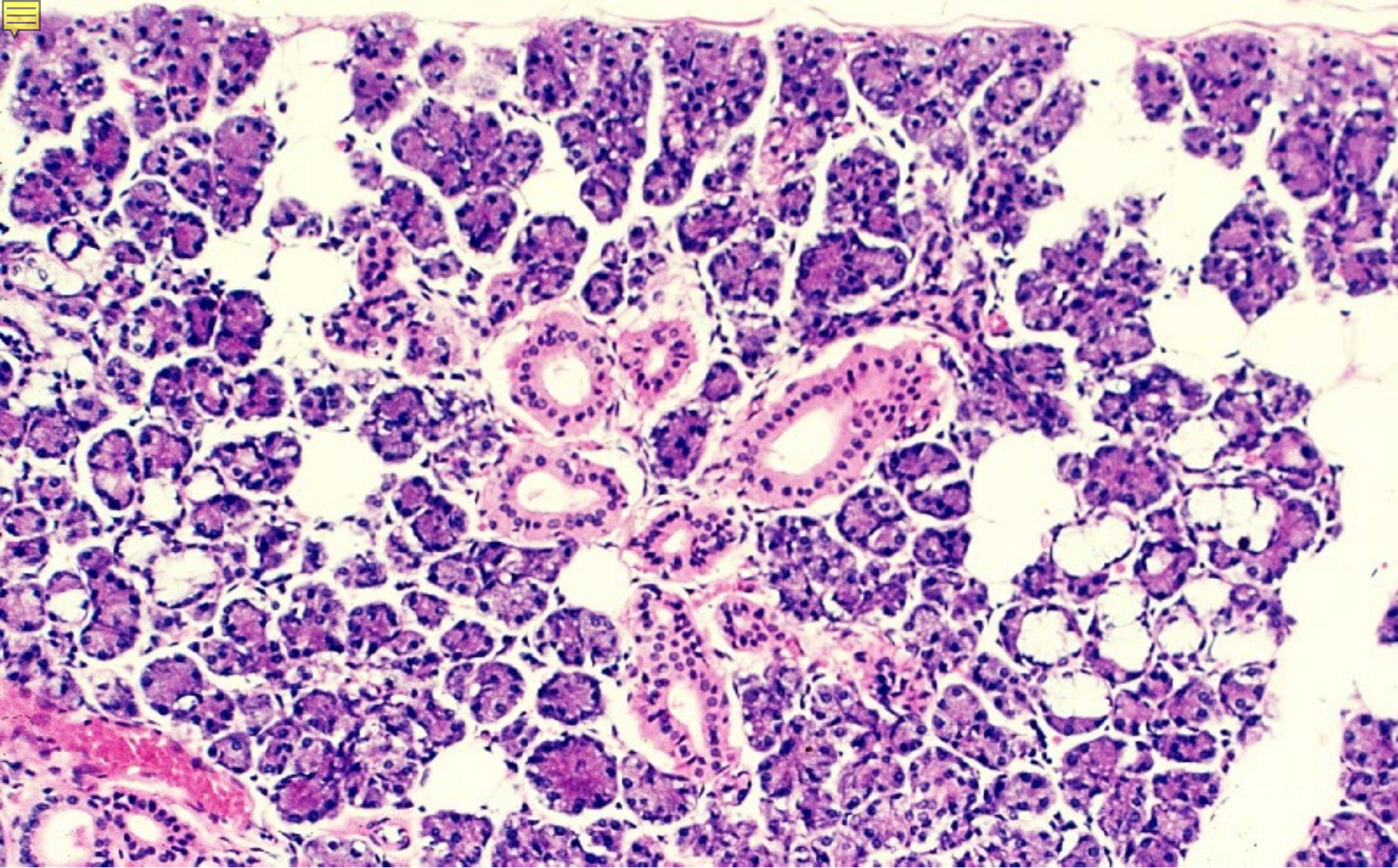


09-27. Gl. submandibularis 1. General view.
Human, H-E stain, x 2.5.

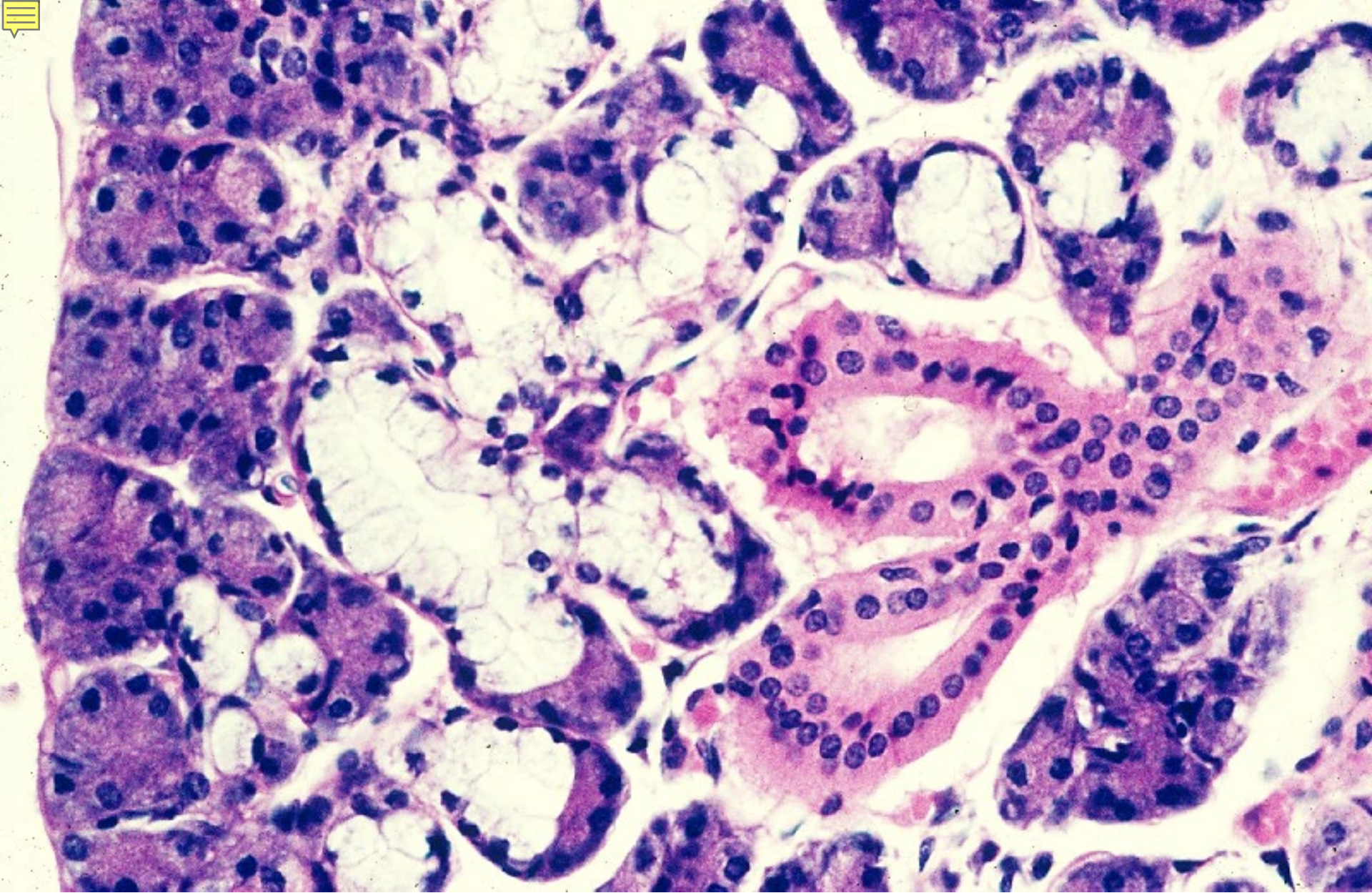


09-28. Gl. submandibularis 2. General view.

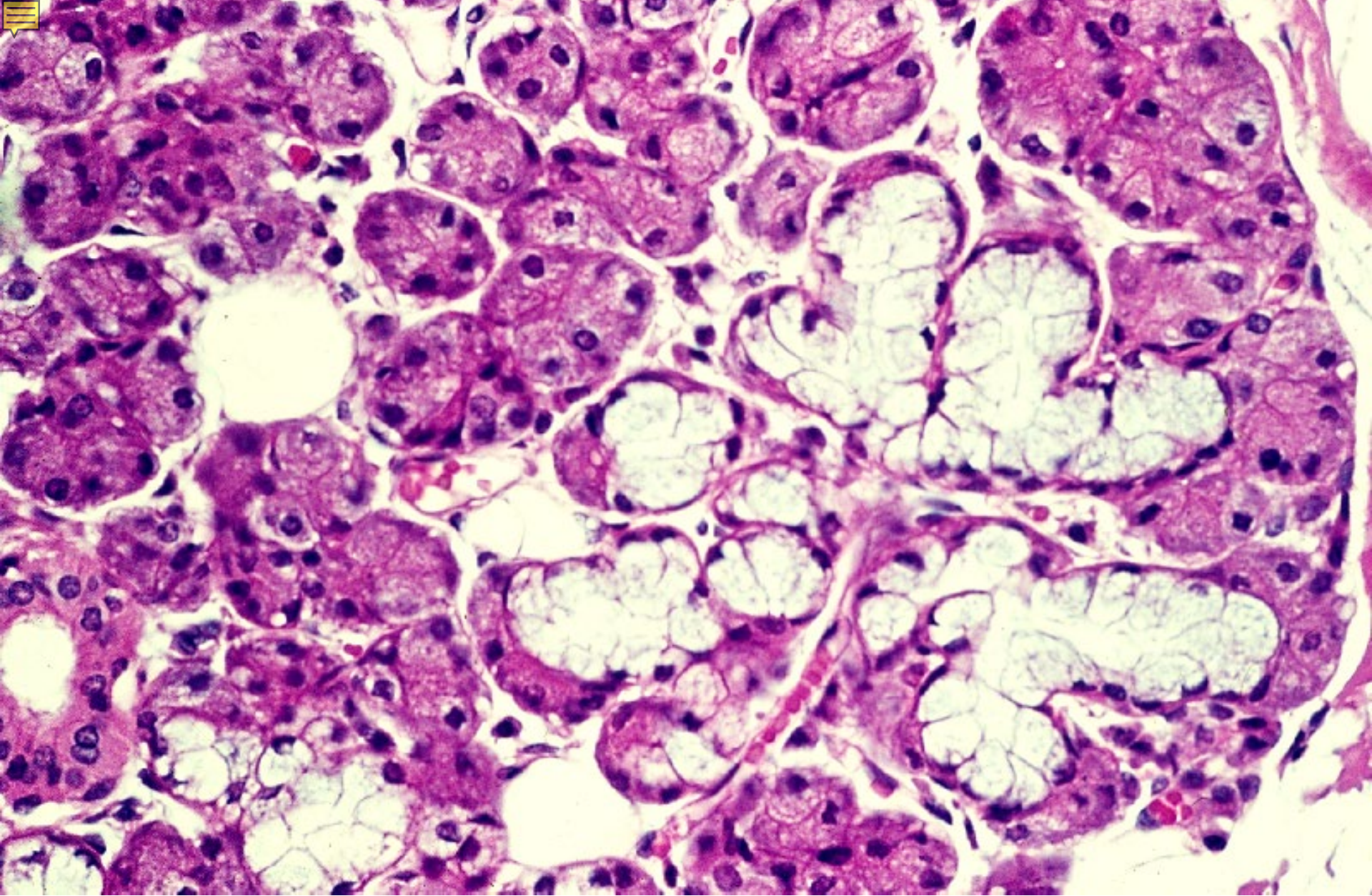
Human, H-E stain, x 40.



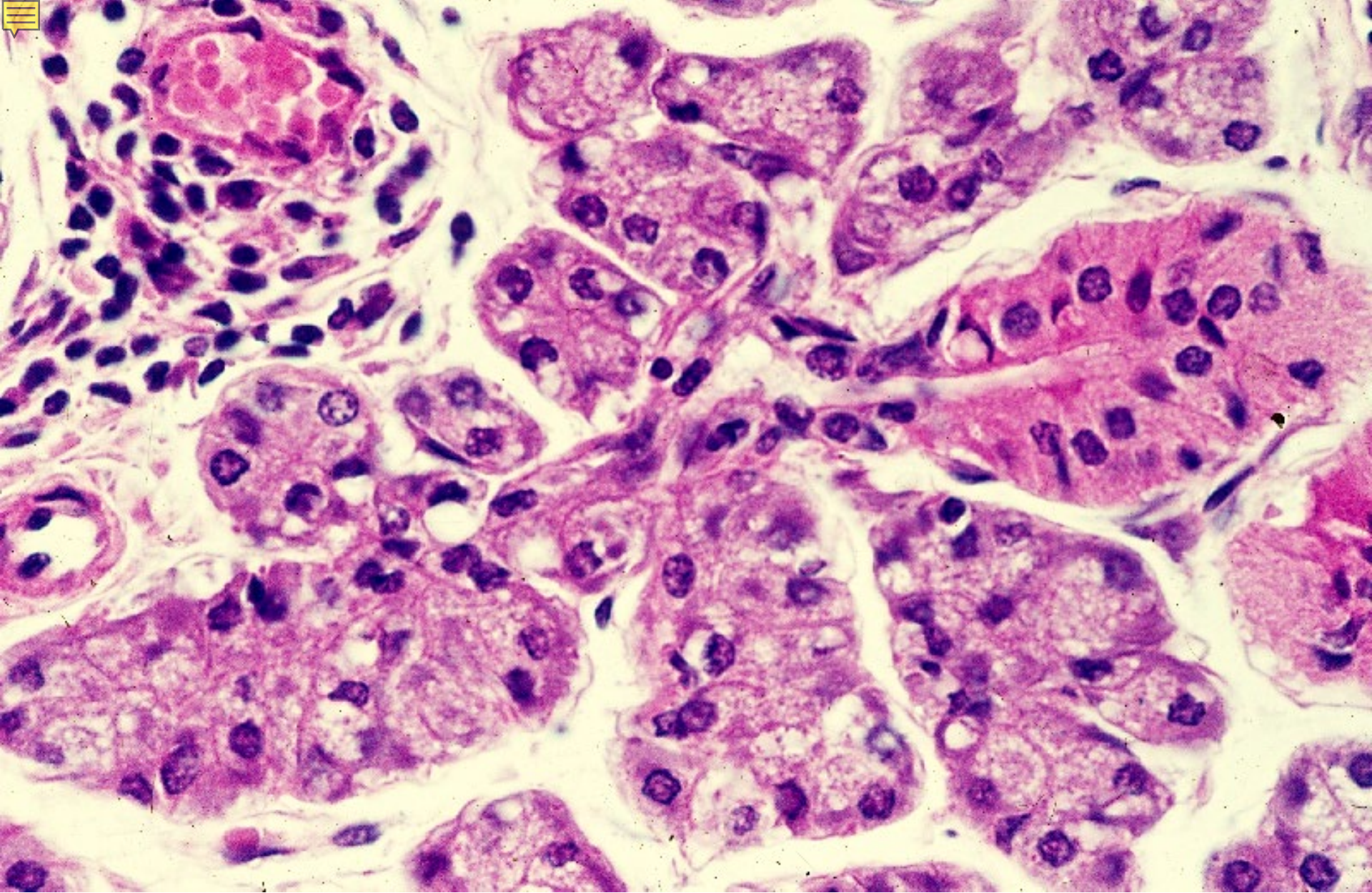
09-29. Gl. submandibularis 3. General view.
Human, H-E stain, x 40.



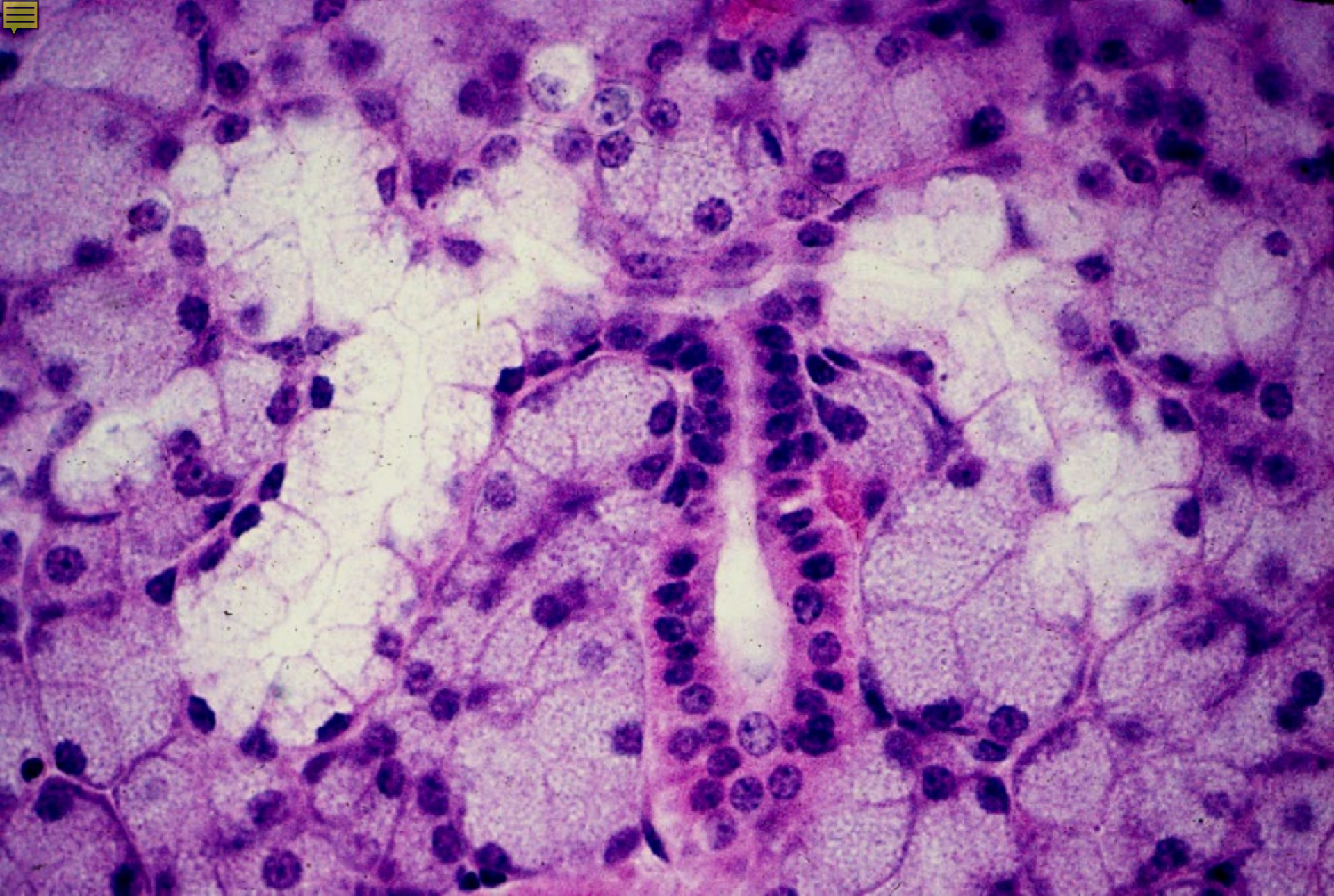09-30. Gl. Submandibularis 4. Human, H-E stain, x 100.



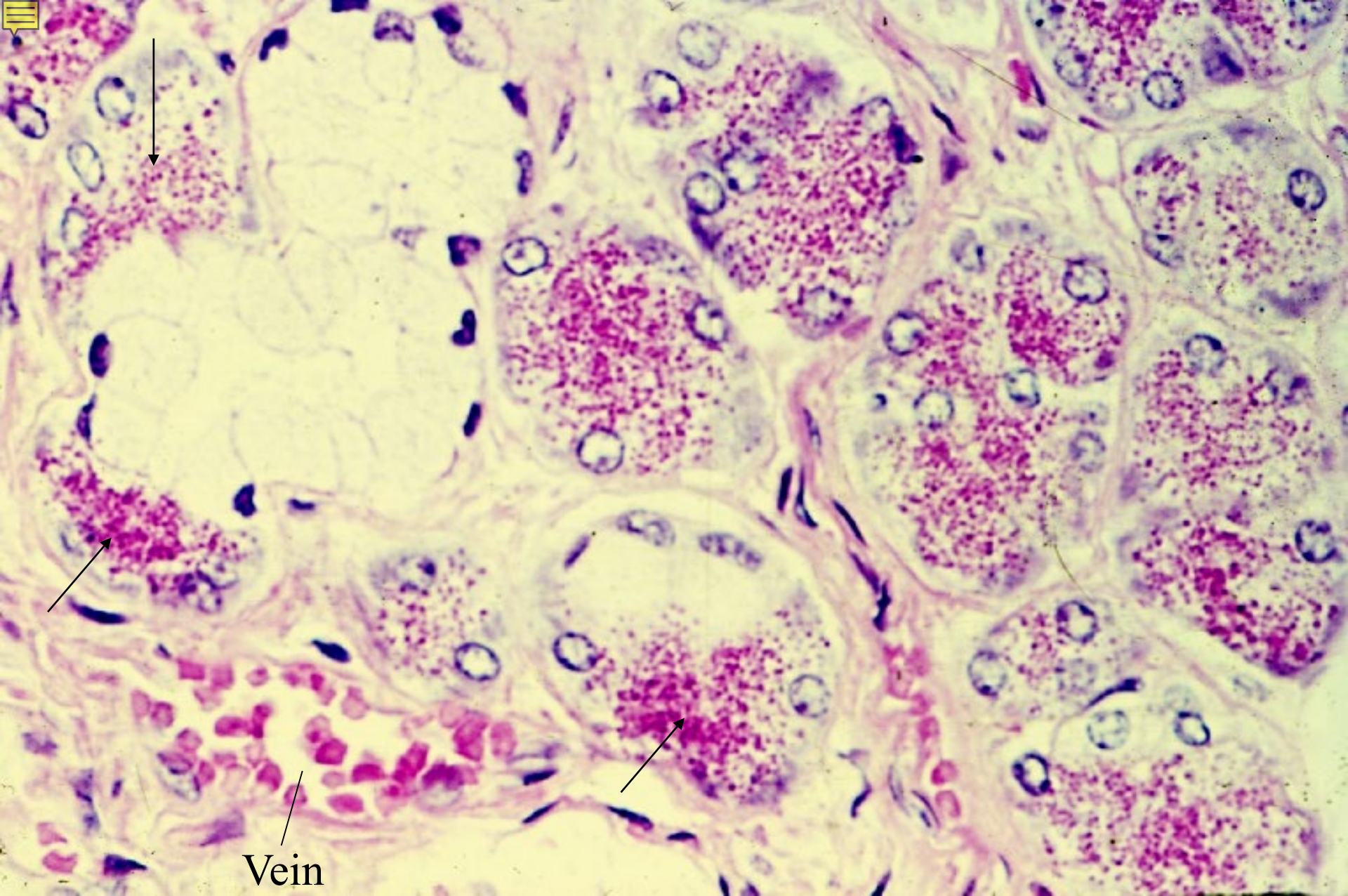
09-31. Gl. submandibularis 5. Human, H-E stain, x 100.



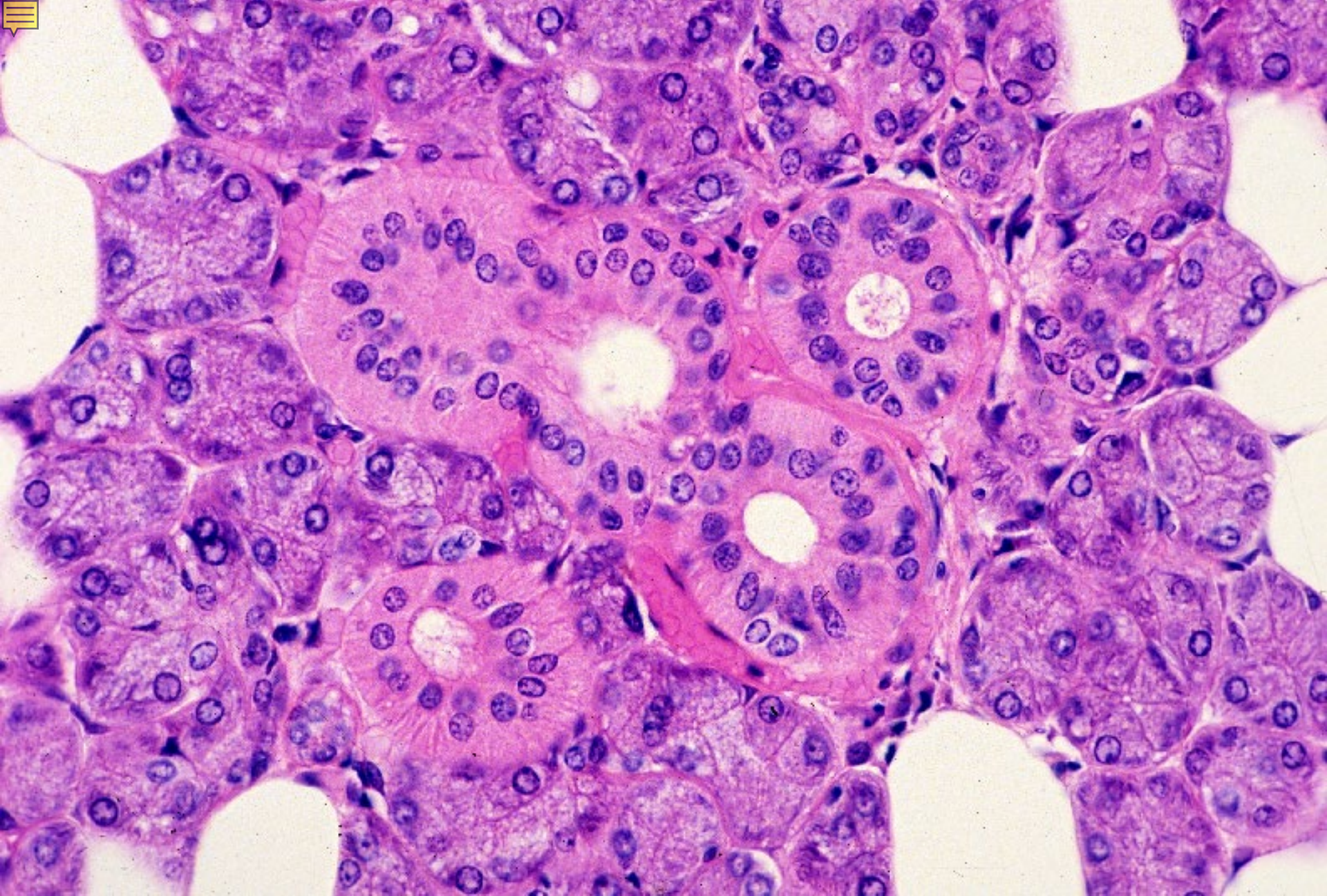
09-32. Gl. submandibularis 6. Intercalated duct and striated duct.
Human, H-E stain, x 160.



09-33. Gl. Submandibularis 7. Intercalated duct and striated duct.
Monkey, H-E stain, x 160.

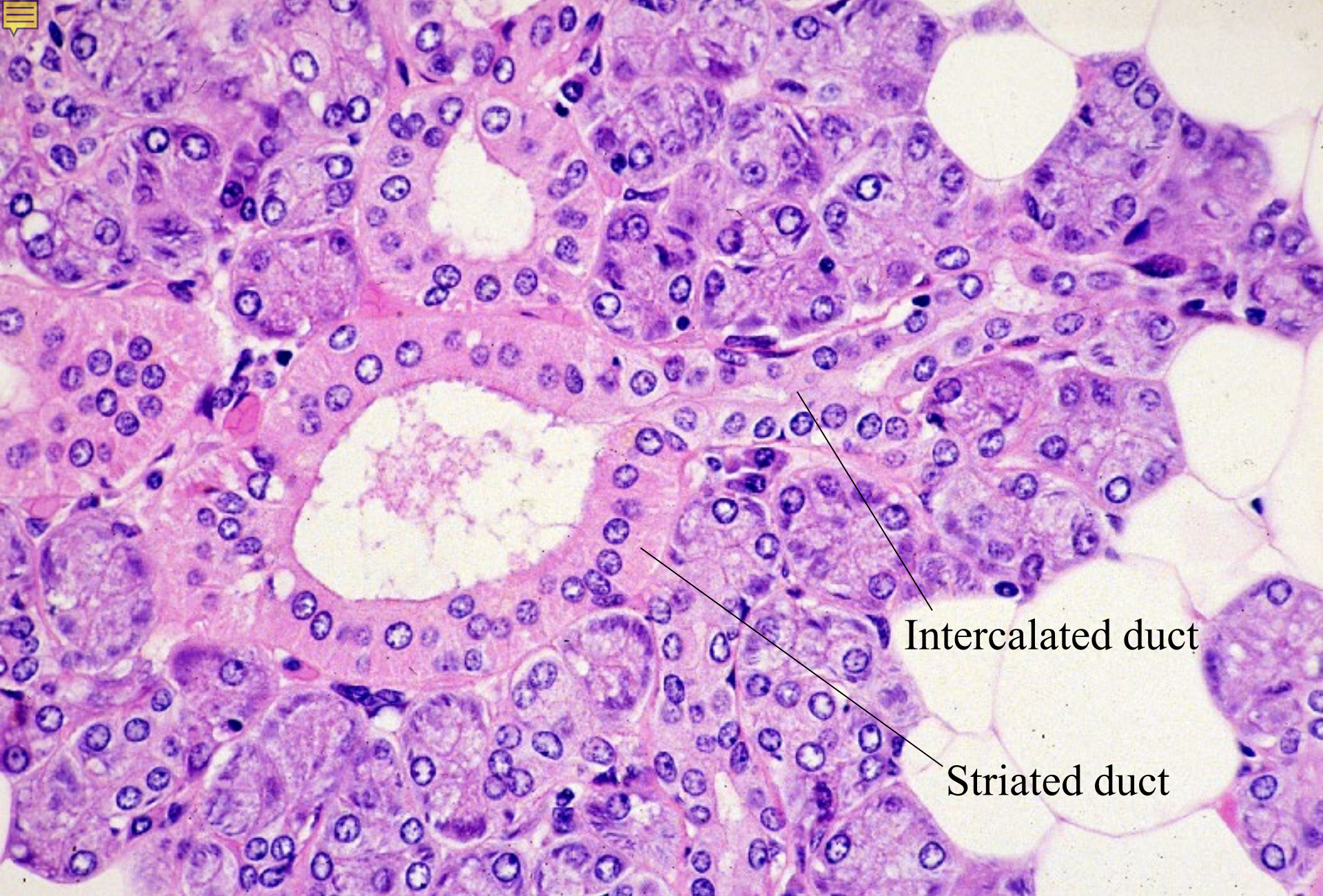


09-34. Gl. submandibularis 8. Secretion granules.
Human, H-E stain, x 160.



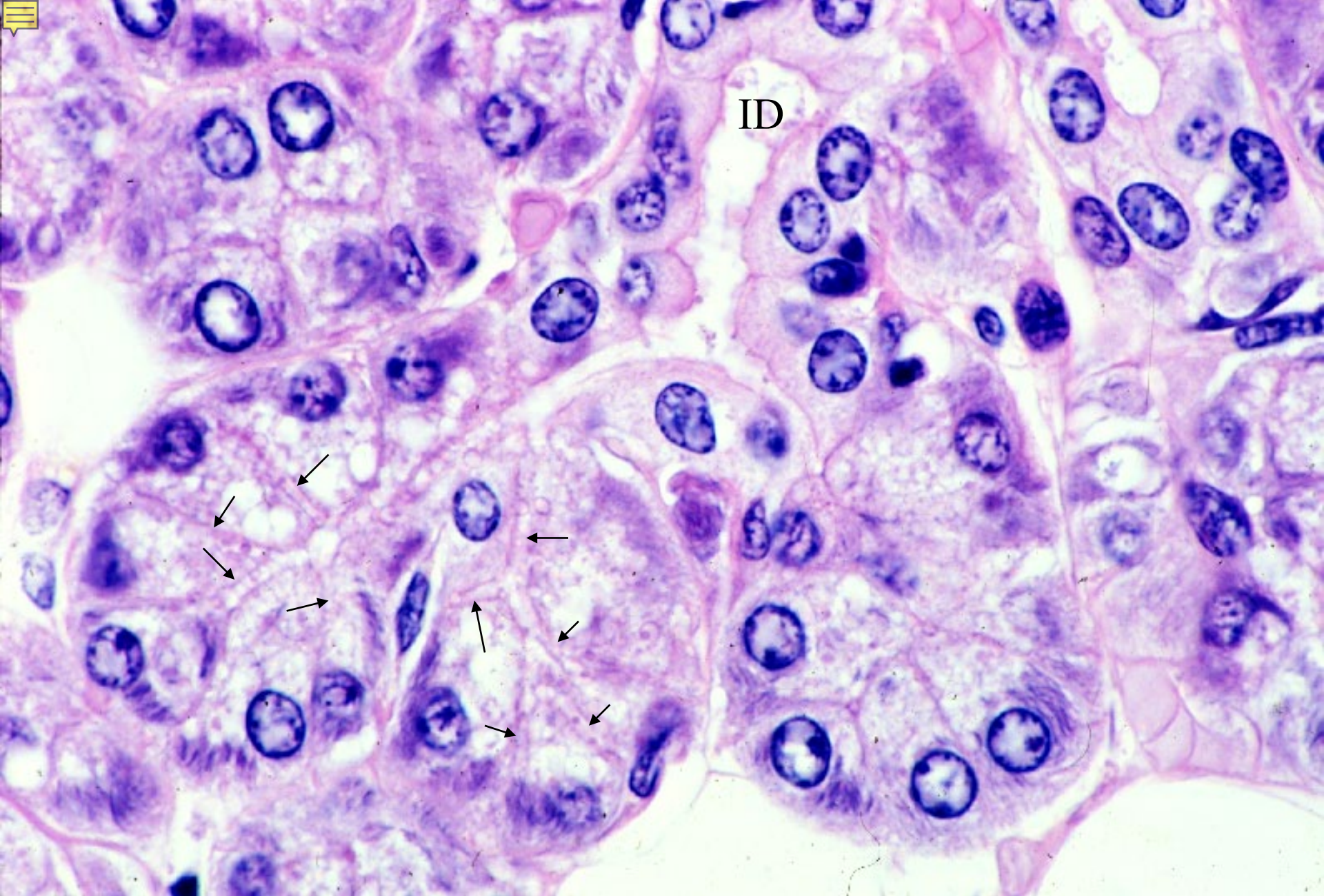
09-35. Gl. submandibularis 9. Striated ducts, transverse section.

Human H-E stain x 160



09-36. Gl. Submandibularis 10. Intercalated duct and striated duct.

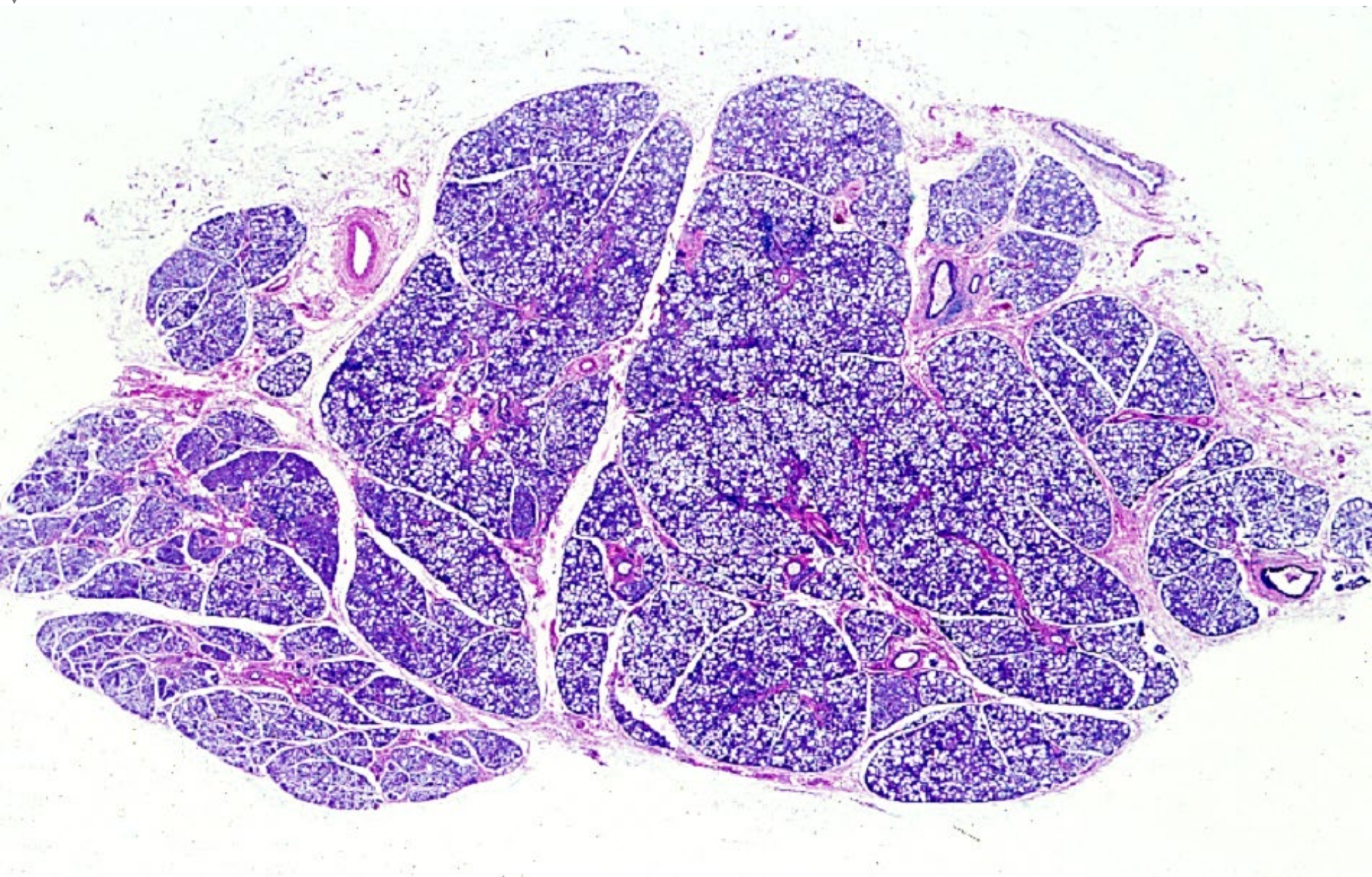
Human H-E stain x 160



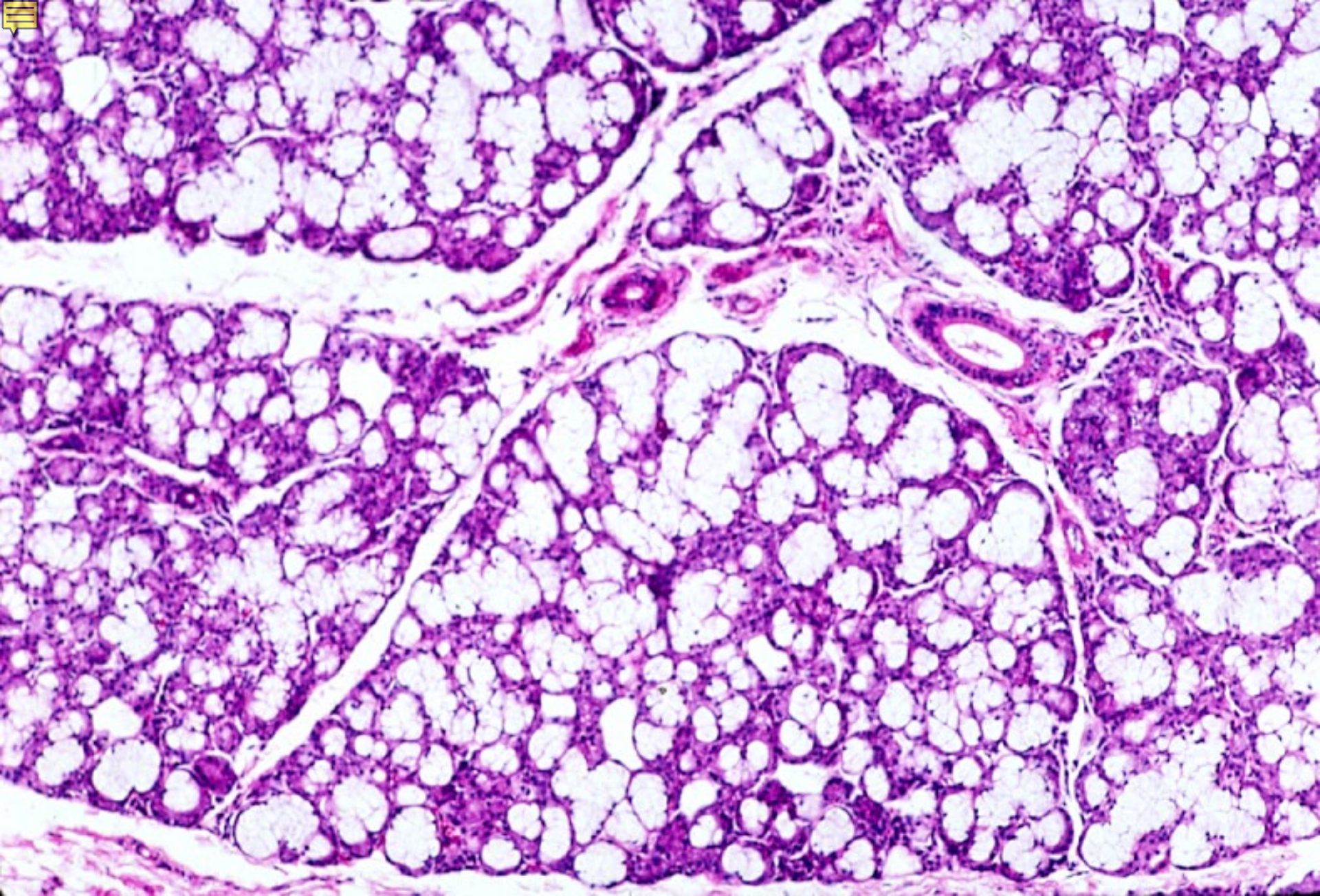
09-37. Gl. submandibularis 11. Secretory portion and intercalated duct Human H-E stain x 250

09-0023

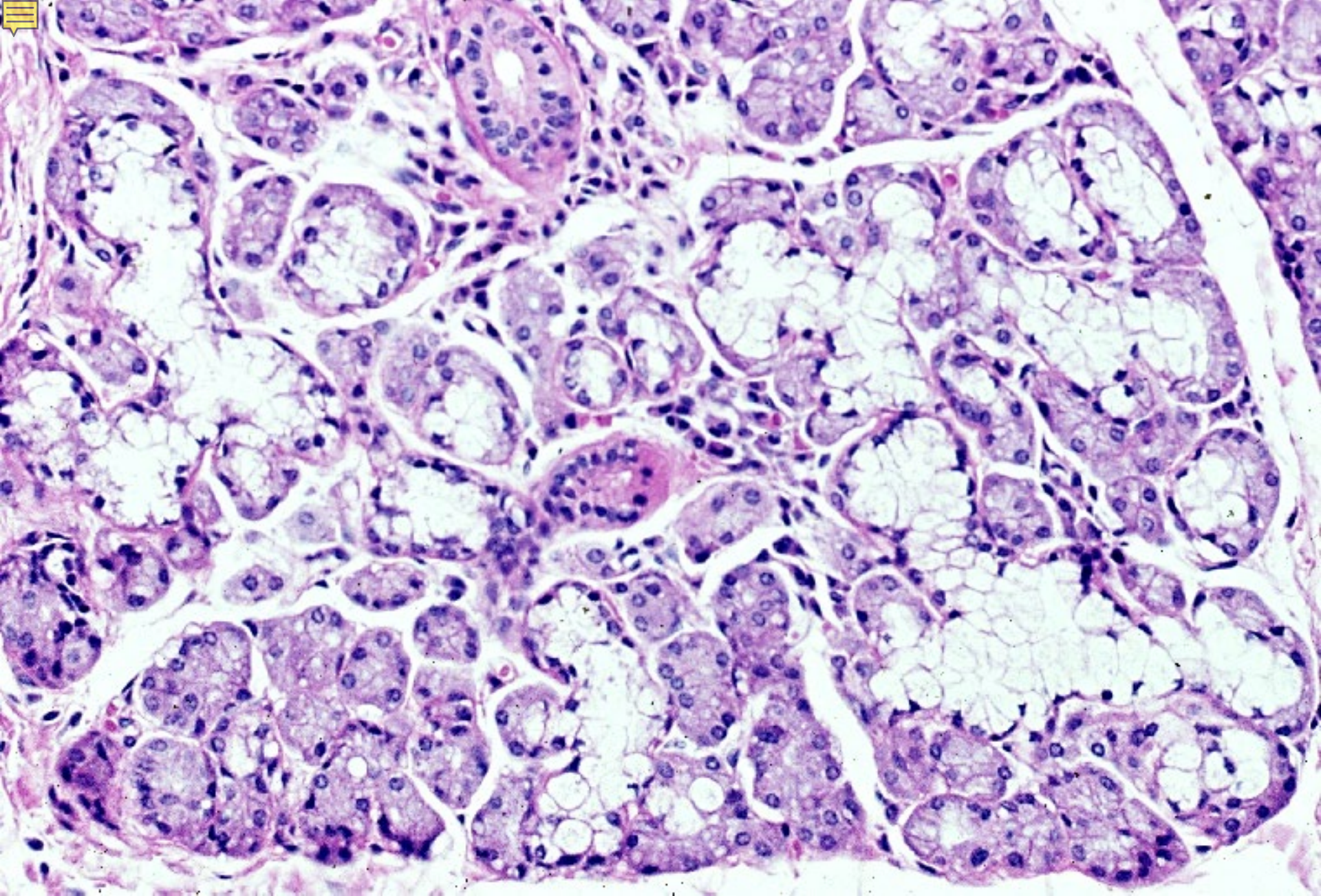
G1. sublingualis



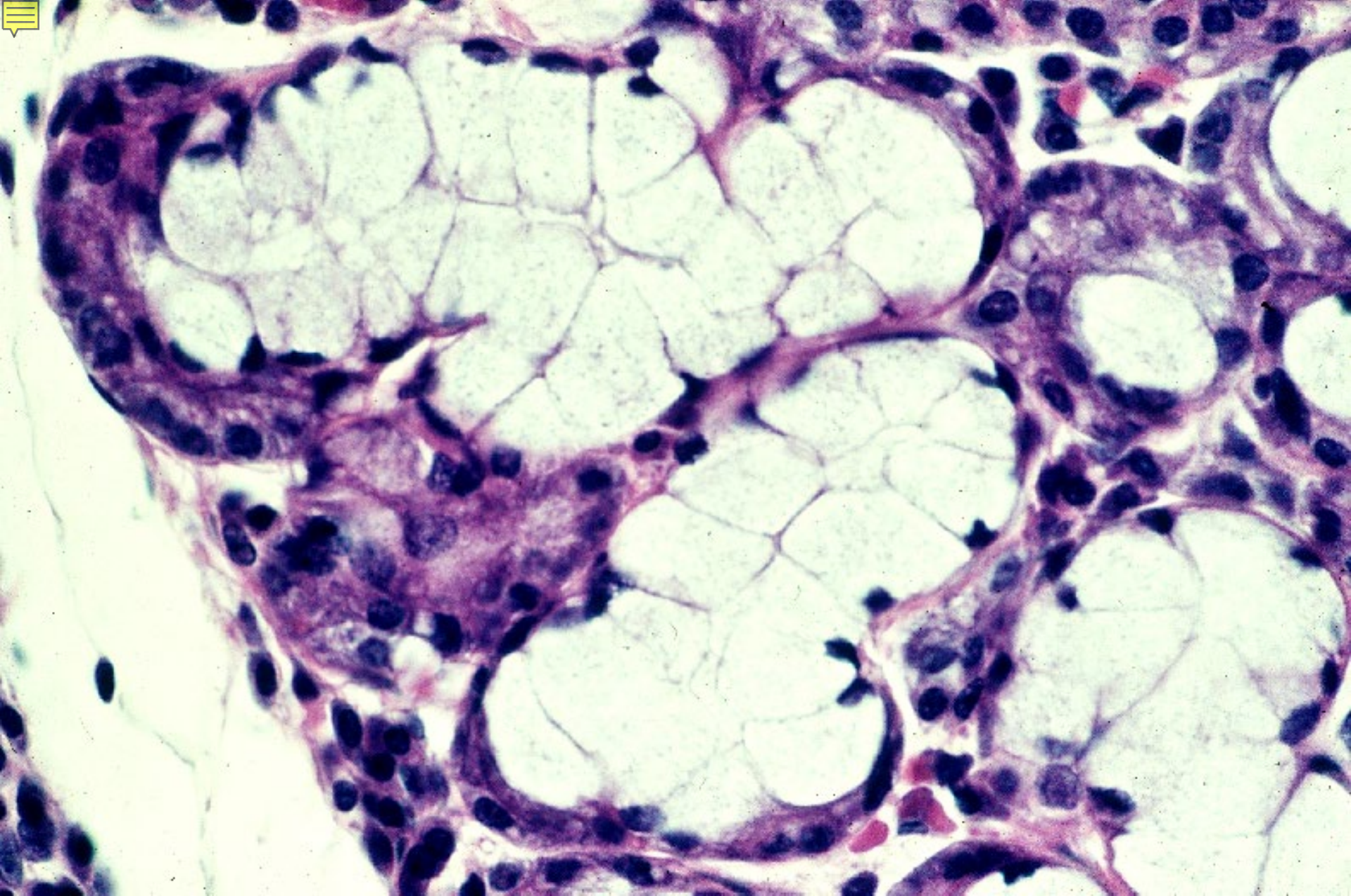
09-38. Gl. sublingualis 1. General view. Human, H-E stain, x 2.2.



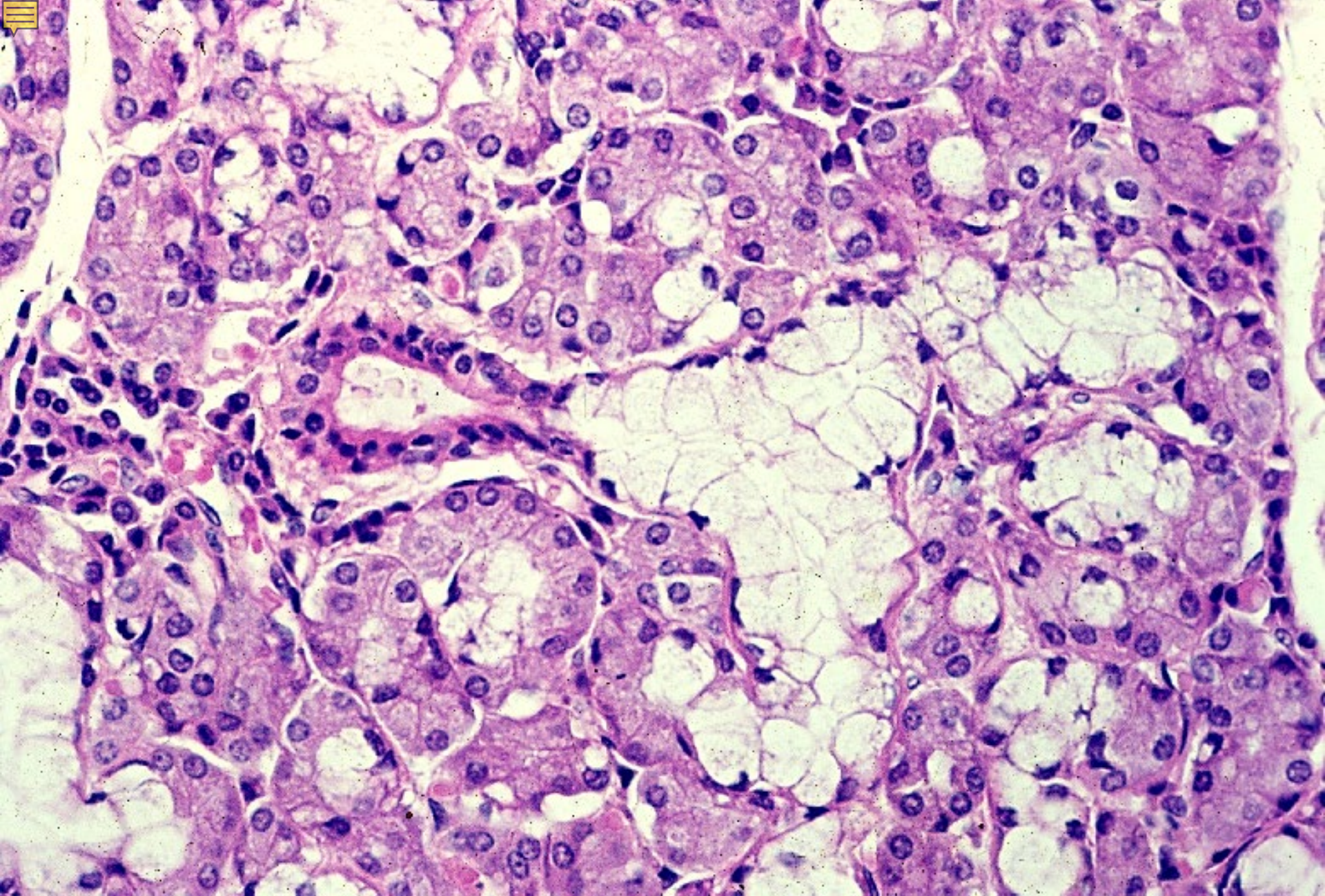
09-39. Gl. sublingualis 2. Human, H-E stain, x 25.



09-40. Gl. sublingualis 3. Human, H-E stain, x 64.

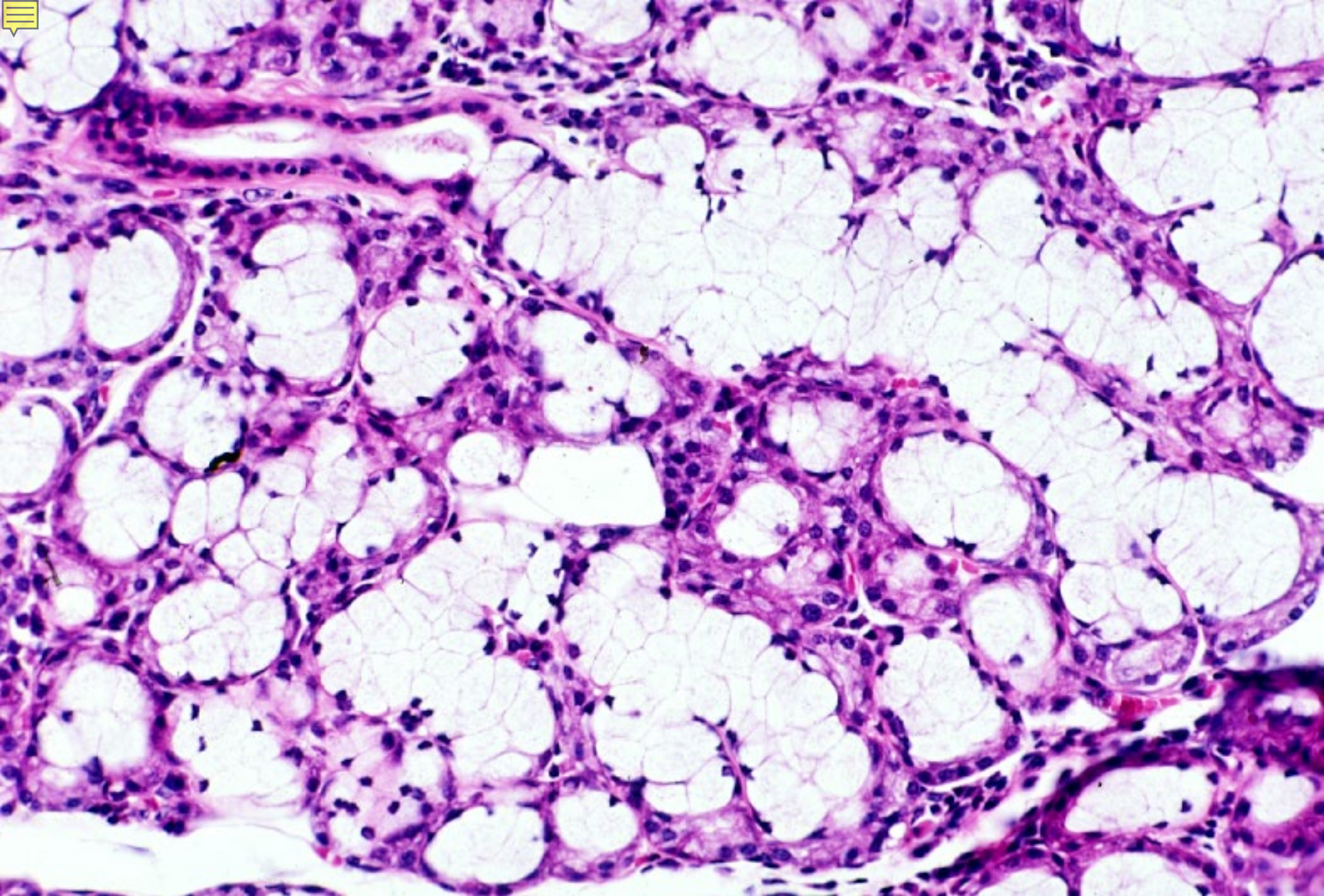


09-41. Gl. sublingualis 4. Mucous glands and demilunes.
Human, H-E stain, x 160.



09-42. Gl. sublingualis 5. Duct and mucous gland.

Human, H-E stain, x 100.



09-43. Gl. sublingualis 6. Duct and mucous gland.
Human, H-E stain, x 66.