



## Data base of Histology Color slides

Mizoguchi, Fumio

---

(Issue Date)

2015-05-04

(Resource Type)

learning object

(Version)

Version of Record

(Rights)

1. 利用者による利用の範囲は、著作権法に定める私的利用の範囲とする。2. 研究成果を利用者が利用した結果について、許諾者はその責任を負わない。  
私的利用の範囲を超える二次利用（印刷物、ウェブサイト、発表資料等への転載など）については、利用希望者は附属図書館（<https://lib.kobe-u.ac.jp/da/secondaryuse/#secondaryuse-...>）

(URL)

<https://hdl.handle.net/20.500.14094/90009617>





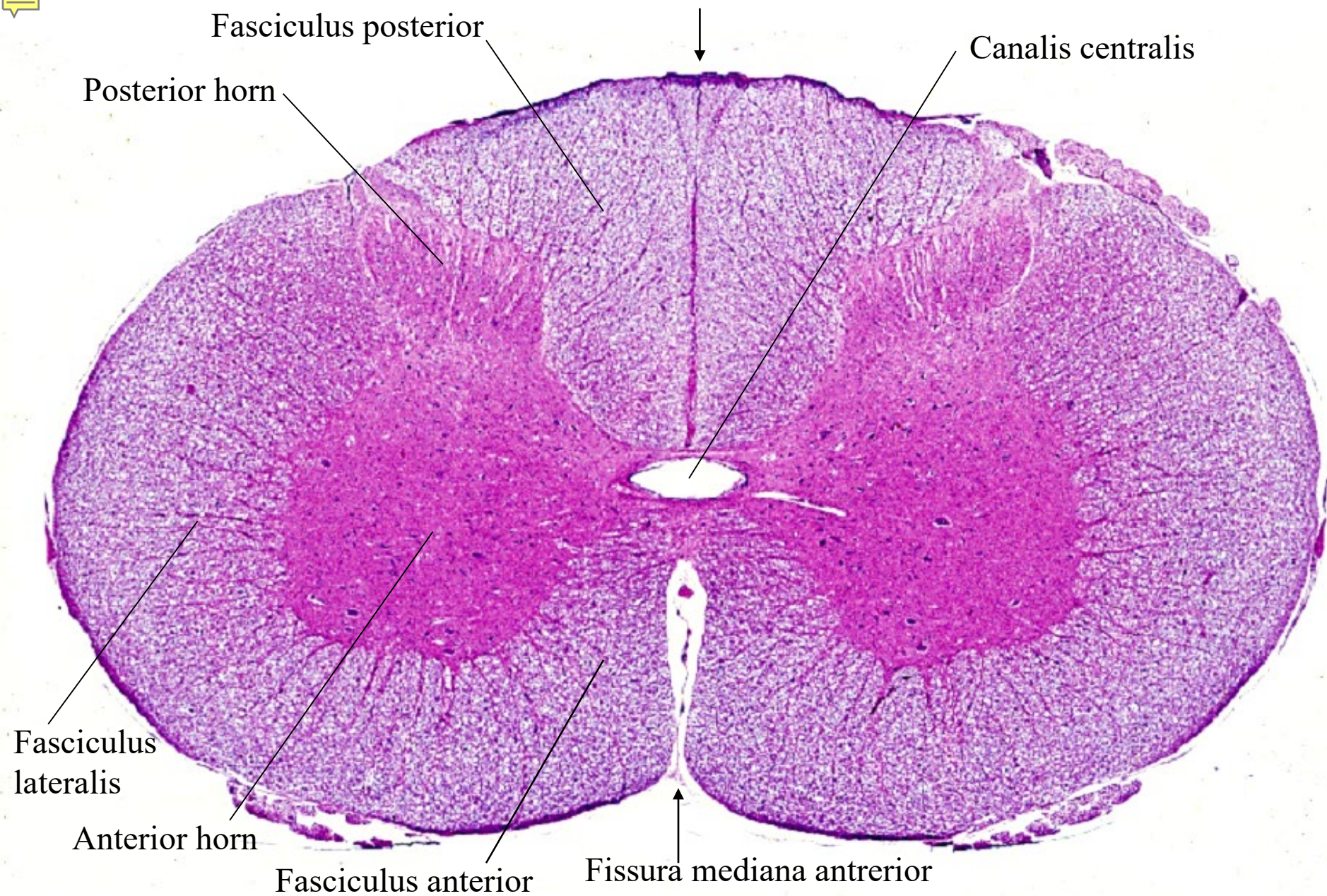
22

# Central Nervous System



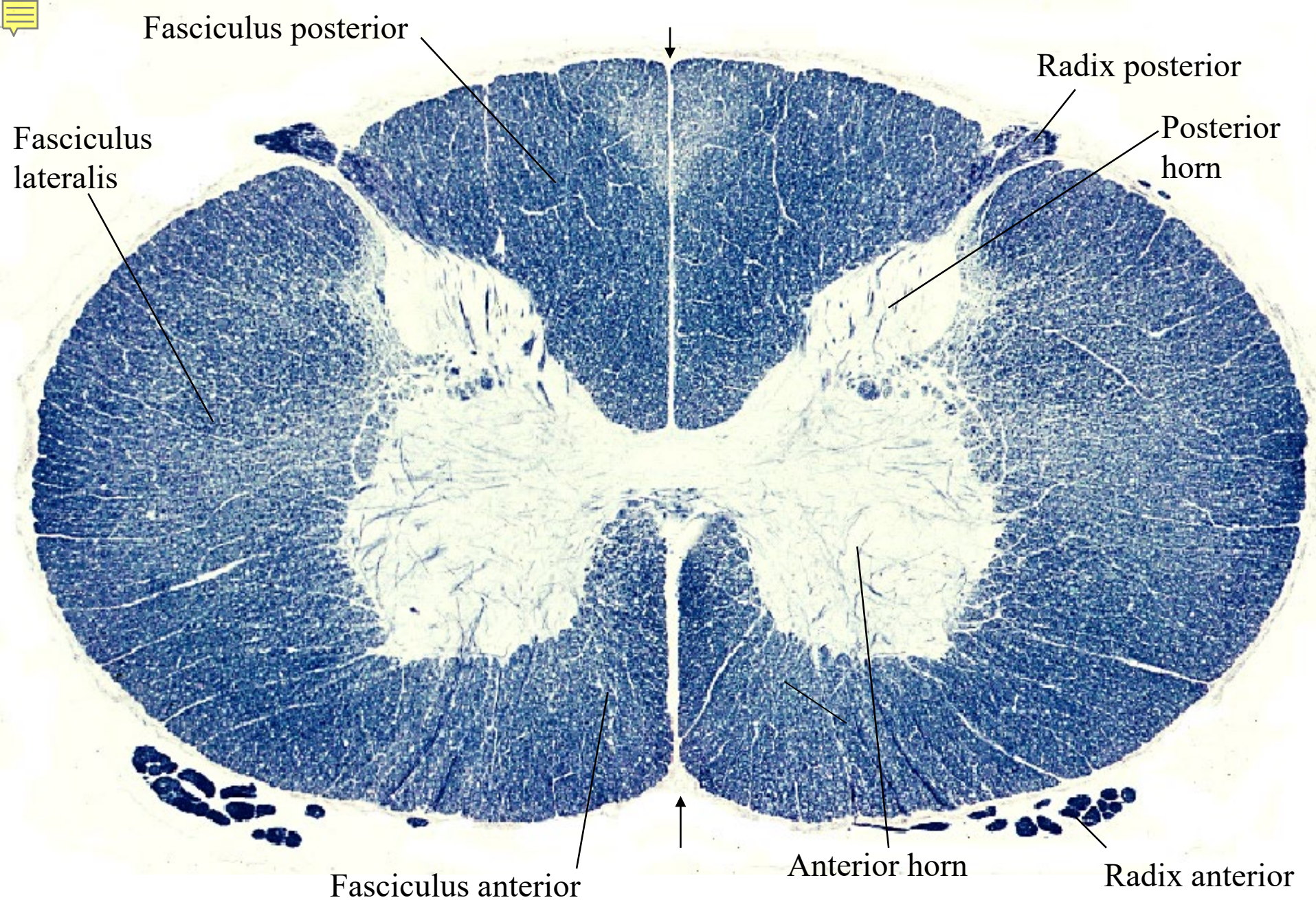
22-001

Spinal Cord



22-01. Spinal cord 1. H-E stain. Dog, transverse section, x 5.



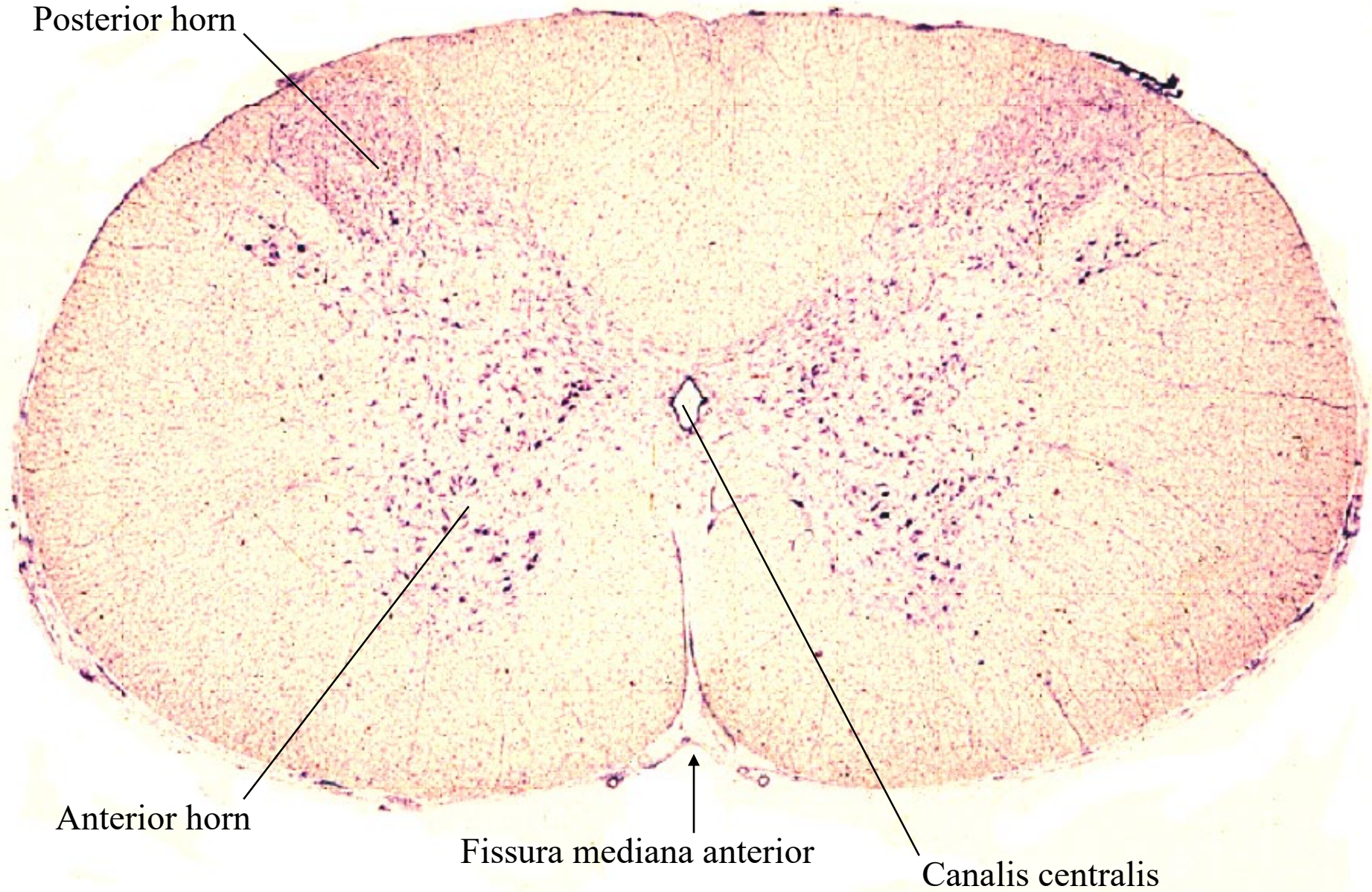


22-02. Spinal cord 2. Weigert stain. Dog, transverse section, x 4.5.



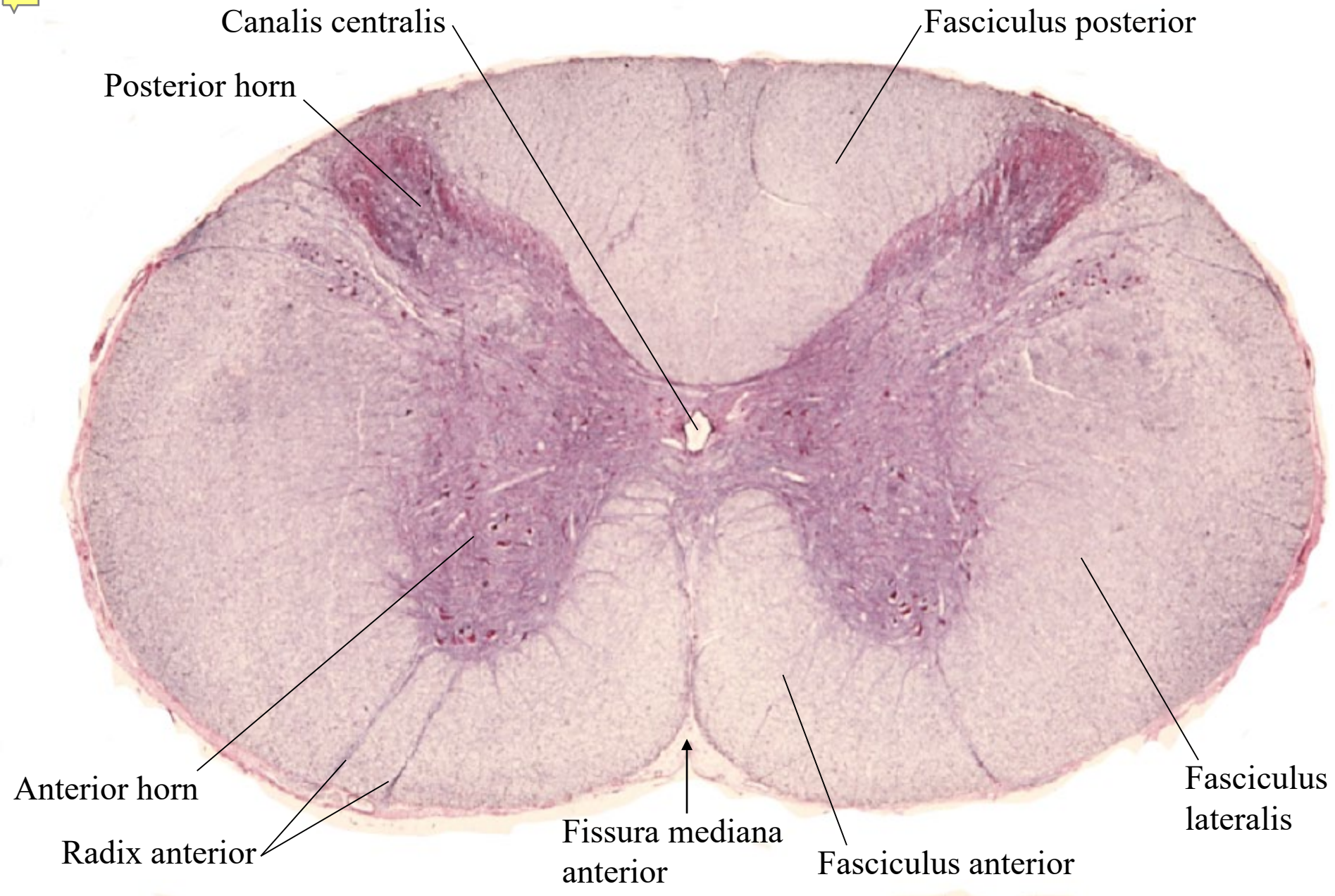


Posterior horn



22-03. Spinal cord 3. Nissl stain. Dog, transverse section, x 5.





22-04. Spinal cord 4. Bodian's Silver impregnation. Dog, transverse section, x 5.

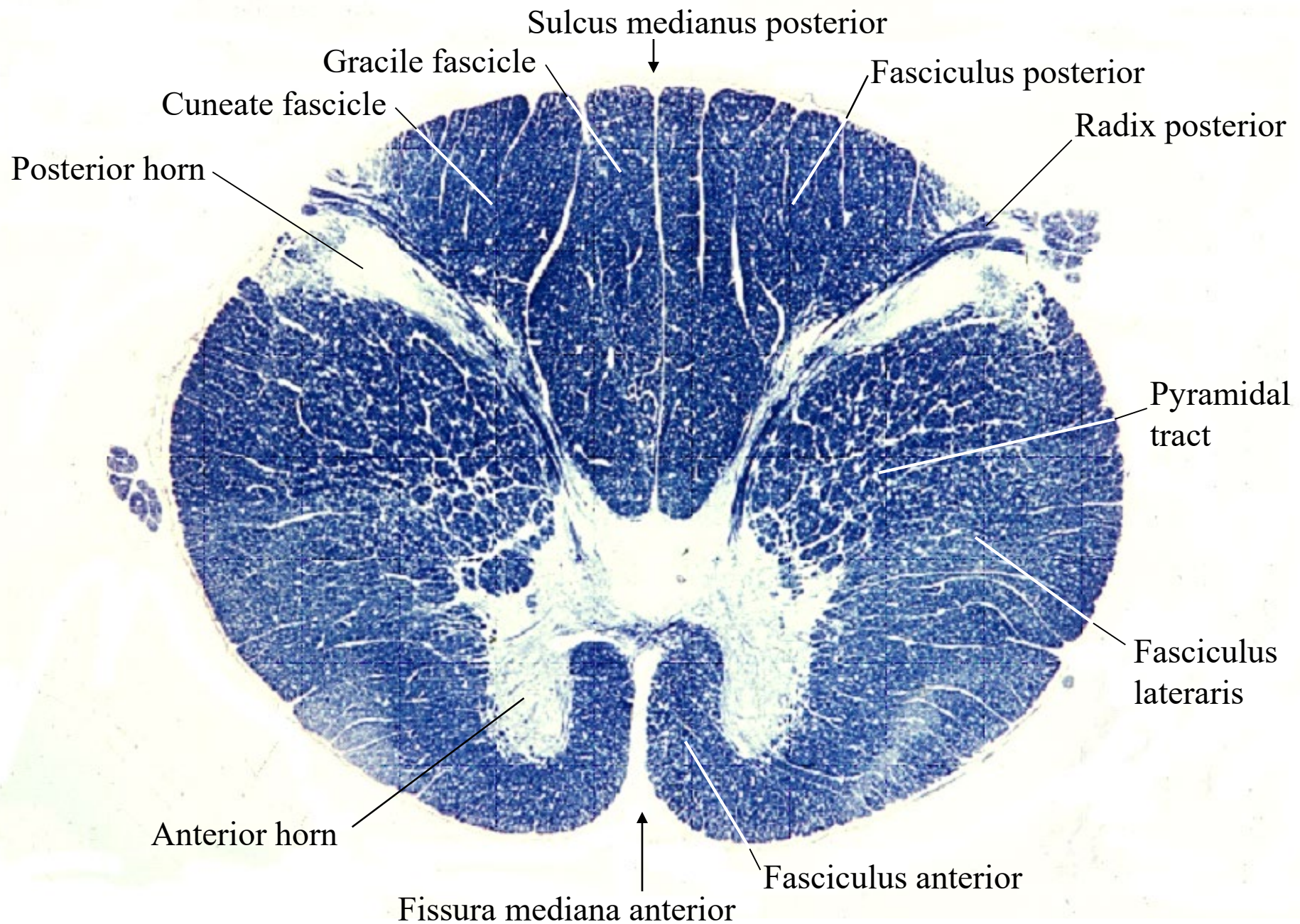


22-002

Brain Stem

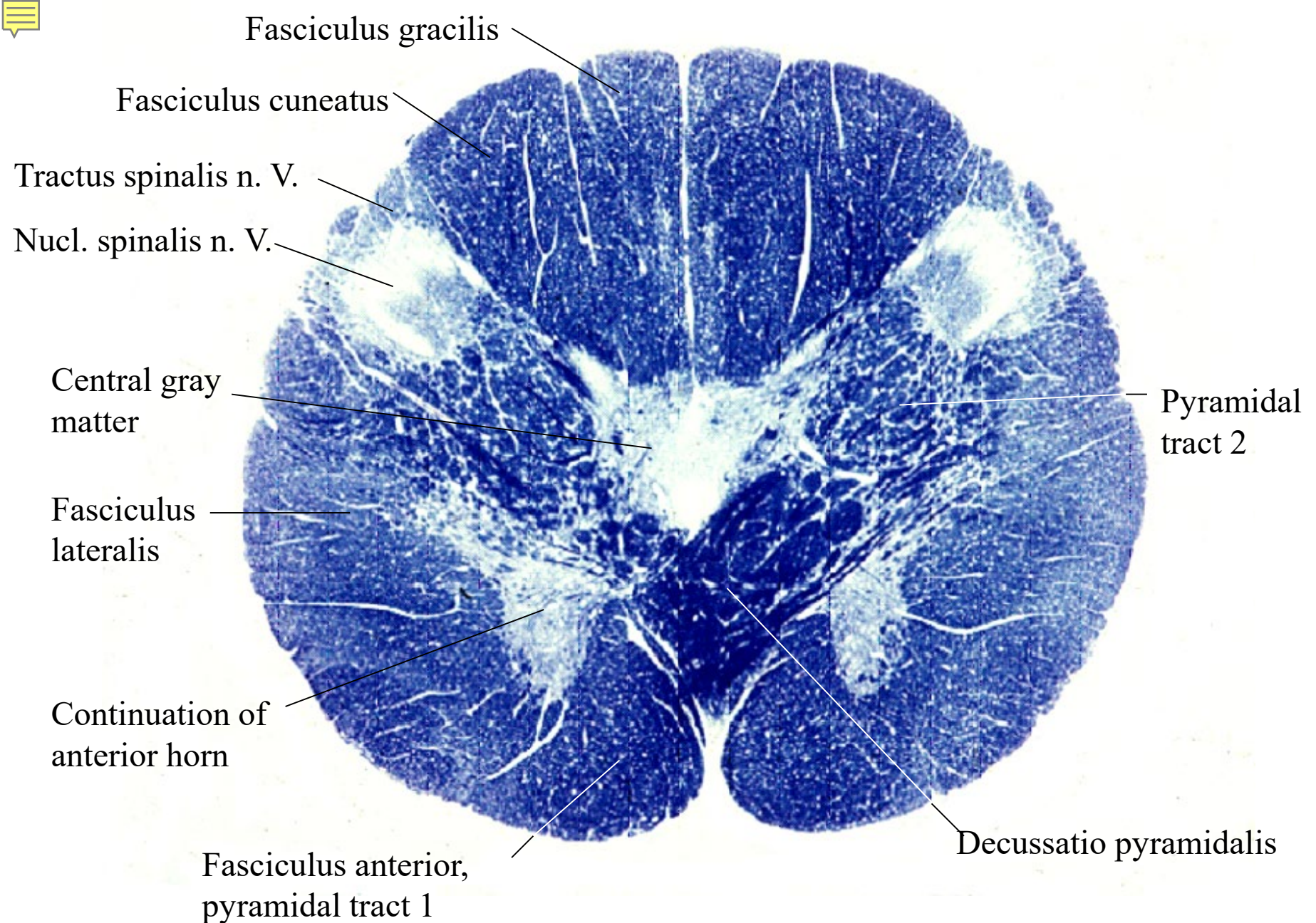
(Transverse section,  
Weigert stain)





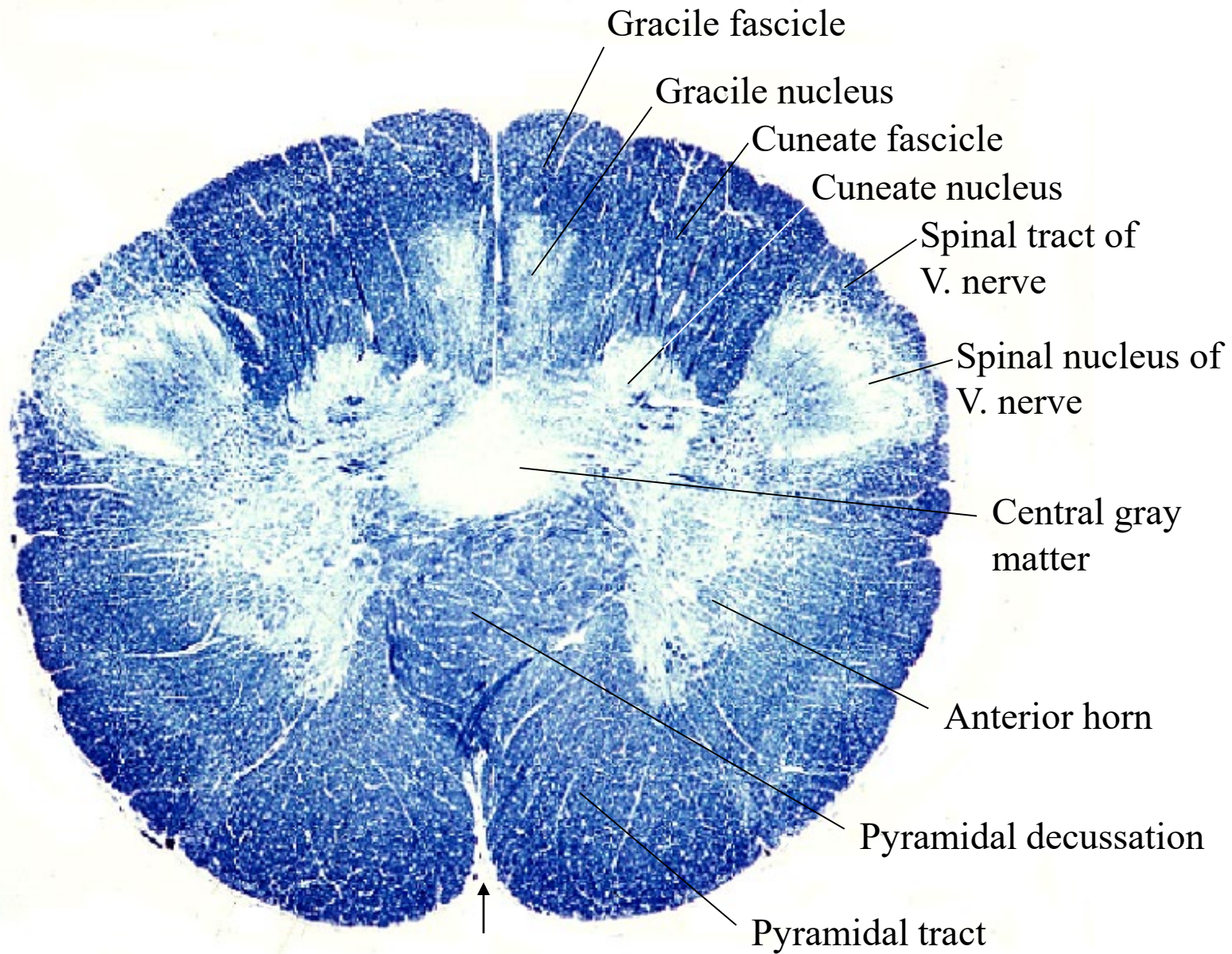
22-05. The first cervical segment ( $C_1$ ). x 2.





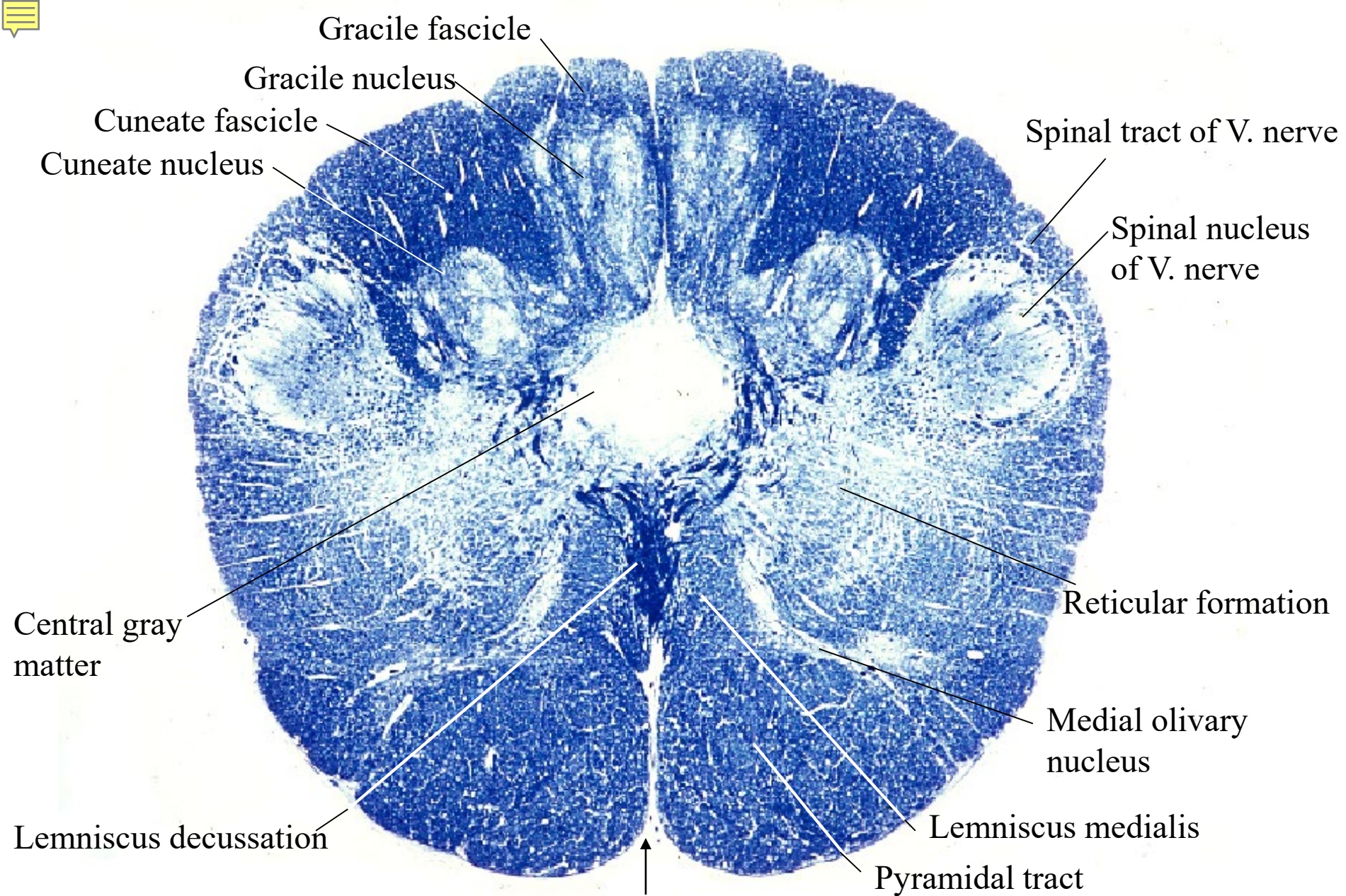
22-06. Medulla oblongata 1. Inferior end of the pyramidal decussation. x 2.





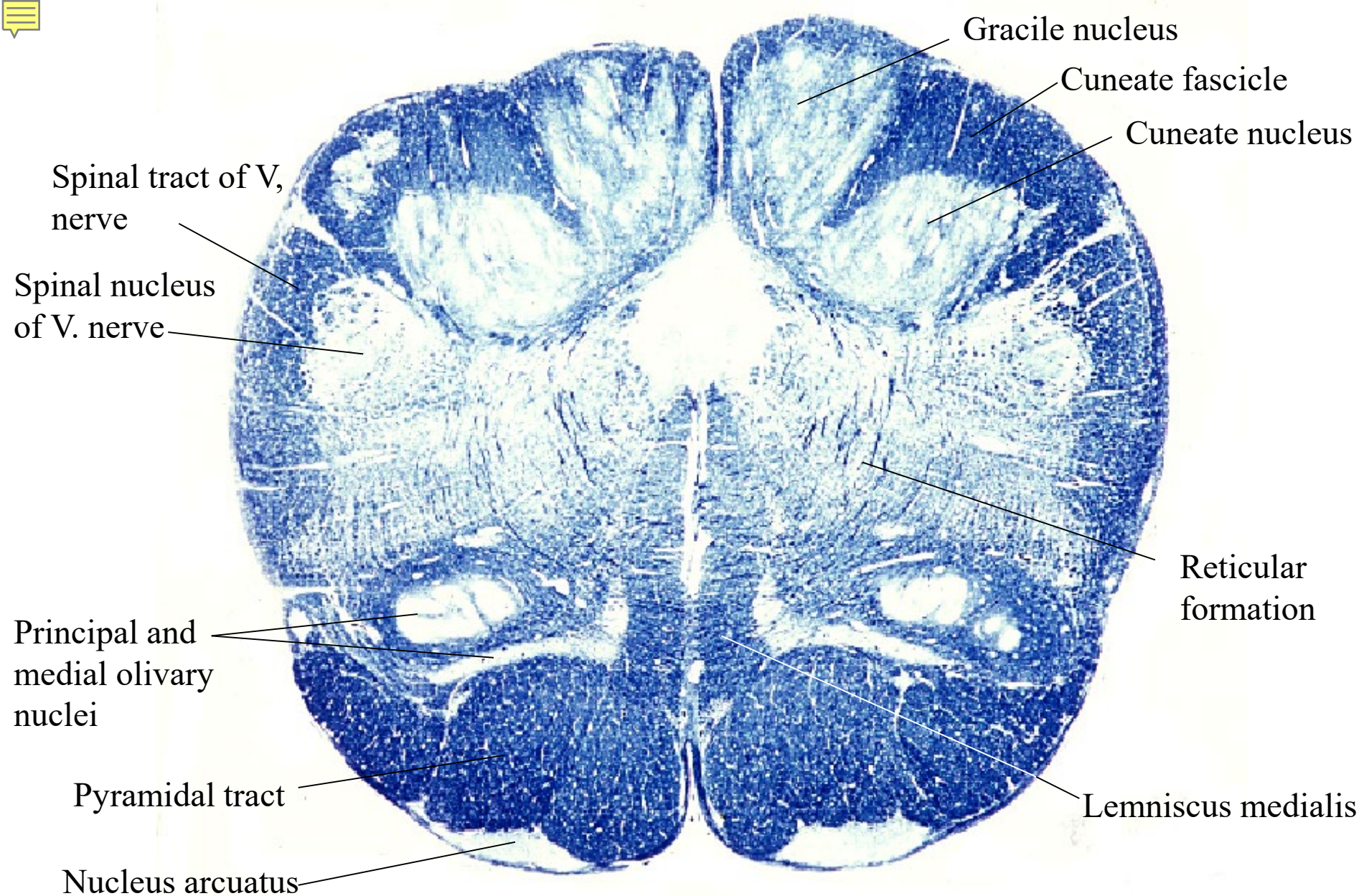
22-07. Medulla oblongata 2. The level of the upper portion of the pyramidal decussation. x 2.





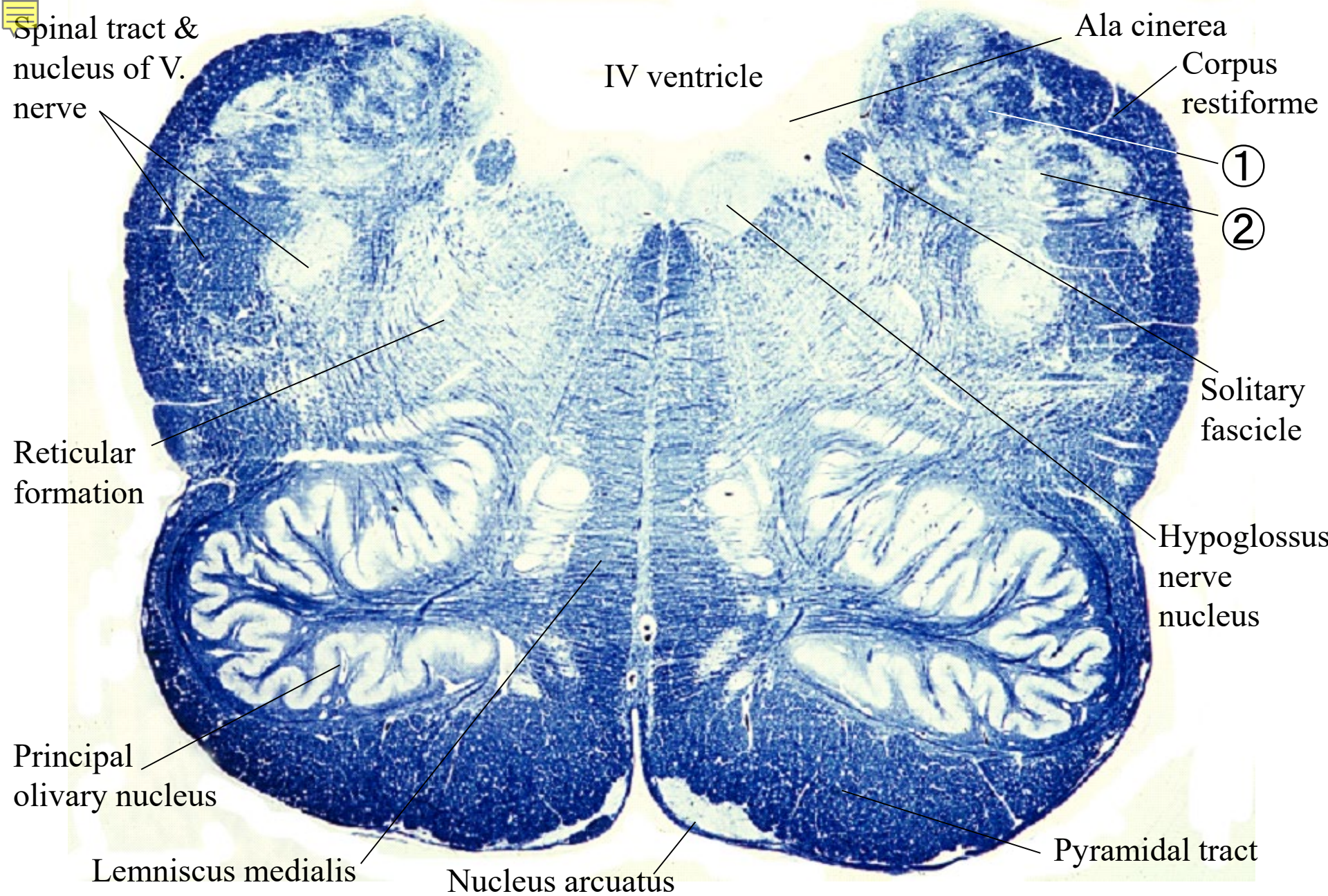
22-08. Medulla oblongata 3. The level of the inferior end of the lemniscus decussation. x 2.





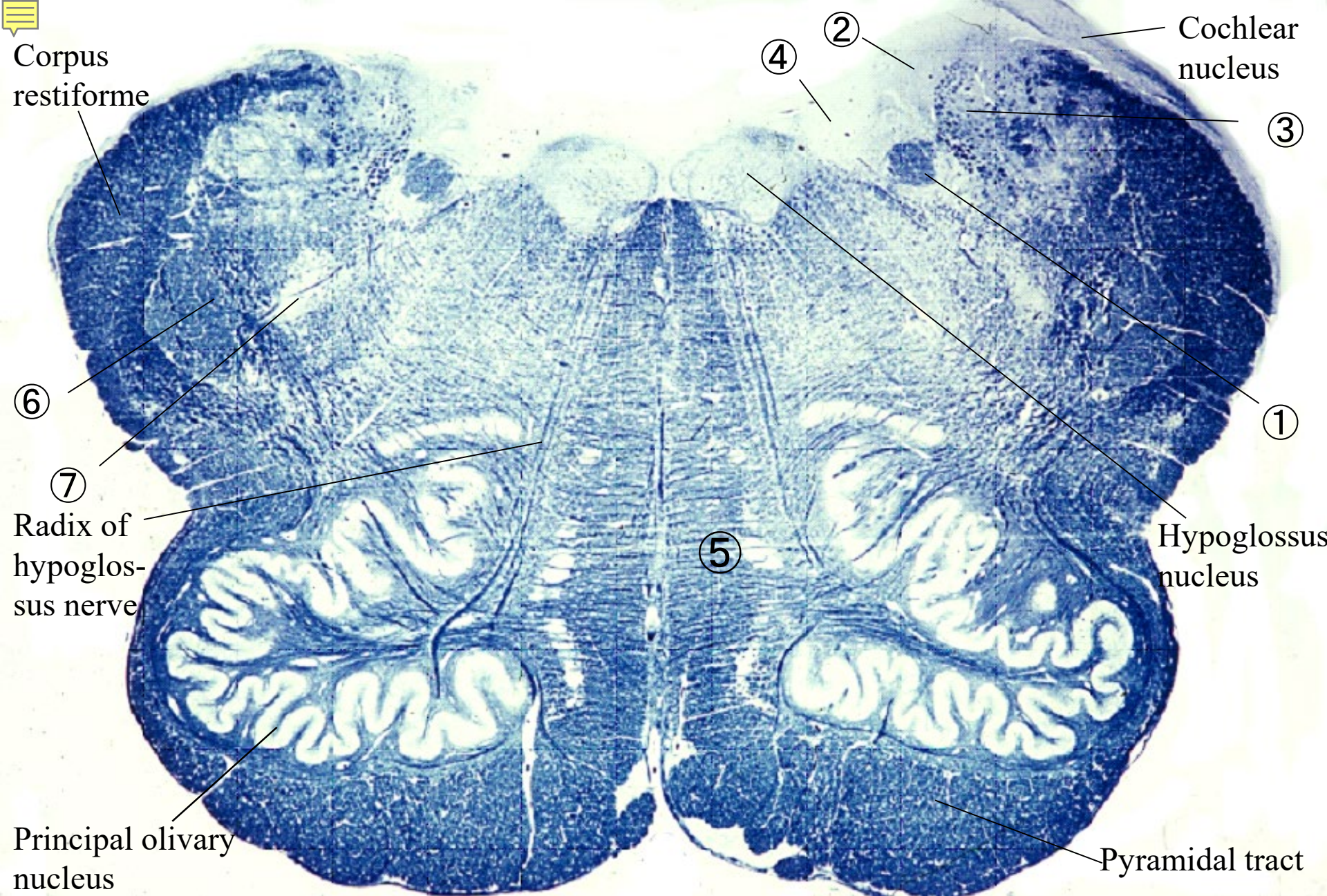
22-09. Medulla oblongata 4. The level of the upper portion of the lemniscus decussation. x 1.6.





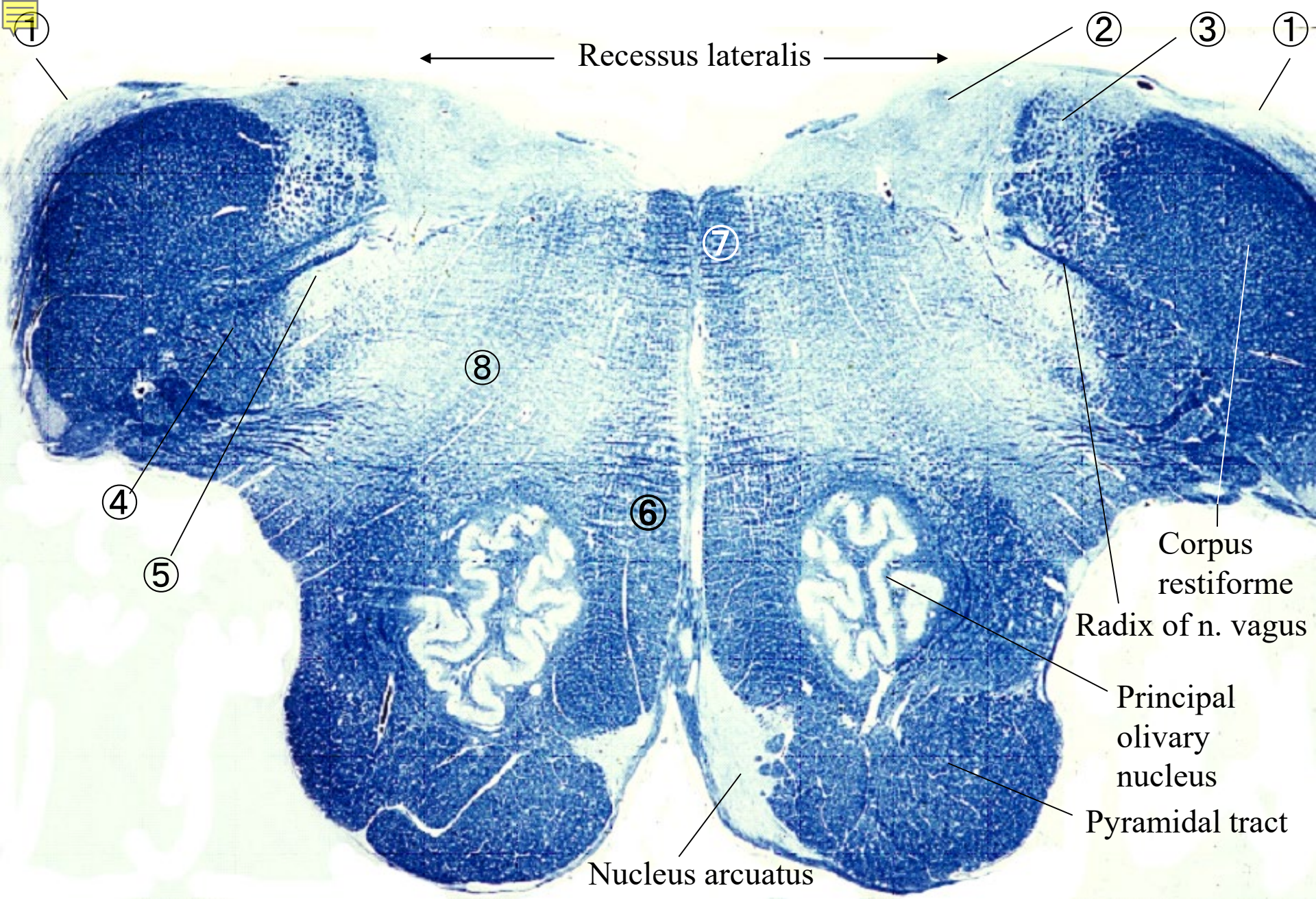
22-10 . Medulla oblongata 5. The level of the middle portion of the nucl. olivaris inferior. x 1.6.





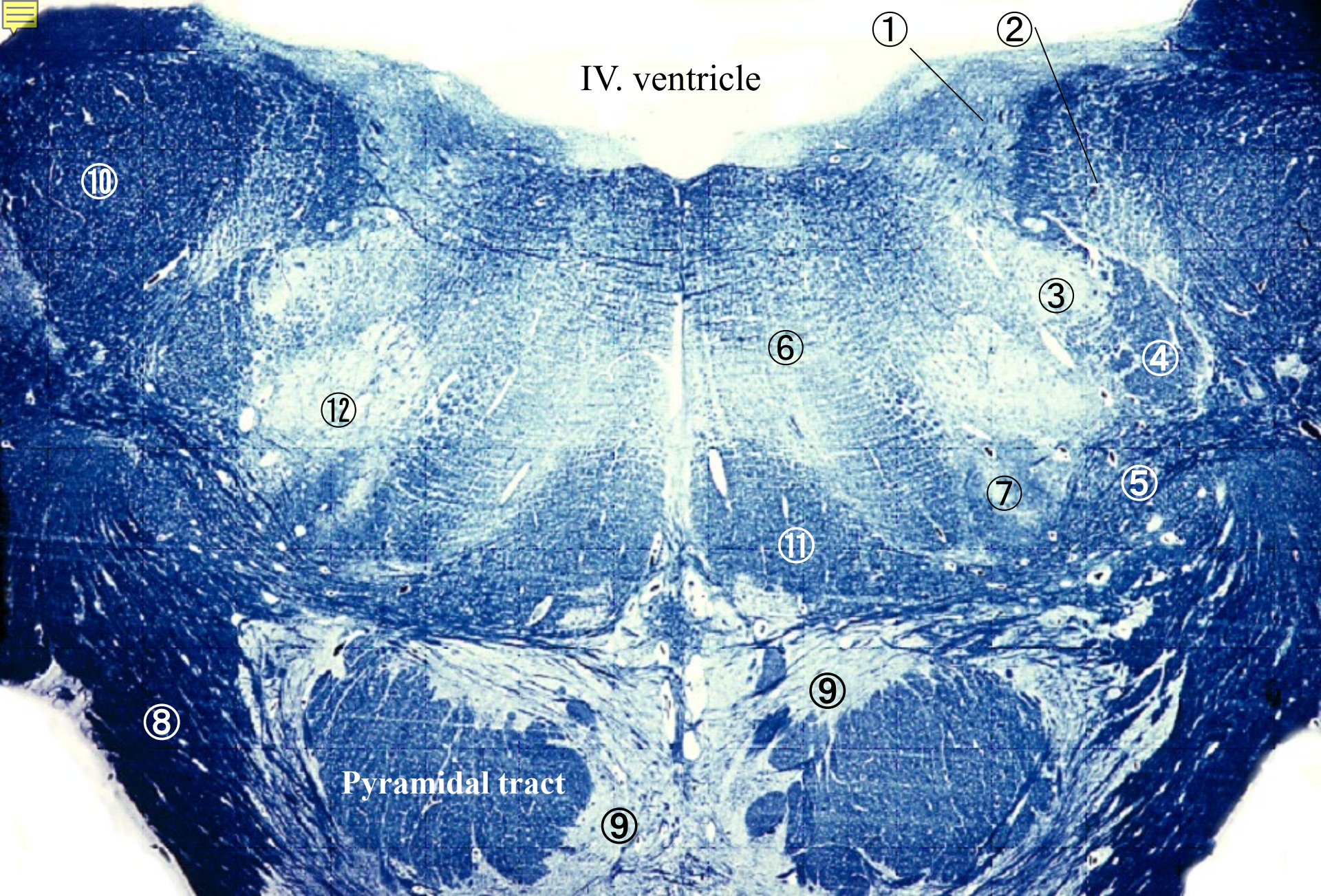
22-11. Medulla oblongata 6. The level of the upper portion of the nucl. hypoglossus. x 1.6





22-12. Medulla oblongata 7. The level of the upper end of the medulla oblongata. x 1.6.





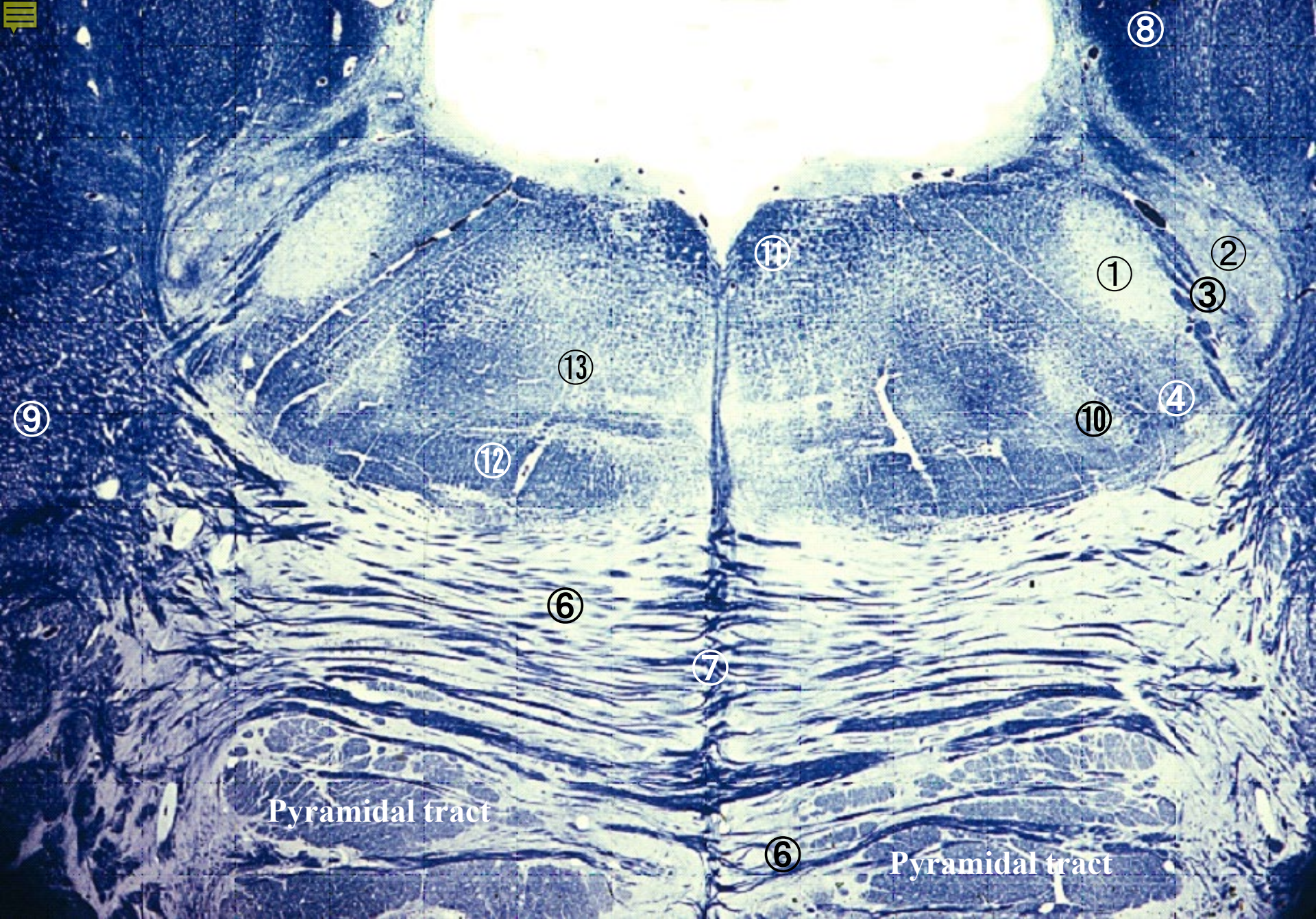
22-13. Pons 1. The level of the nucl. facialis. x 1.6





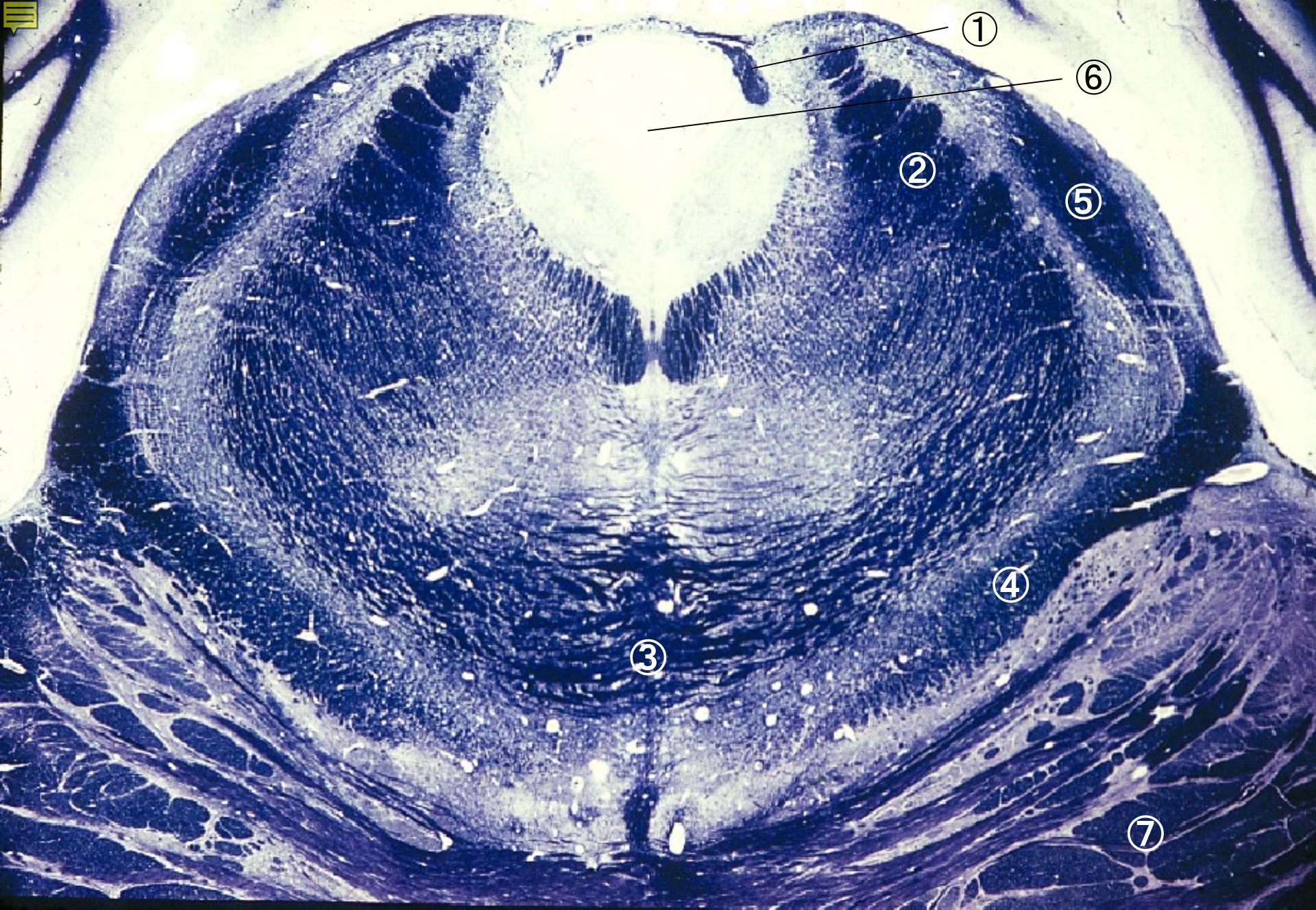
22-14. Pons 2. The level of the nucl. n. abducentis. x 1.6.





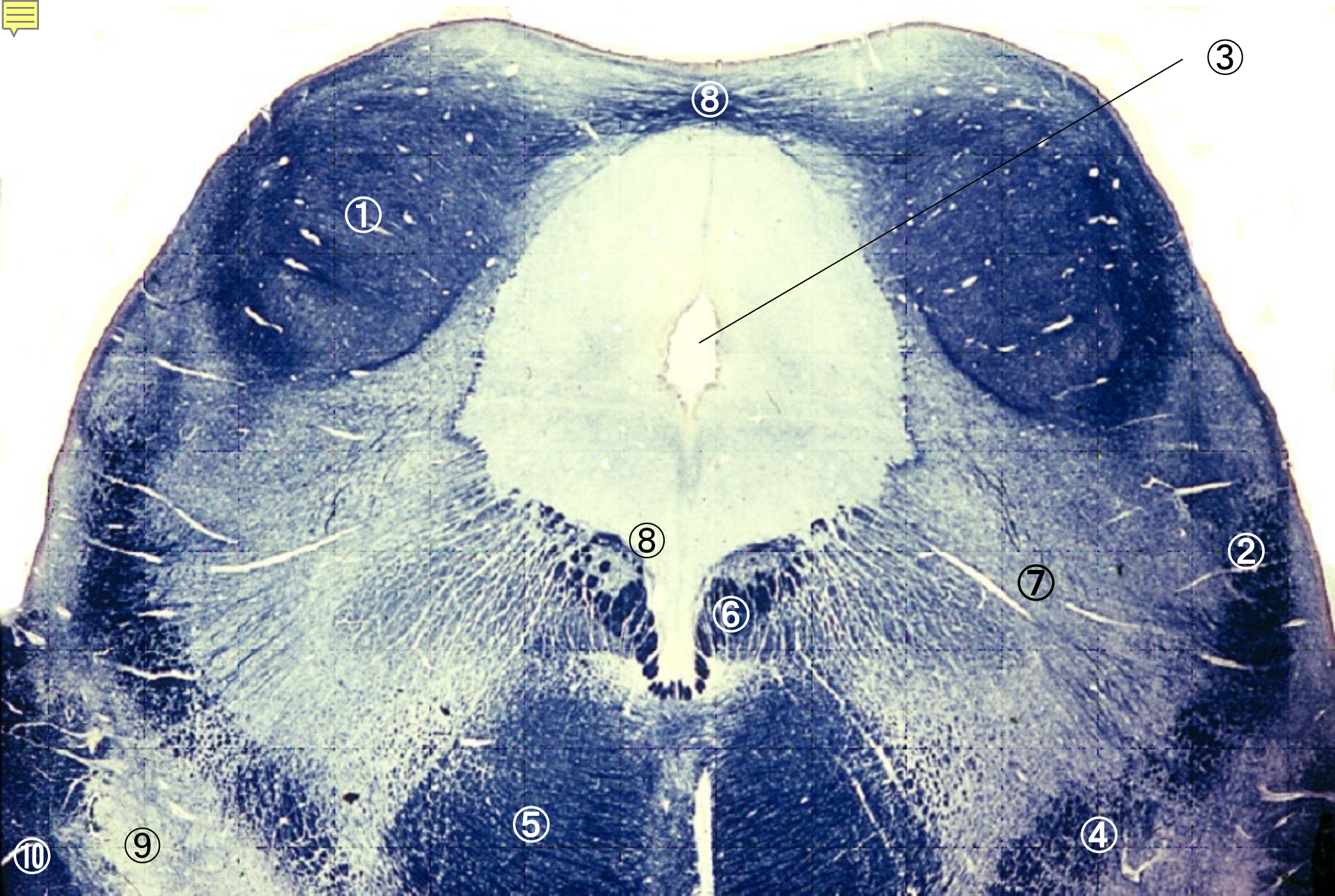22-15. Pons 3. The level of the nucl. motorius n. trigemini. x 1.4





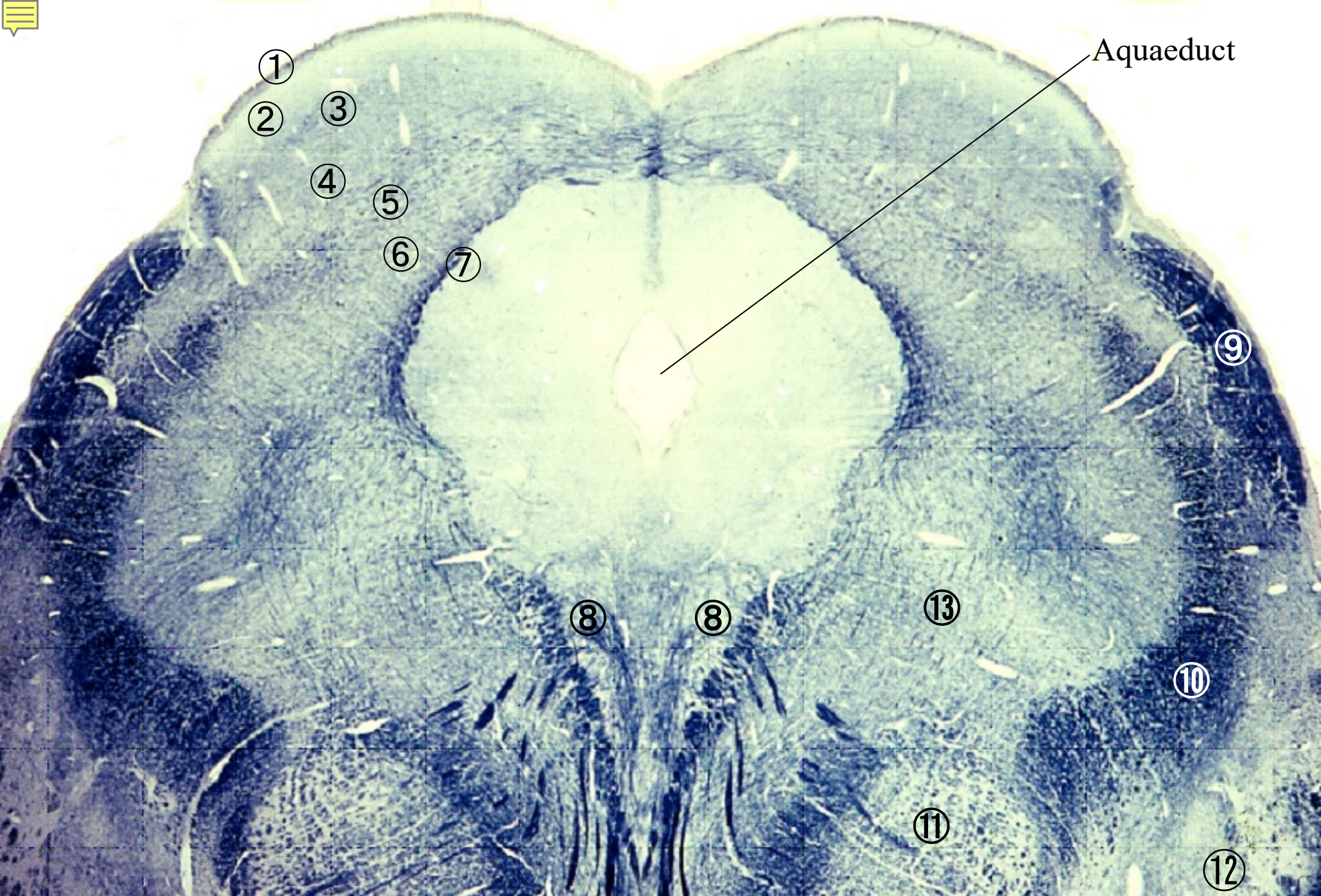
22-16. *Isthnus rhombencephali*. The caudal end of the midbrain. x 1.4





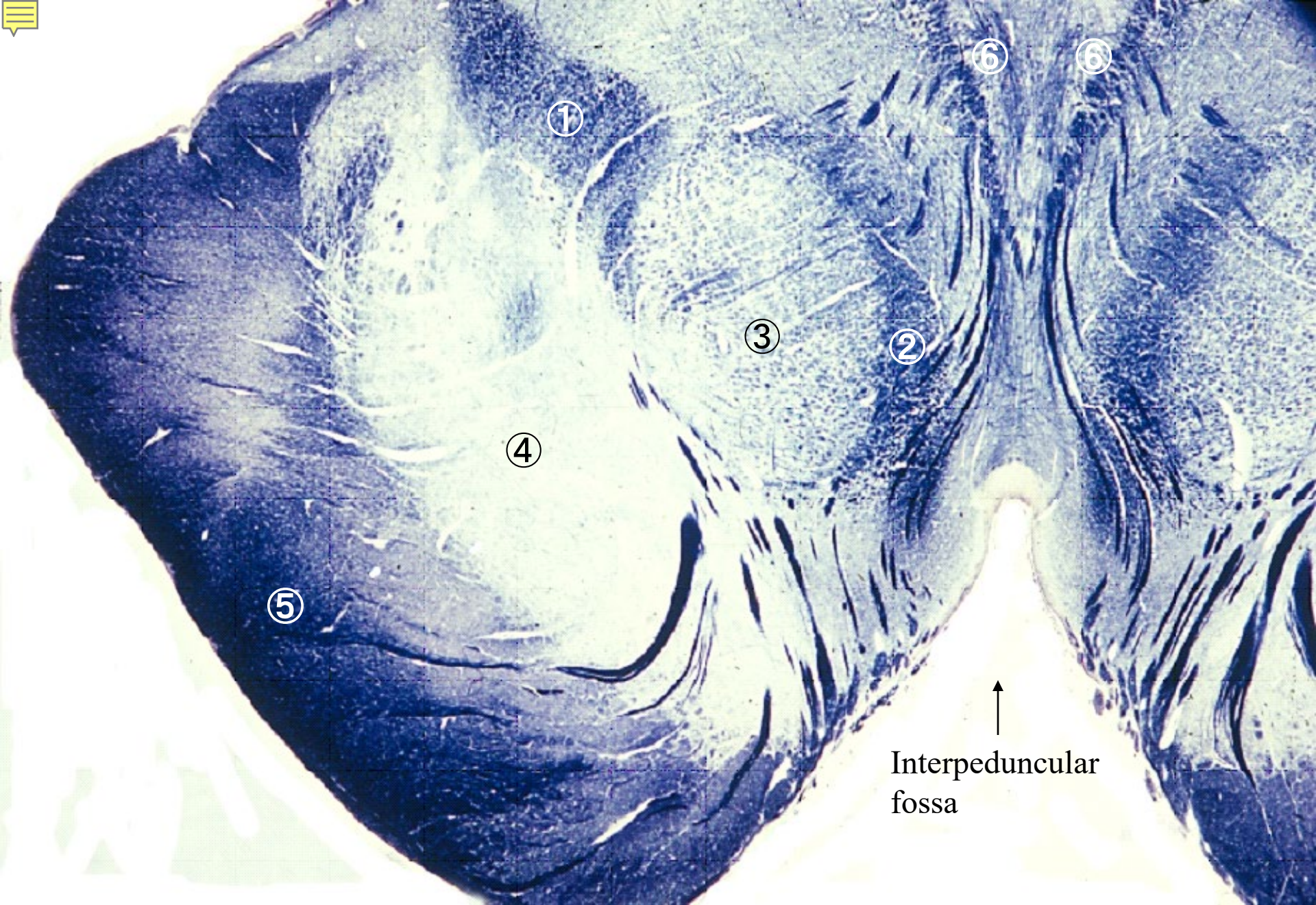
22-17. Mesencephalon 1. The level of the inferior colliculus. x 1.4





22-18. Mesencephalon 2. Dorsal half of the superior colliculus. x 1.4.





22-19. Mesencephalon 3. Ventral half of the superior colliculus. x 1.4.





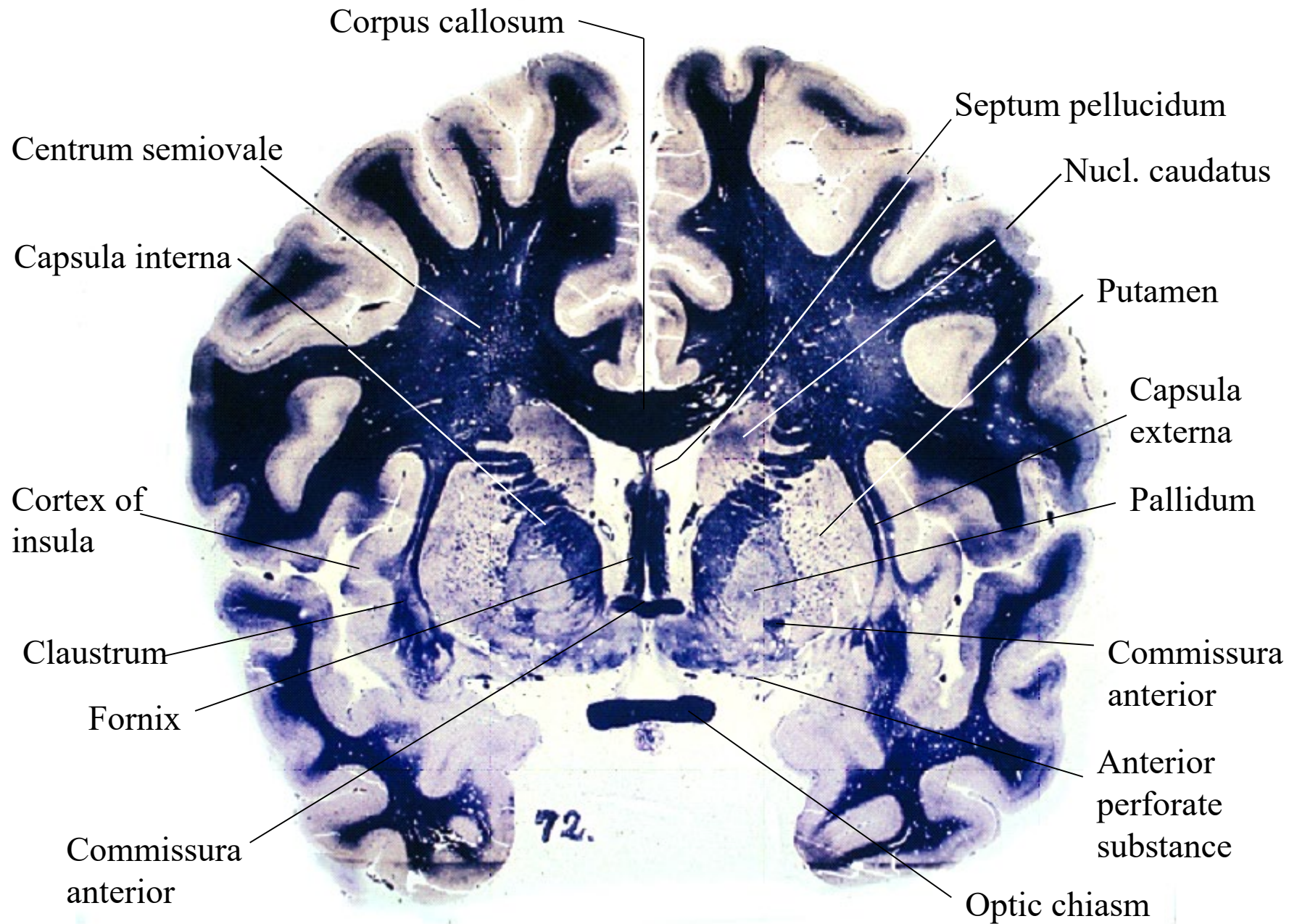
22-003

Cerebrum

(Frontal section,

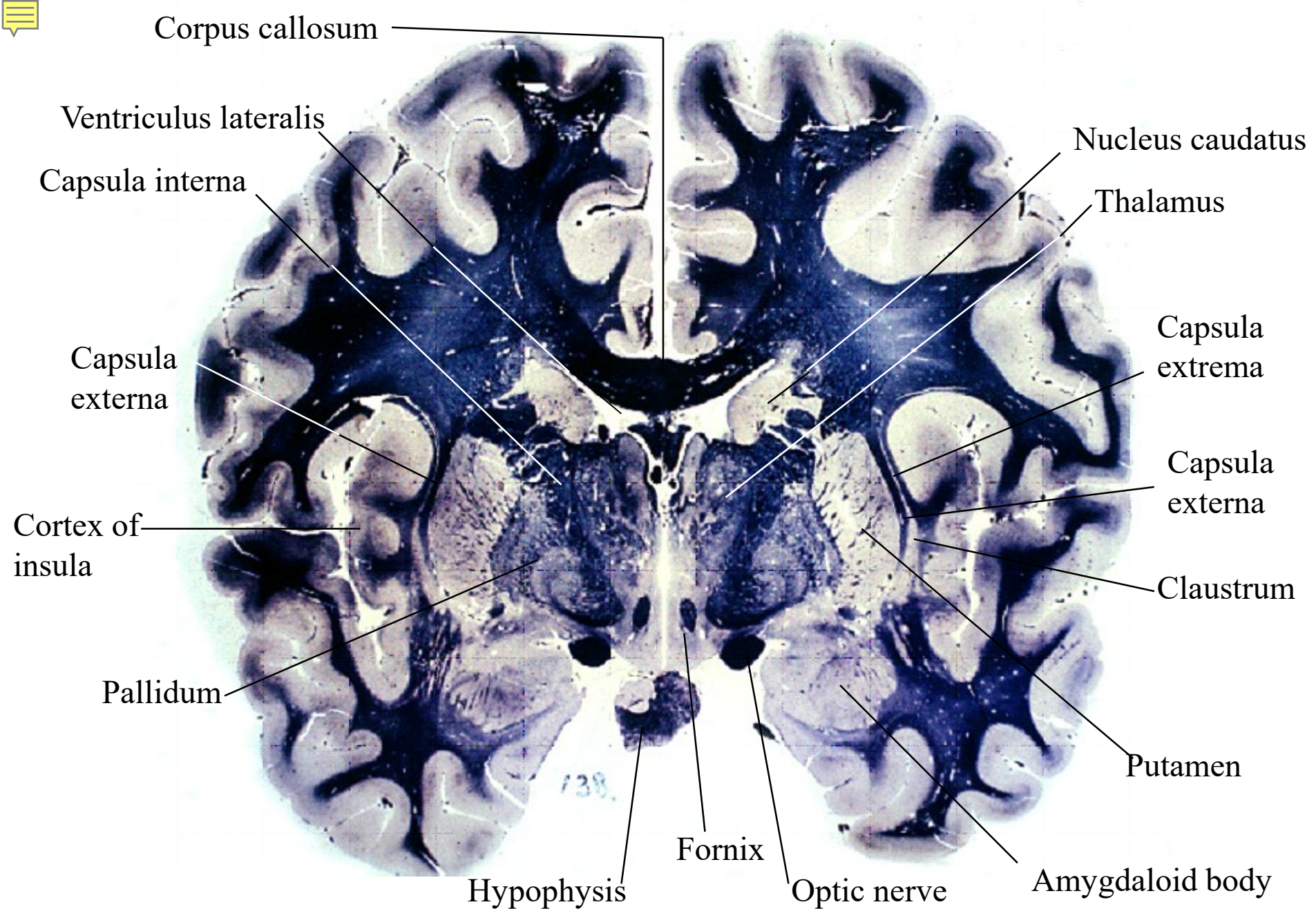
Weigrt stain)





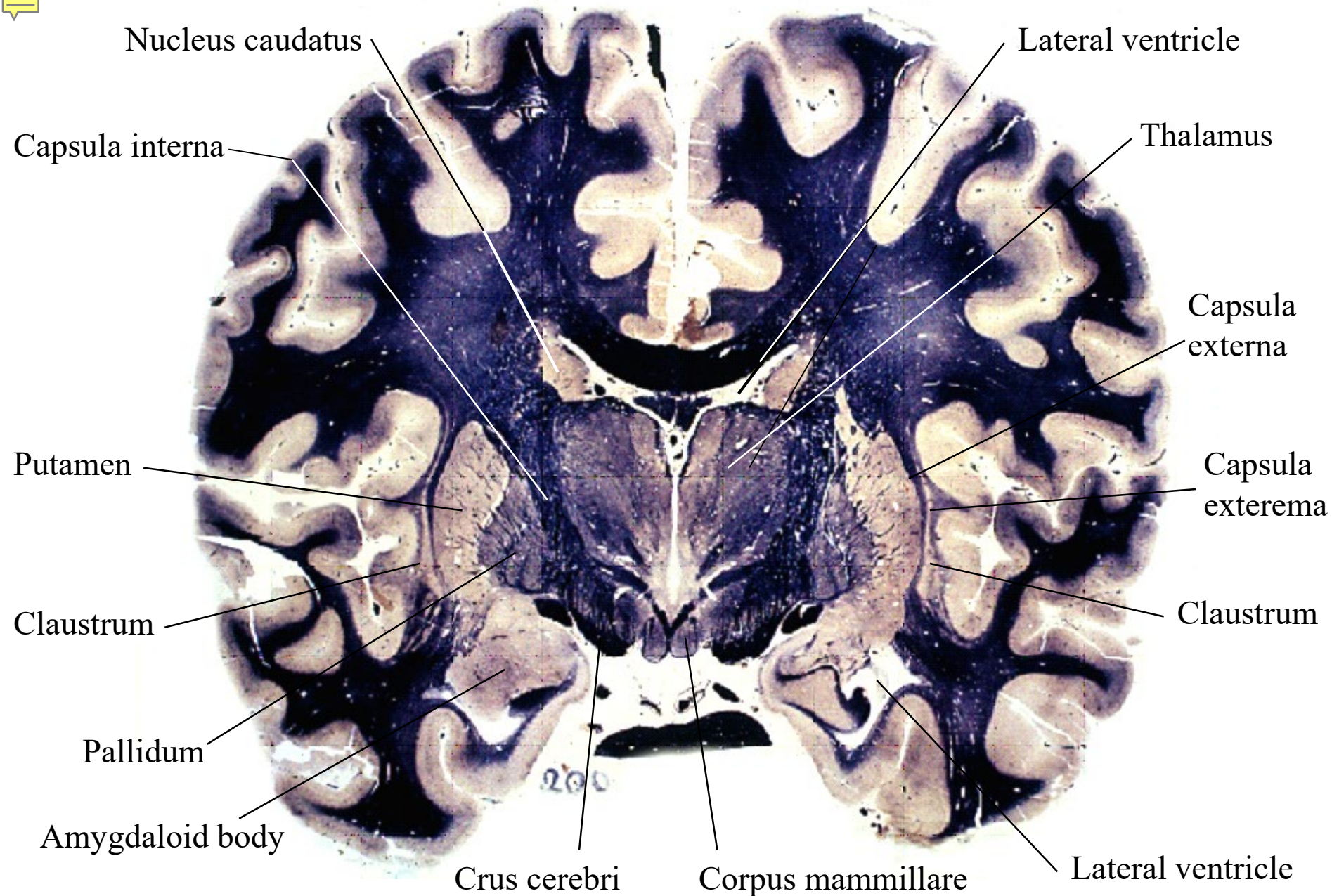
22-20. Cerebrum 1. The level of the commissura anterior. x 1/5.





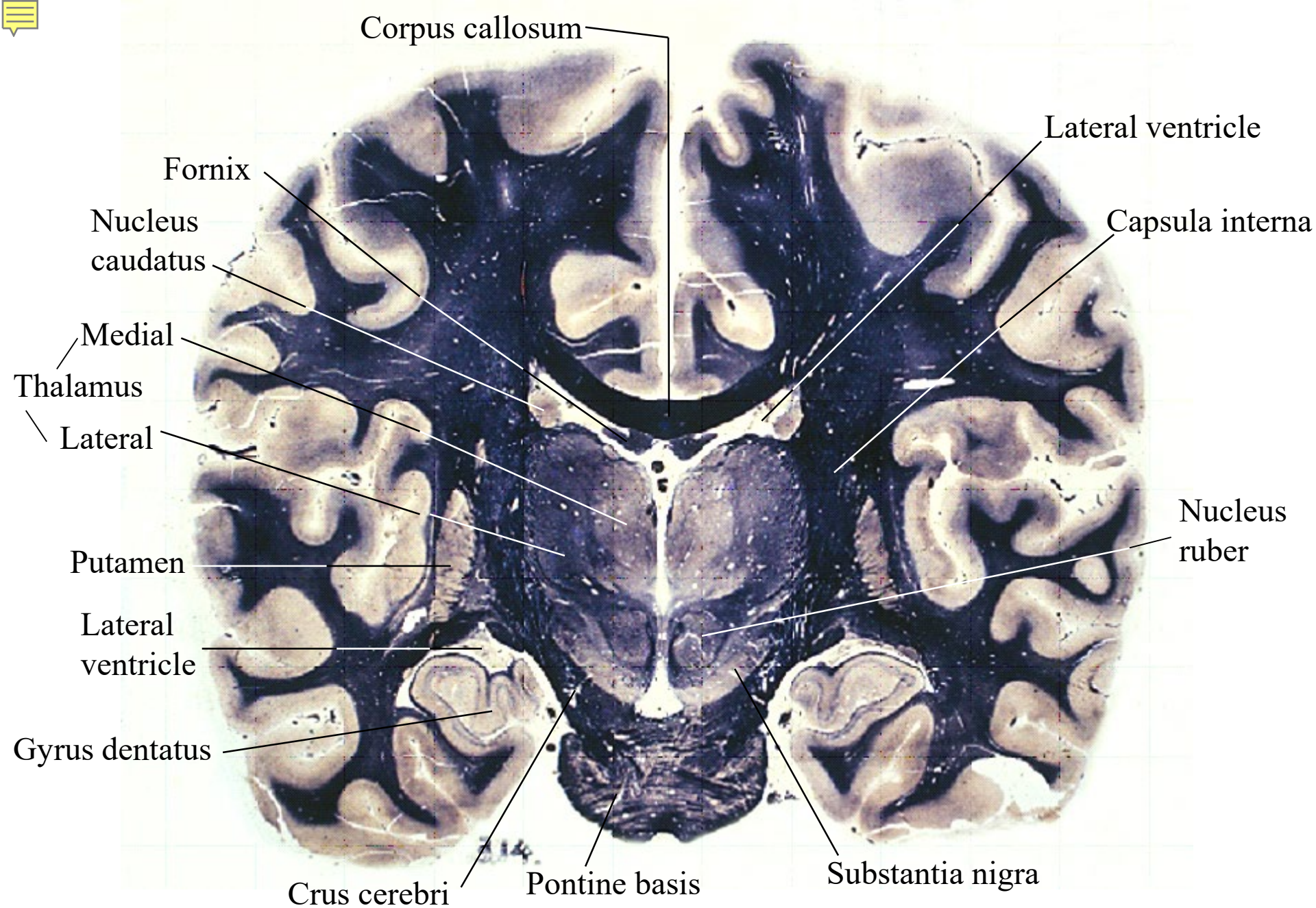
22-21. Cerebrum 2. The level of the Infundibulum. x 1/5.





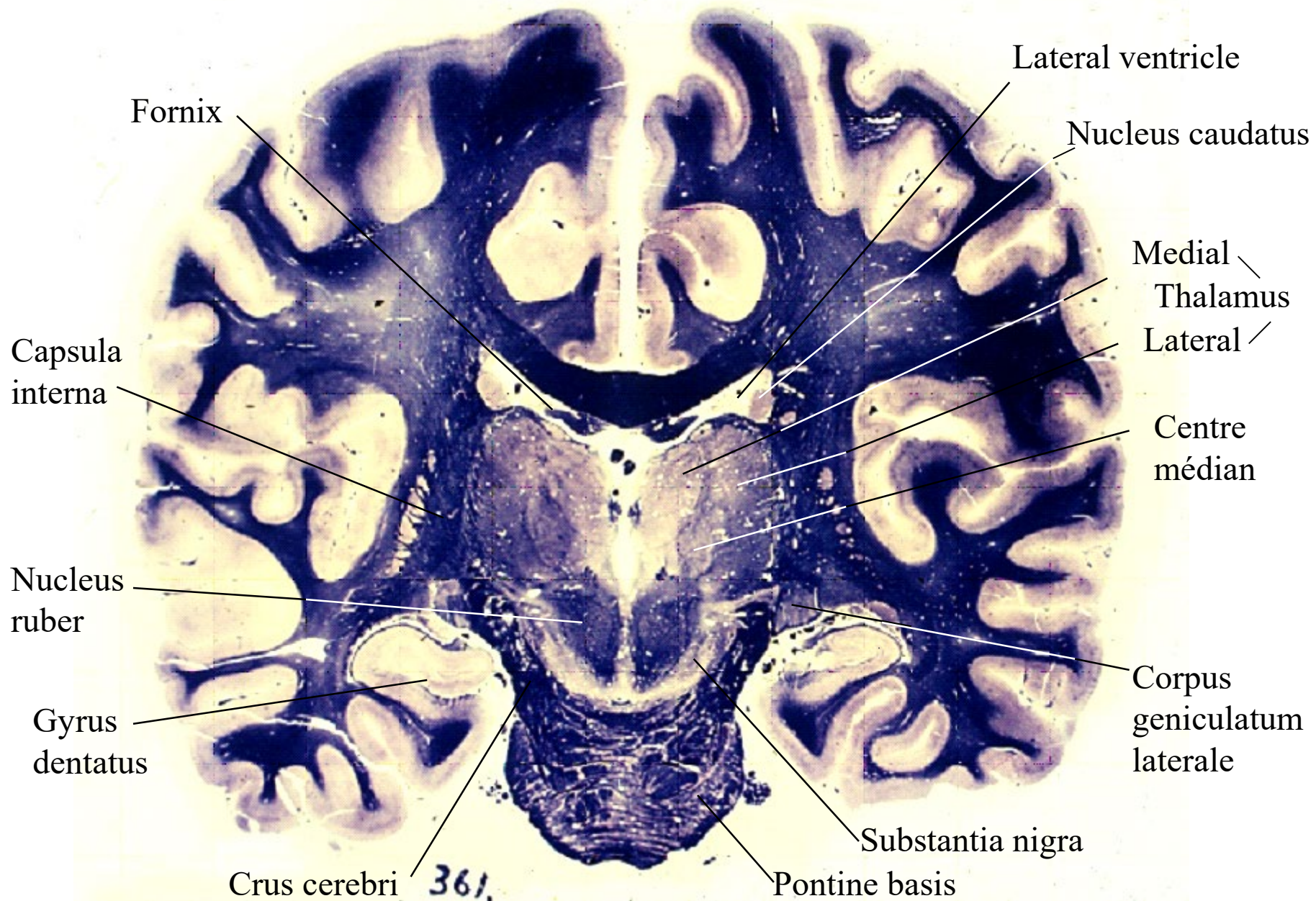
22-22. Cerebrum 3. The level of the corpus mammillare. x 1/5





22-23. Cerebrum 4. The level of the anterior portion of nucl. ruber. x 1/5.





22-24. Cerebrum 5. The level of the lateral geniculate body. x 1/5.





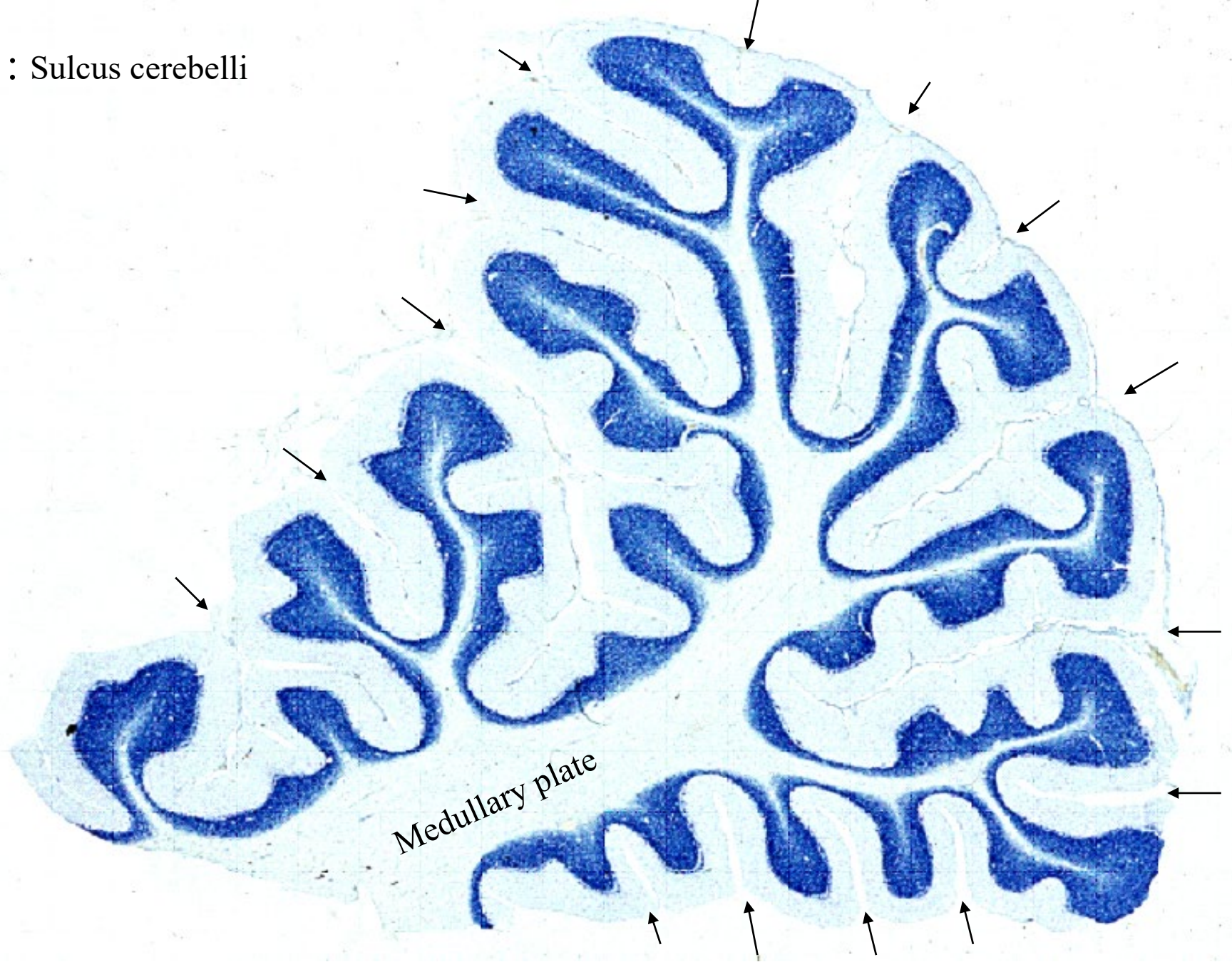
22-004

# Cerebellar Cortex



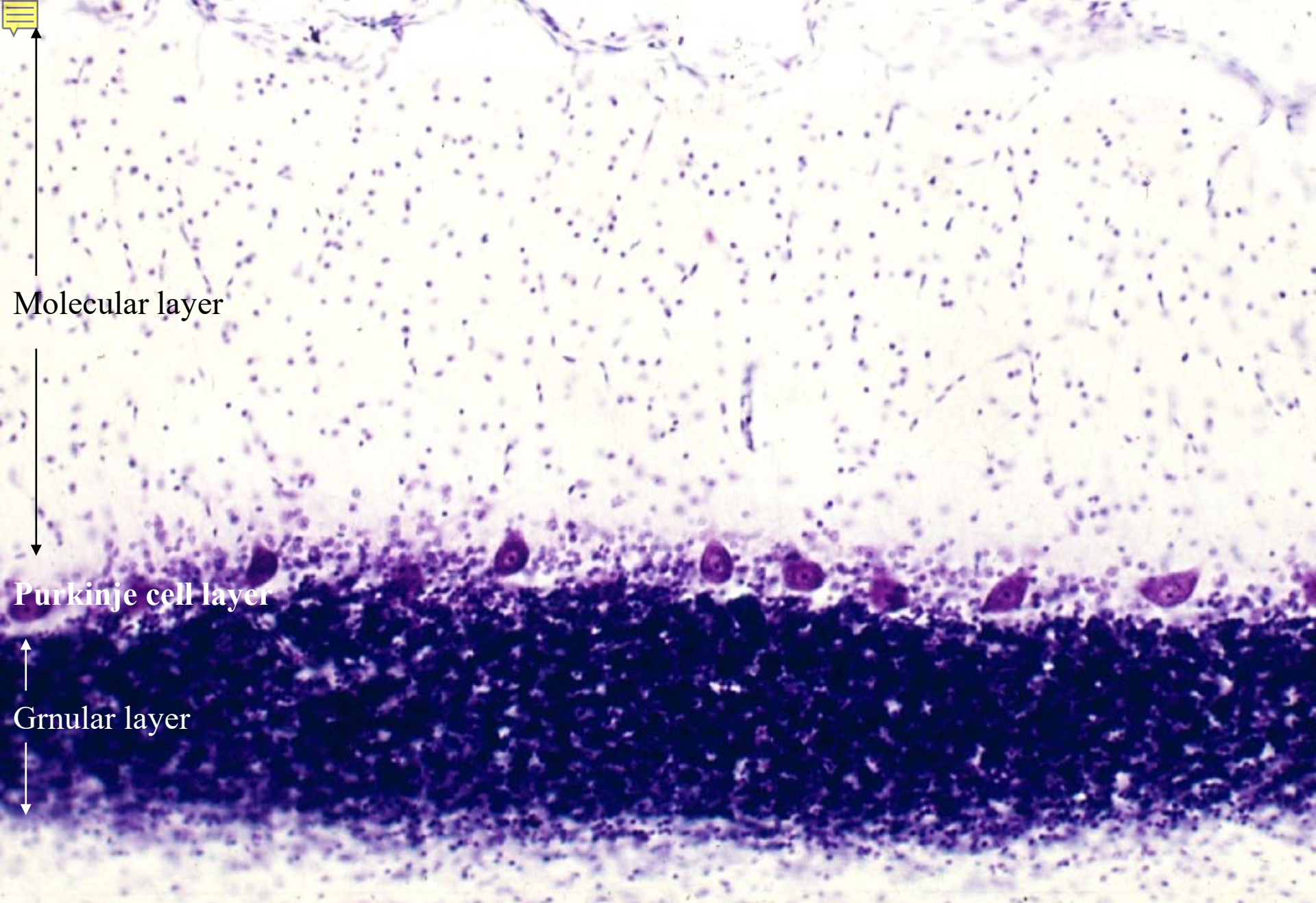


↓ : Sulcus cerebelli



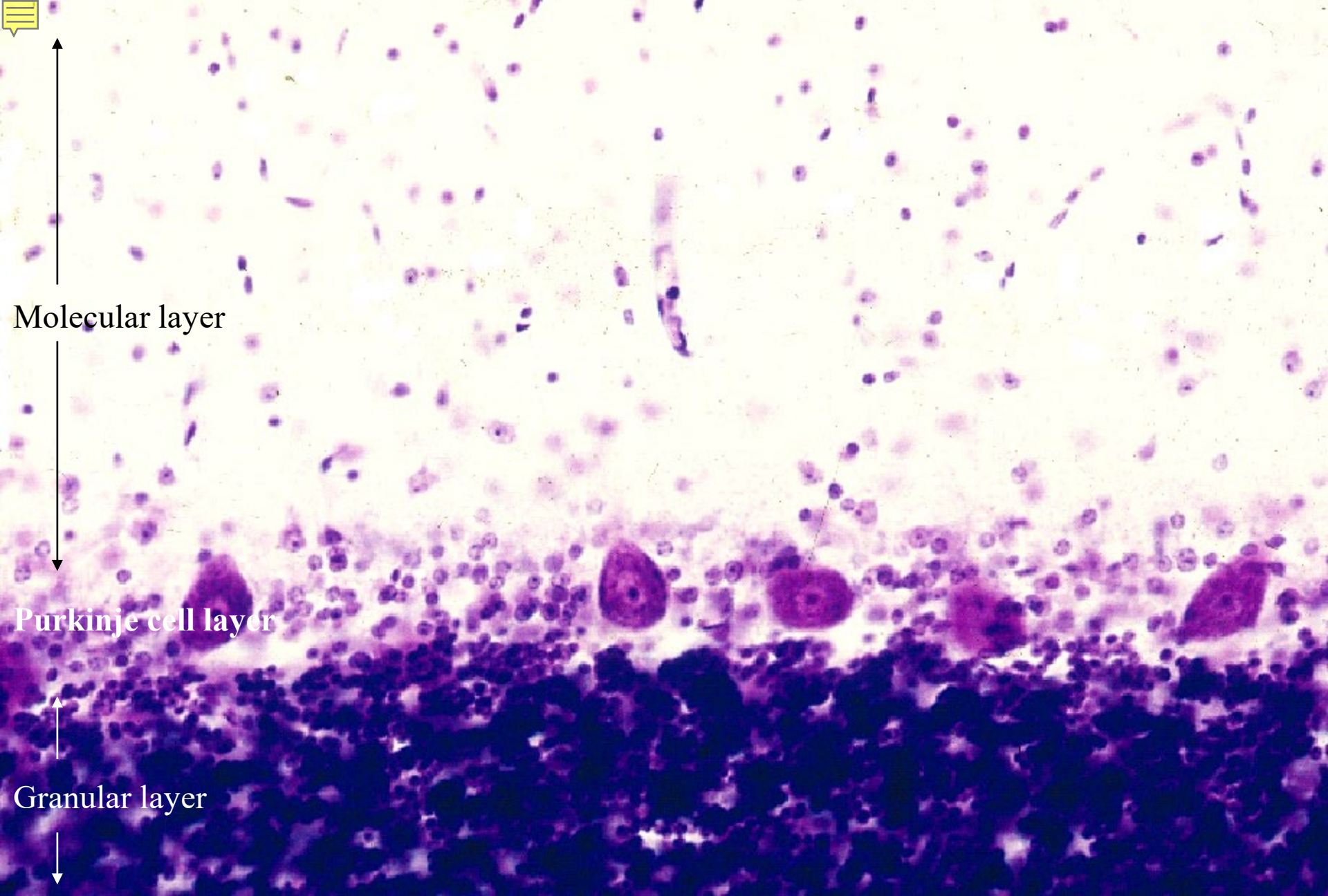
22-25. Lobus cerebelli. Sagittal section. Human, Nissl stain, x 1.7





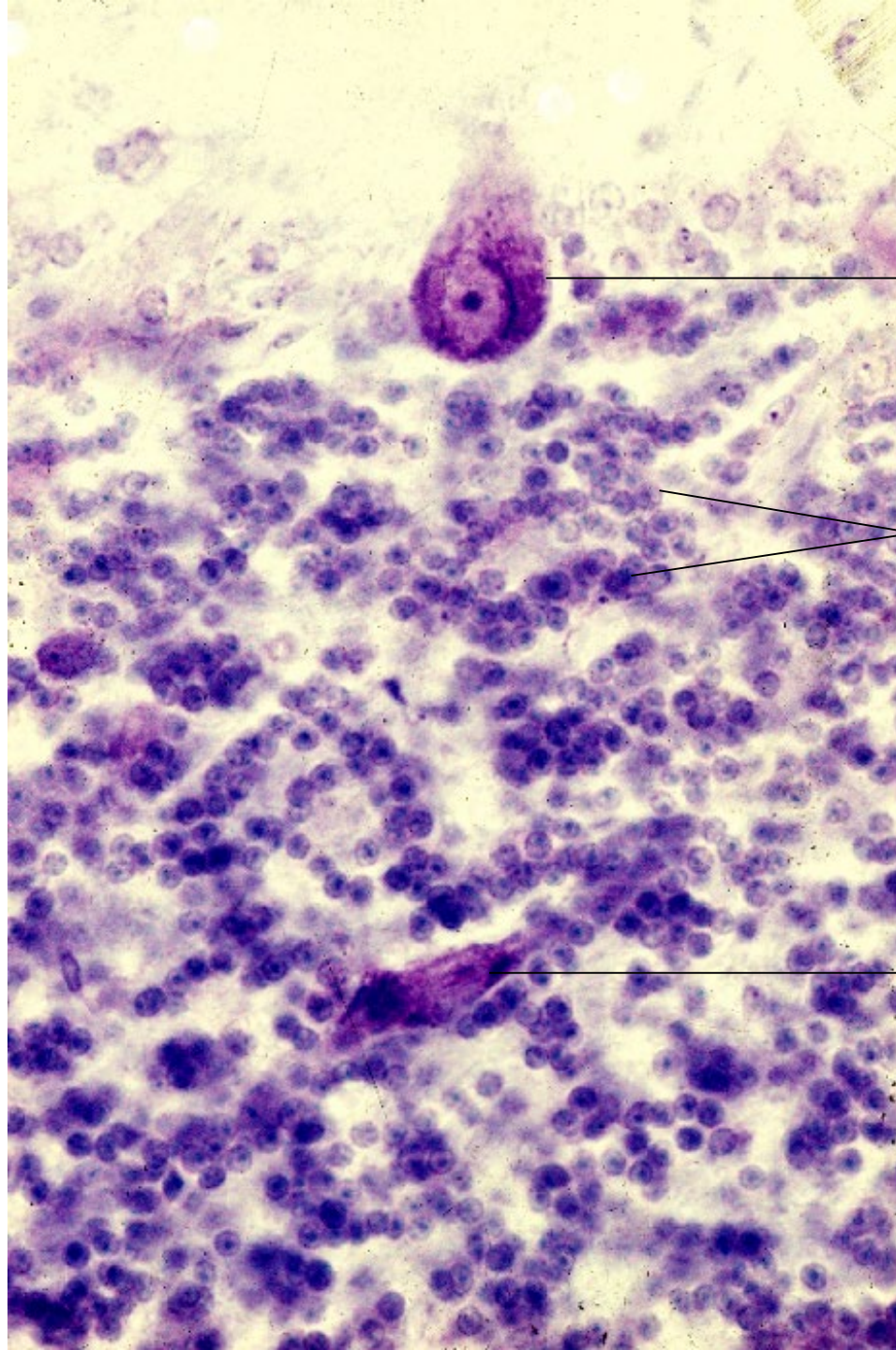
22-26. Cerebellar cortex 1. Human, Nissl stain, x 40.





22-27. Cerebellar cortex 2. Human, Nissl stain, x 64.





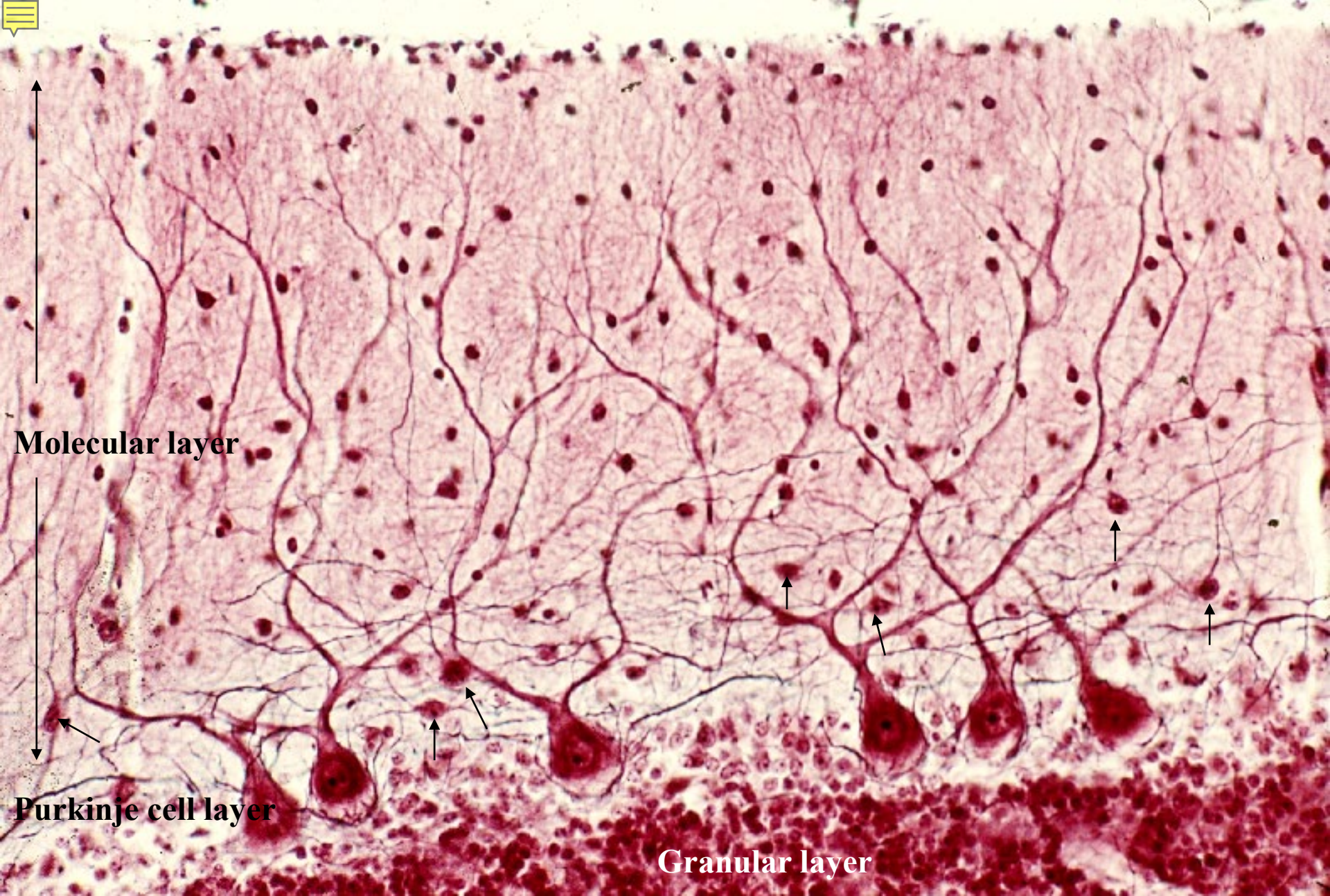
Purkinje cell

Granule cells

Nerve cell

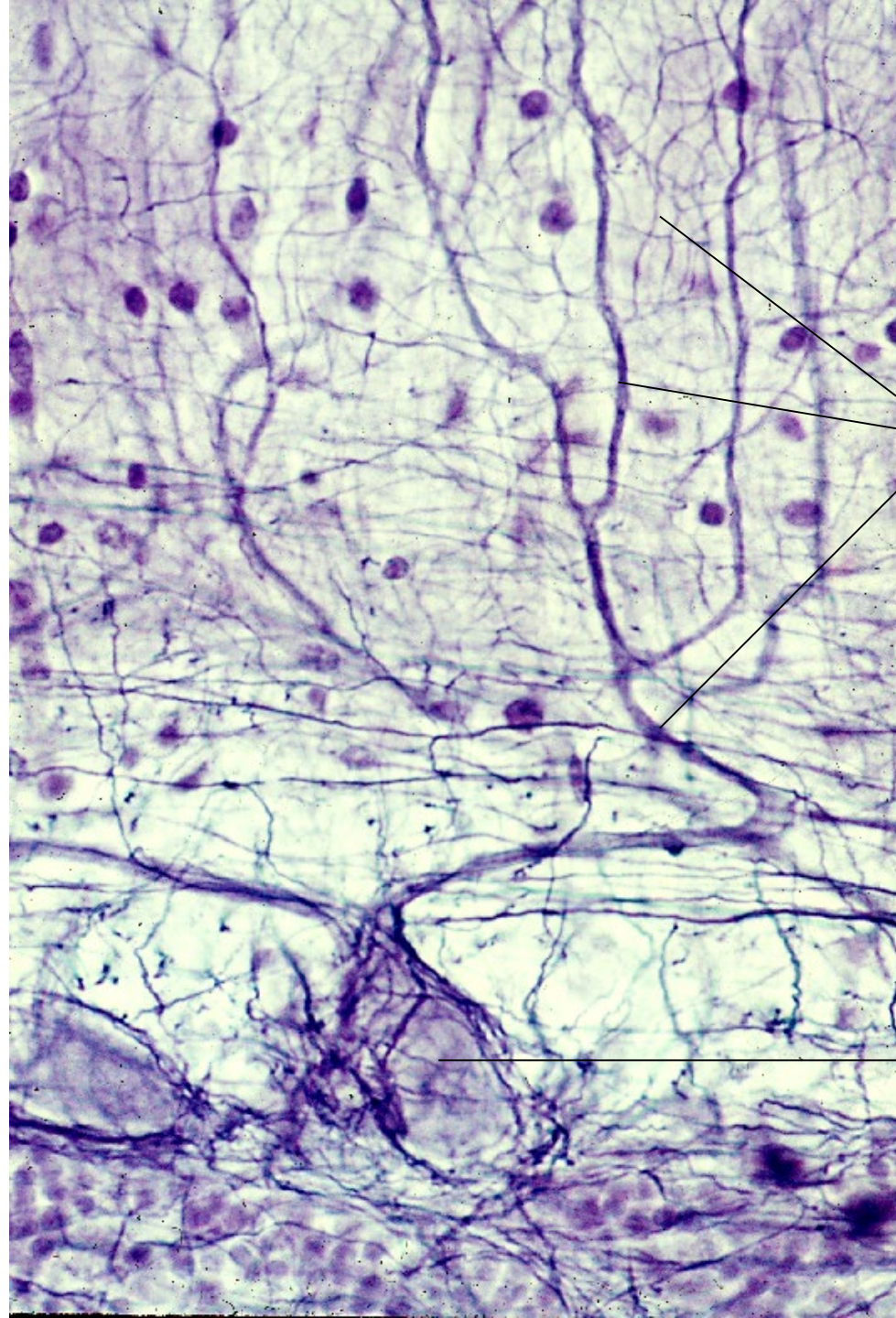
22-28.  
Cerebellar cortex  
3.  
Human,  
Nissl stain,  
x 160.





22-29. Cerebellar cortex 4. Dog, Bodian's silver impregnation, x 64.



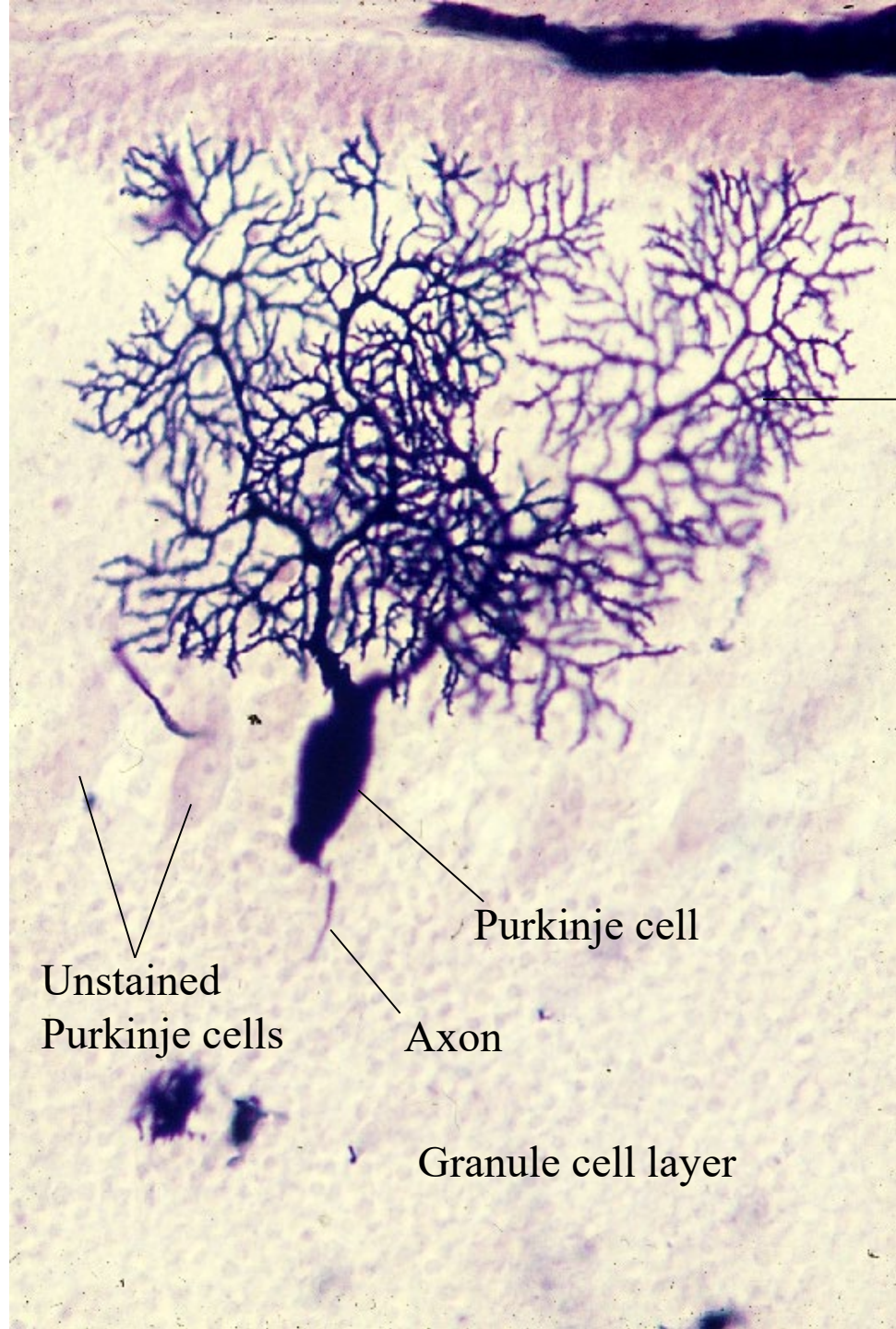


Dendrites

Purkinje  
cell

22-30.  
Cerebellar cortex  
5.  
Human,  
Suzuki's silver  
impregnation,  
x 160.





Dendrite

Unstained  
Purkinje cells

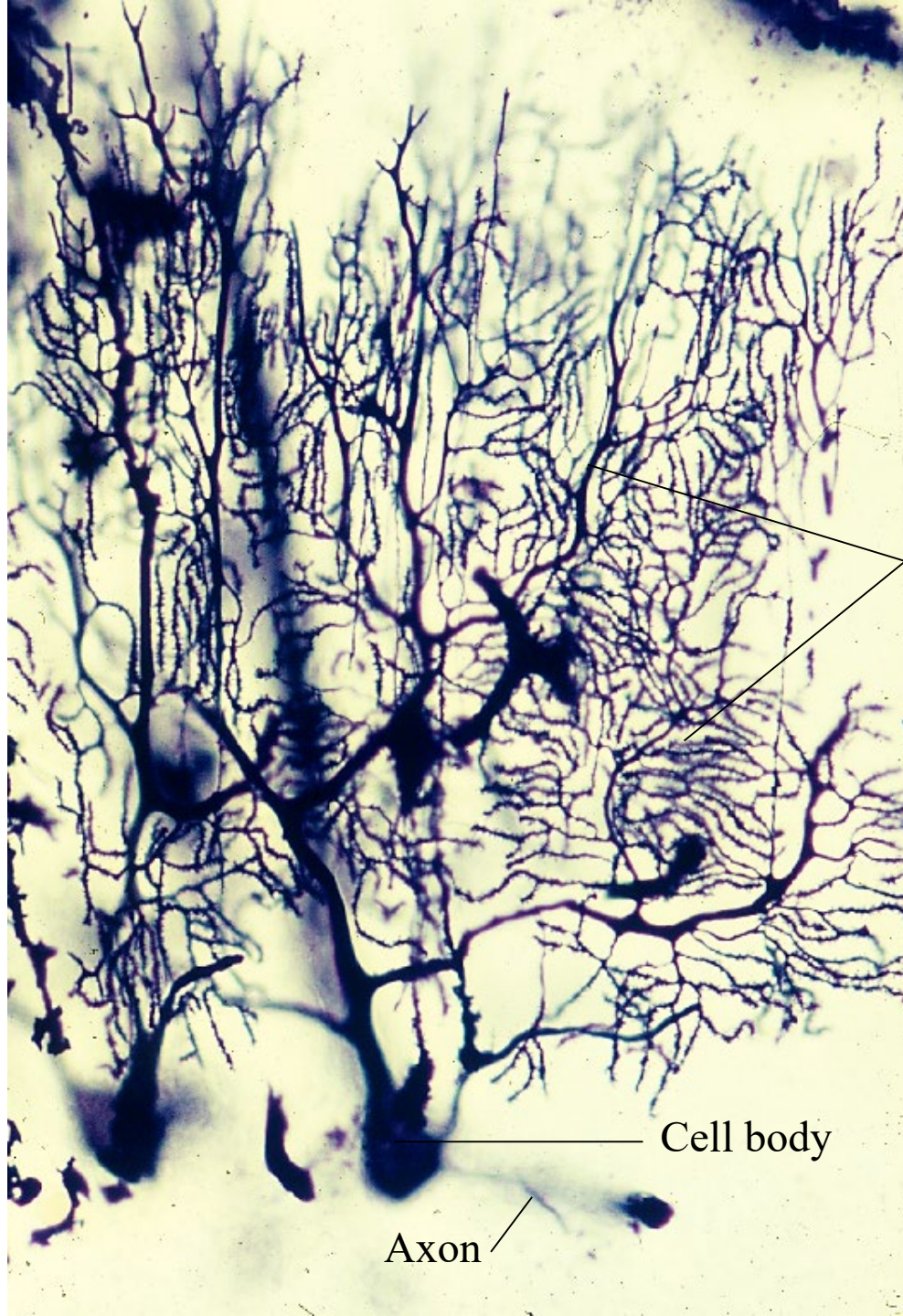Purkinje cell

Axon

Granule cell layer

22-31.  
Cerebellar cortex  
6.  
Dog,  
Golgi silver  
impregnation,  
x 80.





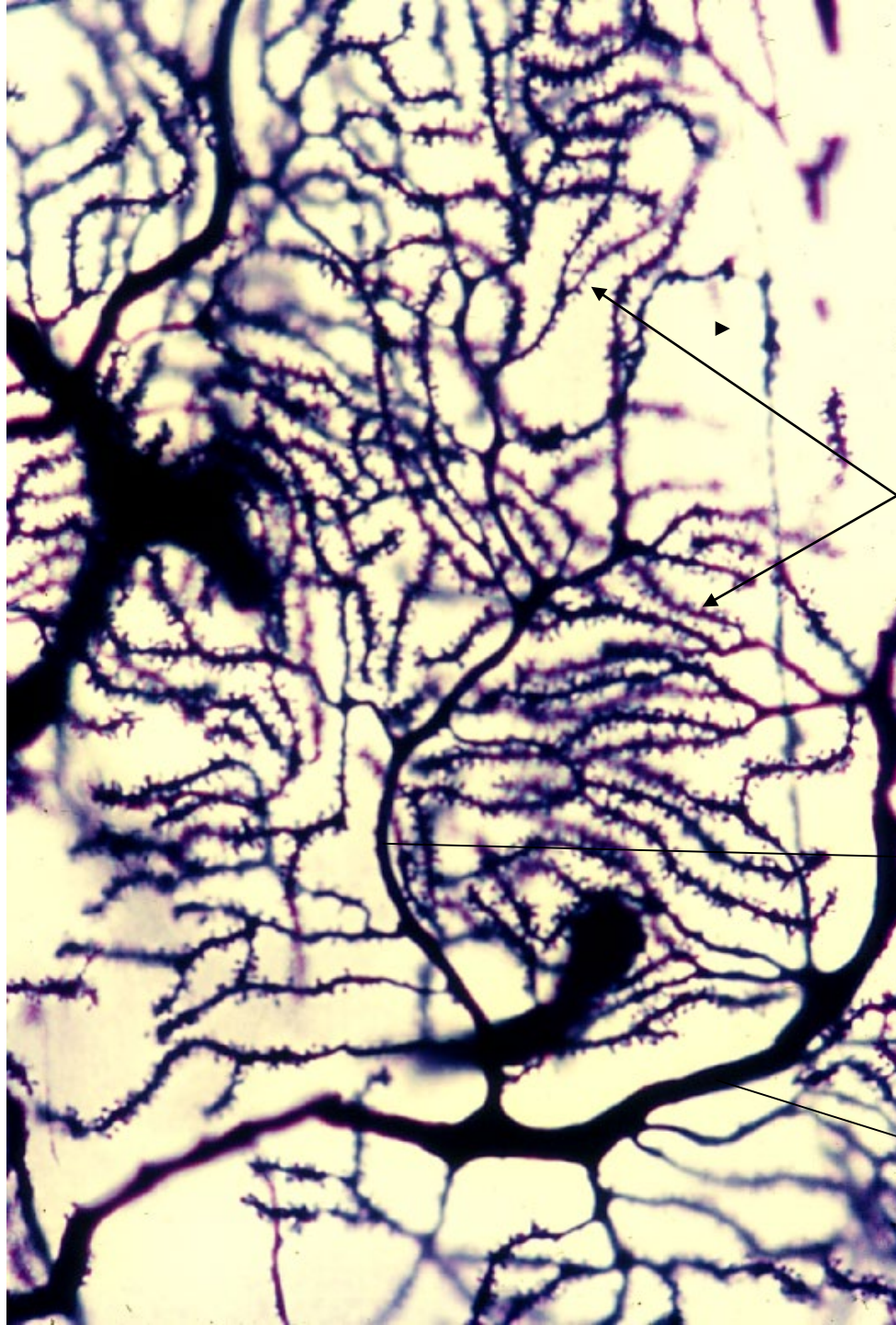
Dendrites

Cell body

Axon

22-32.  
Cerebellar cortex  
7.  
Human,  
Golgi silver  
impregnation,  
x 80.





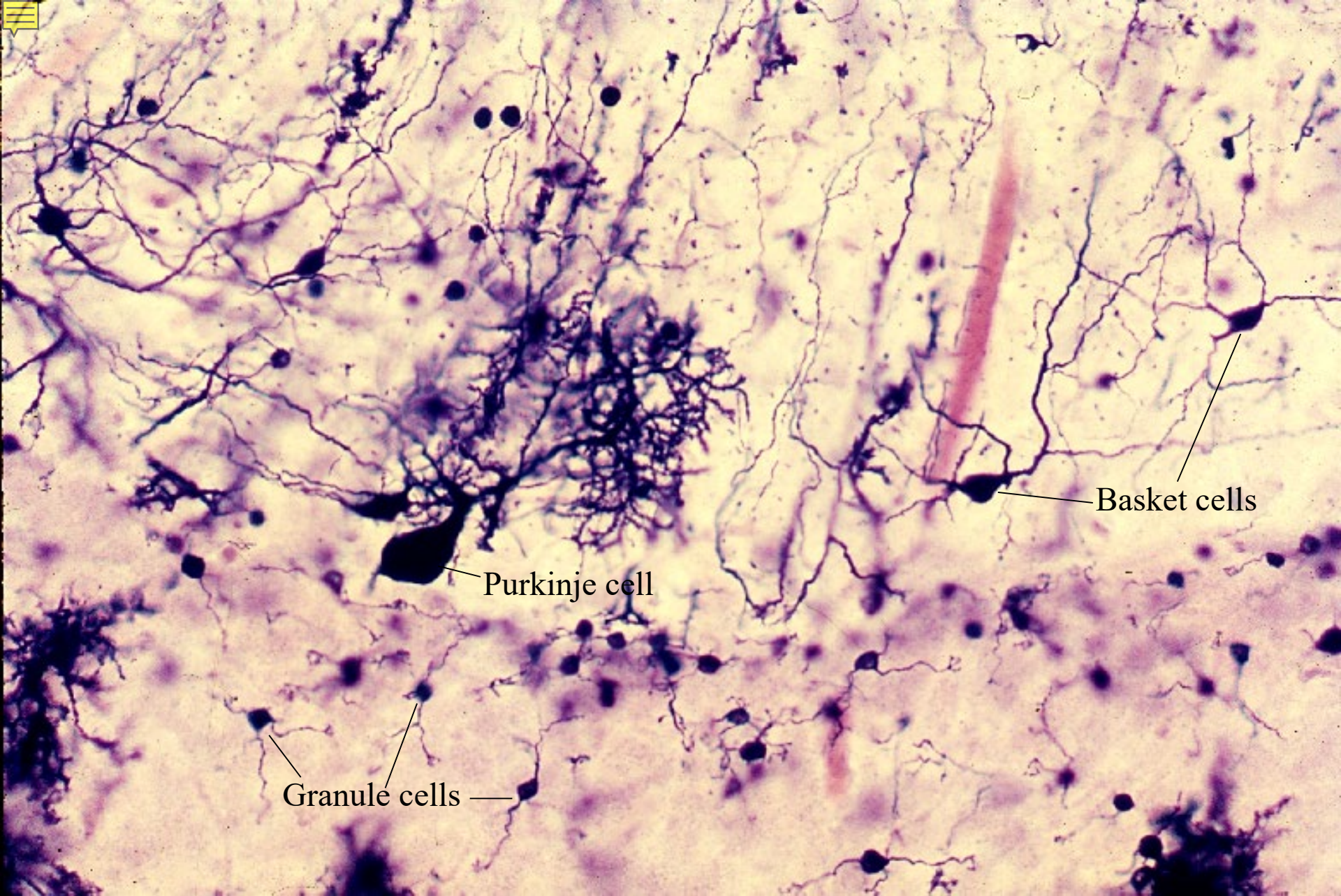
Spines on the  
terminal dendrites

Tertiary  
dendrite

Secondary  
dendrite

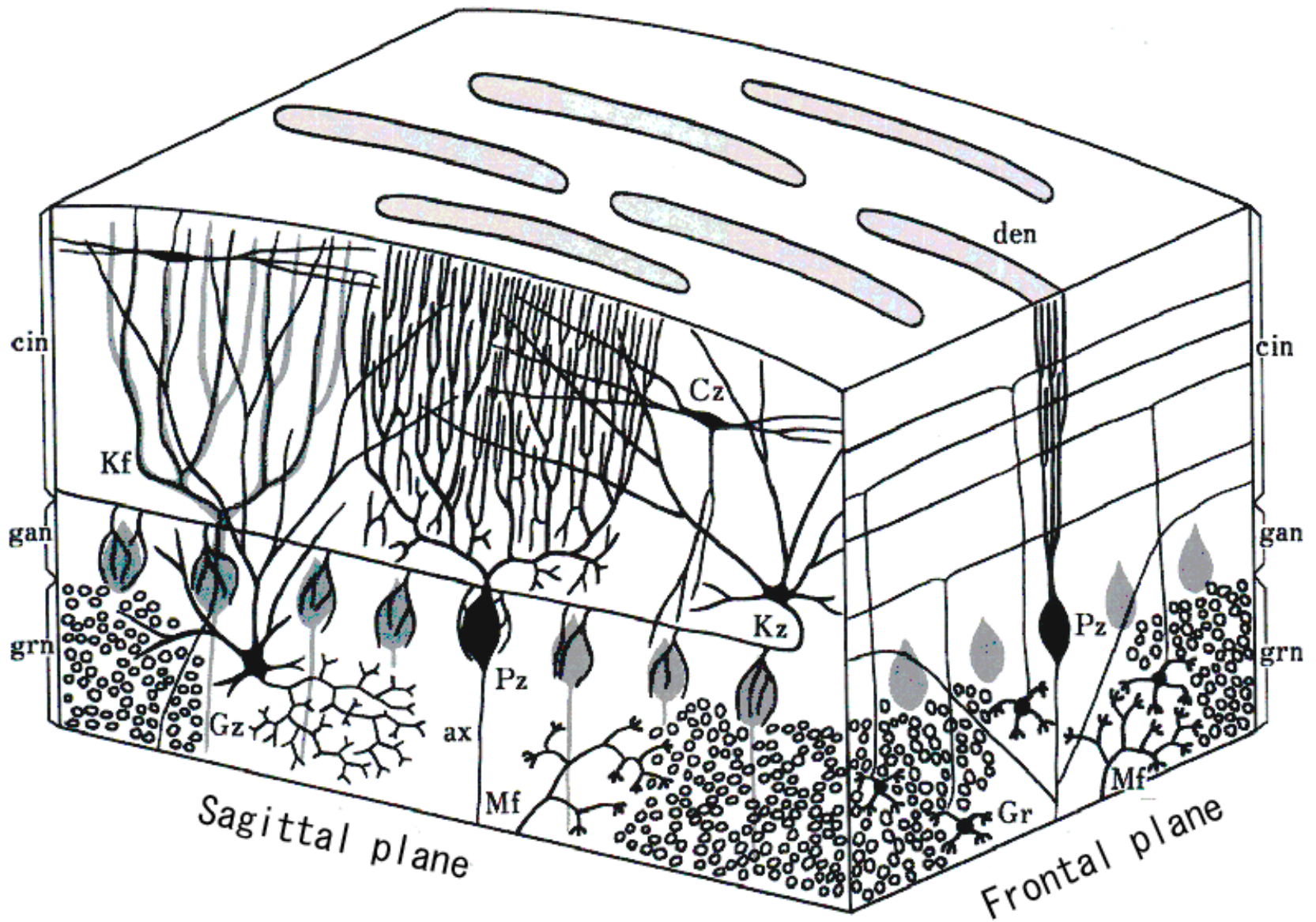
22-33.  
Cerebellar cortex  
8.  
Human,  
Golgi silver  
impregnation,  
x 200.





22-34. Cerebellar cortex 9. Cat, Golgi silver impregnation, x 64.





22-35. Scheme showing the three dimensional structure of the cerebellar cortex.





22-005

# Cerebral Cortex

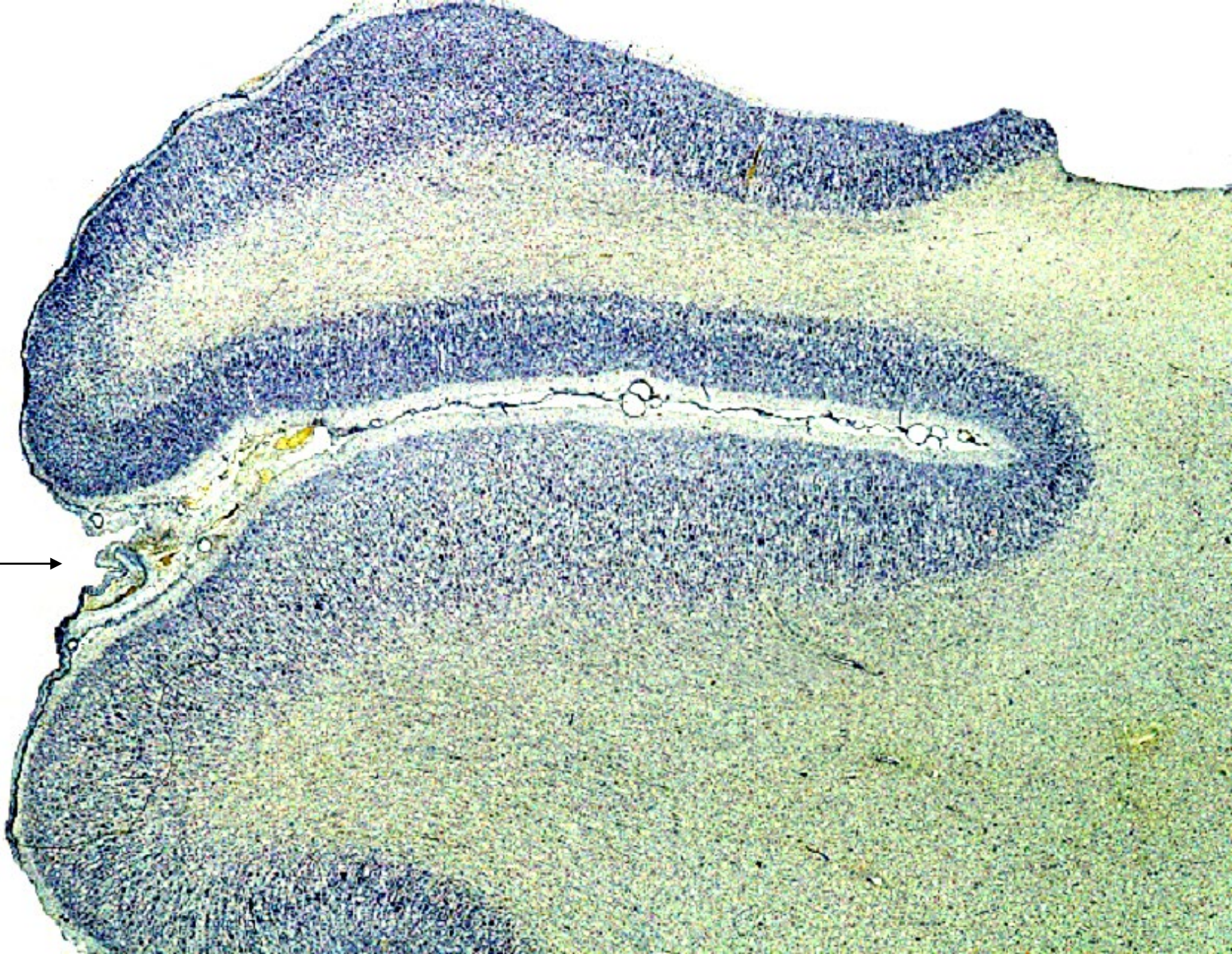




Gyrus  
postcentralis

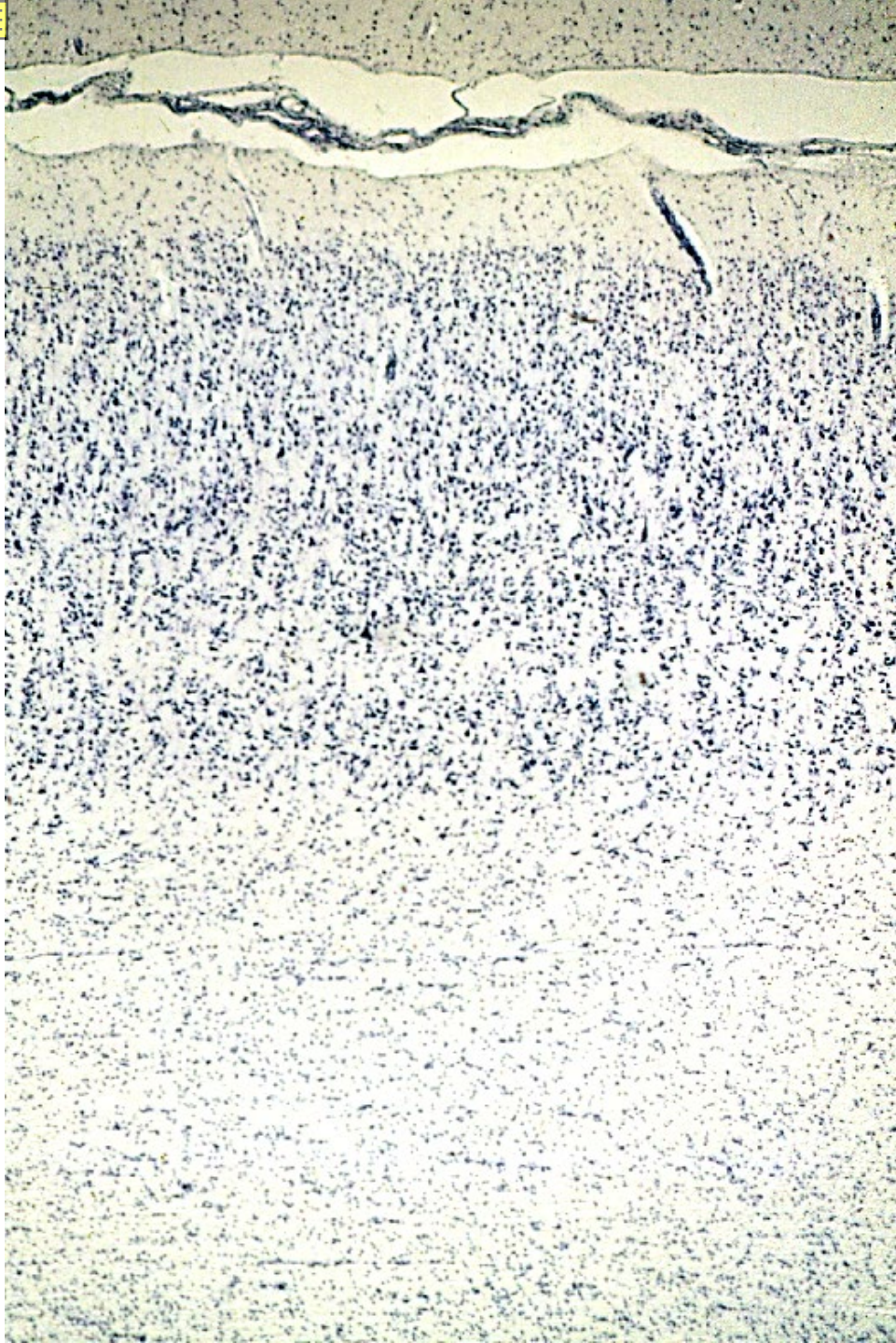
Sulcus  
centralis →

Gyrus  
precentralis



22-36. Gyrus precentralis et postcentralis. Human, Nissl stain, x 1.5.

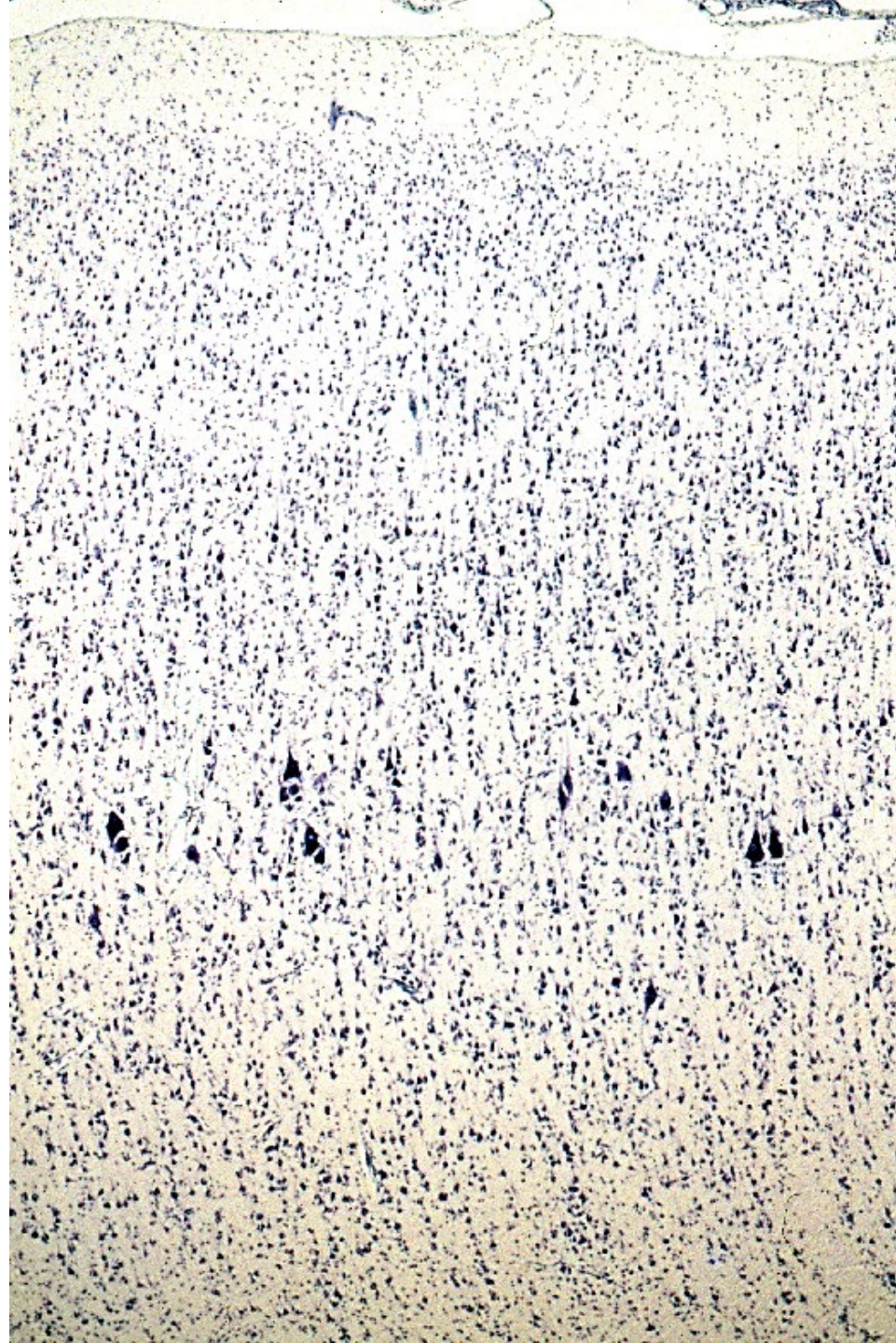



I  
II  
III  
IV  
V  
VI

22-37.  
Area 3.  
Human,  
Nissl stain,  
x 10.





I

II

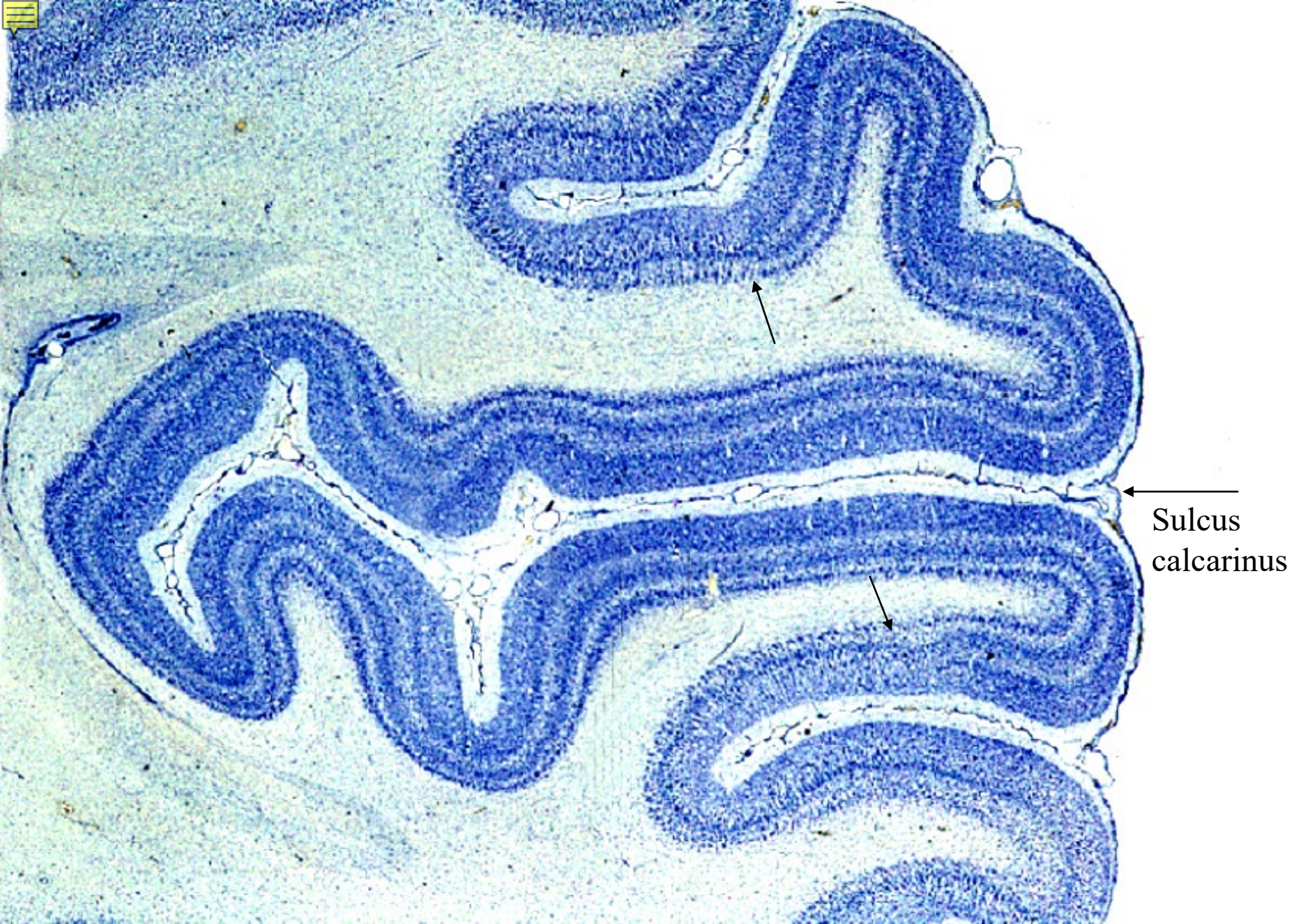
III

V

VI

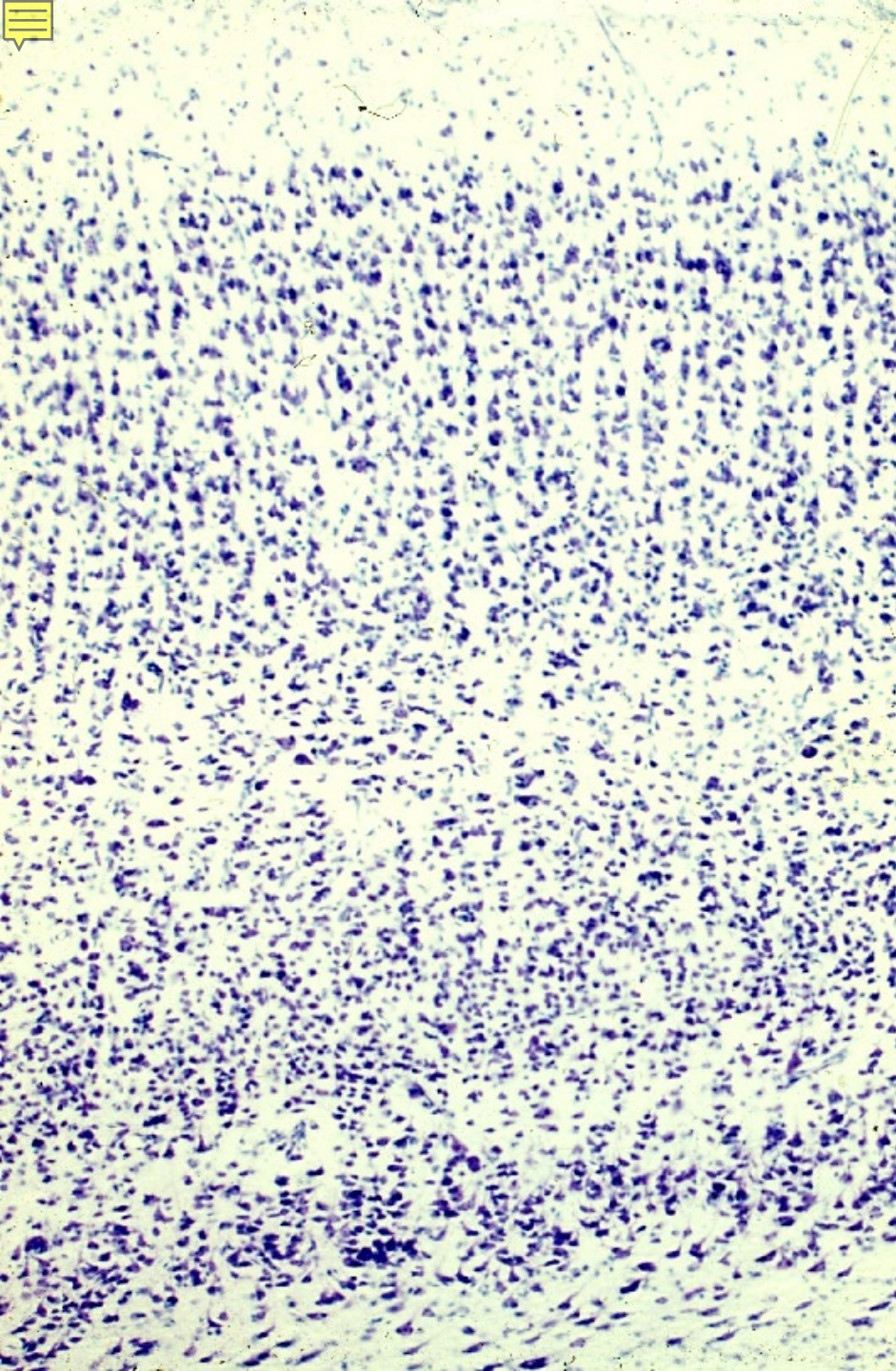
22-38.  
Area 4.  
Human,  
Nissl stain,  
x 10.





22-39. Cerebral cortex surrounding the sulcus calcarinus. Human, Nissl stain, x 1.5.





I

II

III

IVa

IVb

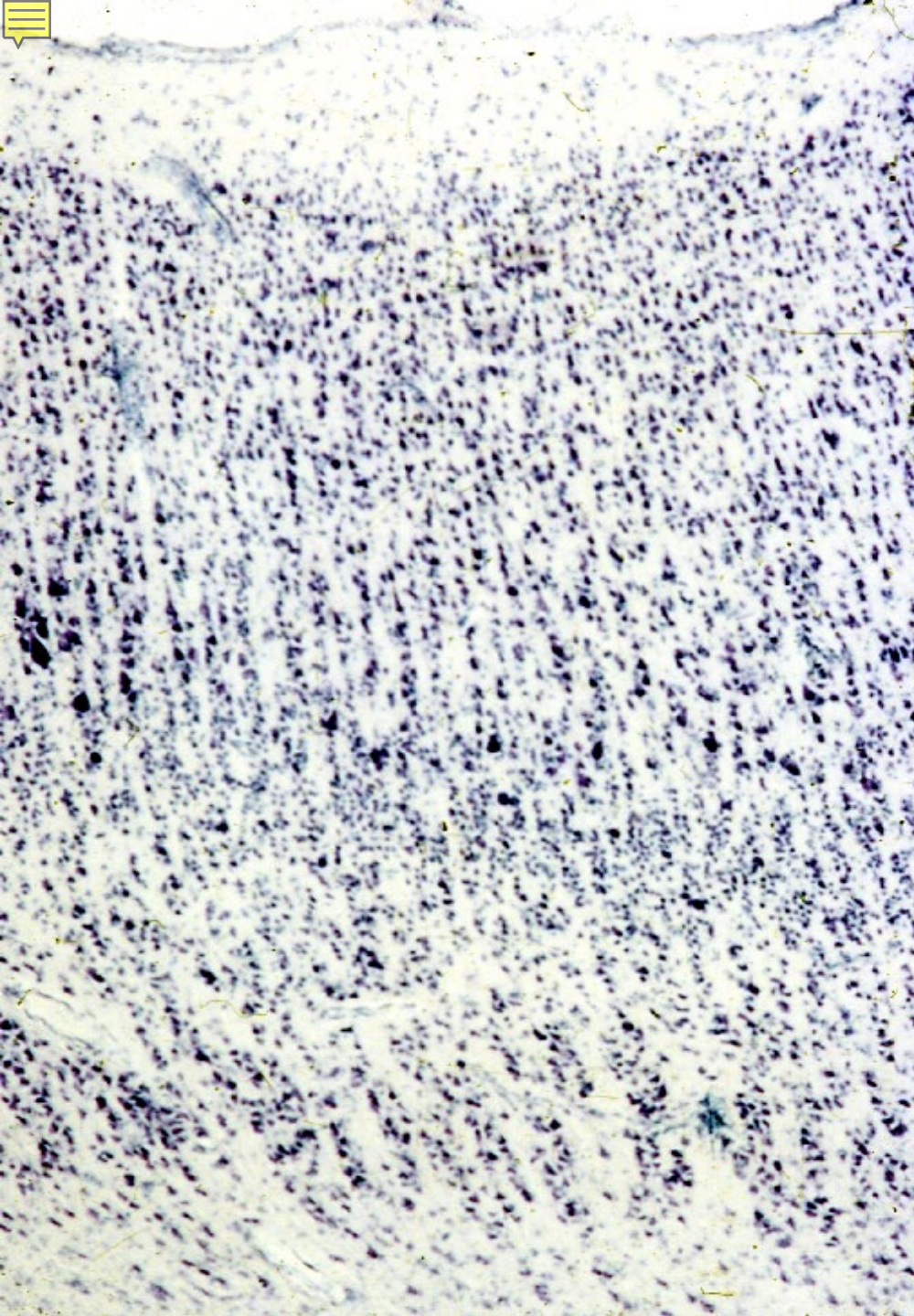
IVc

V

VI

22-40.  
Area17.  
Human,  
Nissl stain,  
x 25.





I

II

III

IV

V

VI

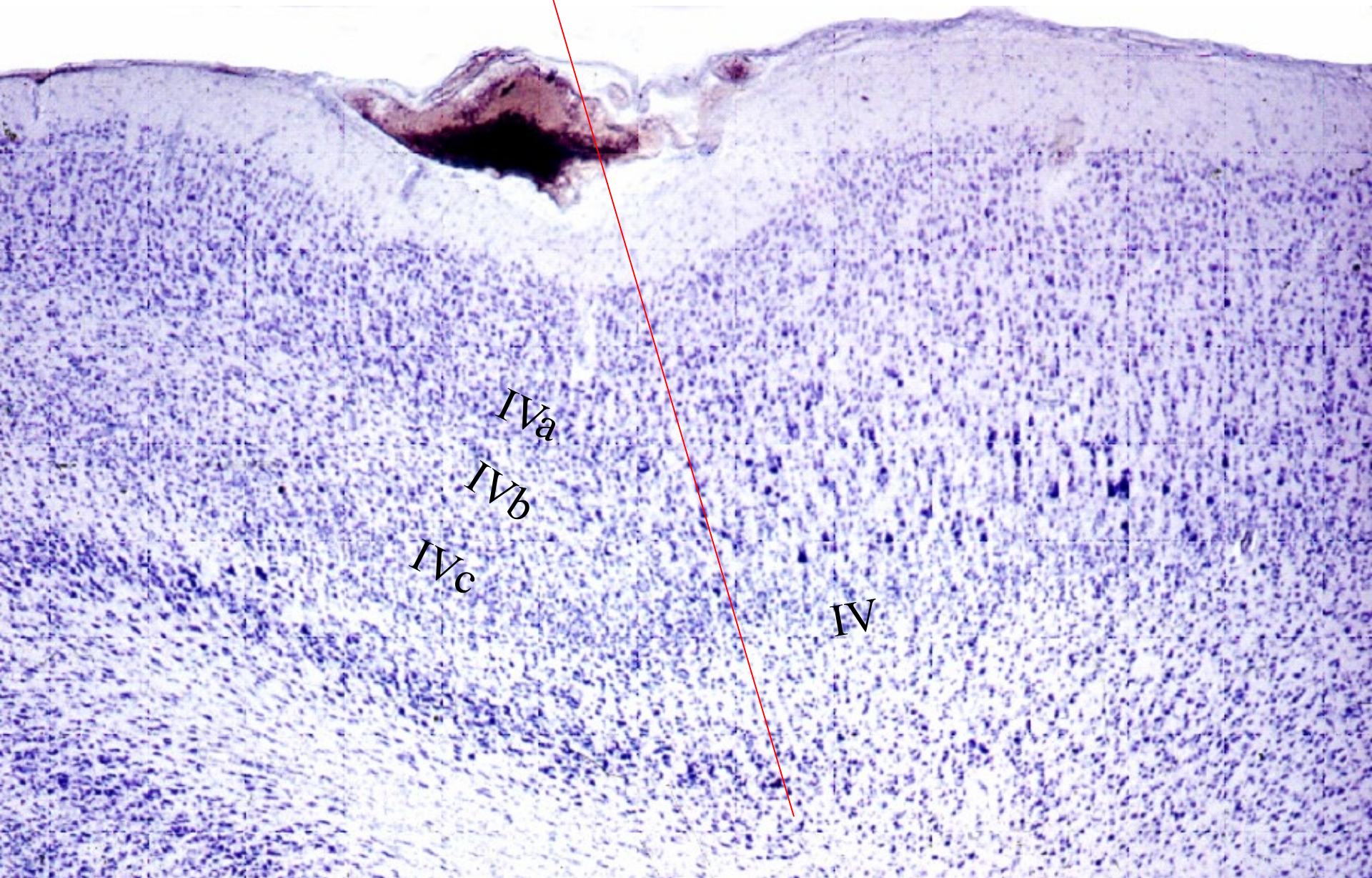
22-41.  
Area 18.  
Human,  
Nissl stain,  
x 25.





Area 17

Area 18



22-42. Area 17 and Area 18. Human, Nissl stain, x 10.