



# The First Japanese Familial Sotos Syndrome with a Novel Mutation of the NSD1 Gene

Tei, Satoshi

---

(Degree)

博士 (医学)

(Date of Degree)

2006-03-25

(Date of Publication)

2012-08-07

(Resource Type)

doctoral thesis

(Report Number)

甲3595

(URL)

<https://hdl.handle.net/20.500.14094/D1003595>

※ 当コンテンツは神戸大学の学術成果です。無断複製・不正使用等を禁じます。著作権法で認められている範囲内で、適切にご利用ください。



## The First Japanese Familial Sotos Syndrome with a Novel Mutation of the *NSDI* Gene

SATOSHI TEI, SYUICHI TSUNEISHI, and MASAFUMI MATSUO

*Division of Pediatrics, Department of Development and Aging,  
Kobe University Graduate School of Medicine, Kobe, Japan*

Received 10 January 2006 /Accepted 18 January 2006

**Key words:** Sotos syndrome, *NSDI*, familial cases, phenotype

**Sotos syndrome is caused by the haploinsufficiency of the *NSDI* gene located in 5q35. More than 70% of the Japanese cases carry microdeletions encompassing of this gene, while point mutations are common in Caucasians. Only 15 familial cases of Sotos syndrome have been reported and all cases shown to have not microdeletions but point mutations. We identified the first Japanese familial case (mother and 3 children). They carry the same mutation at splice donor site of intron 13 (IVS13+1G>A), which results in the *in-frame* skipping of exon 13. This is also the first familial case caused by the mutation of the splice donor site. Each member of this family showed variable phenotypes and mental development. The present report will contribute to further understanding of genotype-phenotype correlation in Sotos syndrome.**

Sotos syndrome (OMIM 117550) is characterized by pre- and post-natal overgrowth, advanced bone age, distinctive craniofacial features (macrocephaly, frontal bossing with high hairline, high palate, prominent jaw), and variable degrees of mental retardation (7,17). Additional features include neonatal hypotonia, neonatal jaundice, seizures, congenital heart defects, scoliosis, brain anomalies, and malignant lesions (1,6,7,10).

Recent reports showed that Sotos syndrome is caused by haploinsufficiency of the gene for *NSDI* (the nuclear-receptor-binding SET-domain-containing protein 1) at 5q35 (13). Up to 90% of individuals with Sotos syndrome have a demonstrable mutation or deletion of *NSDI*. Chromosomal microdeletions encompassing the entire *NSDI* gene are the major cause of Japanese patients with Sotos syndrome, whereas point mutations have been identified in the great majority of European patients (8,14,16,19,20). To our knowledge, more than 250 cases with mutation of *NSDI* have been reported and identified mutations scattered over the coding region without any hotspots (19).

Genotype-phenotype correlation is not fully elucidated in Sotos syndrome. Some studies have suggested that chromosomal microdeletions are associated with less prominent overgrowth and with severer mental retardation than intragenic mutations (8,15,19). Most cases of Sotos syndrome are sporadic, while several familial cases have been described, most of which exhibit autosomal dominant manner of inheritance (21). Only 15 familial cases with proven intragenic mutations in *NSDI* have been identified. Among them only 4 familial cases (two of German, and one each of Turkish, Finnish) have been described concisely with clinical phenotypes (3,11,20).

In this report, we describe clinical features and molecular genetic findings in the first Japanese familial Sotos syndrome. The mother and her 3 children carry the same mutation resulting in the skipping of exon 13, though each case showed somewhat different

phenotypes and severity. The difference especially in mentality observed in our familial case of Sotos syndrome was an interesting finding.

## CLINICAL PHENOTYPES

### **Patient II-1 (first son)**

The boy was the first child of non-consanguineous parents of Japanese origin. He was born as large for-date (Table 1), and he had fairly large hands, feet, and ears. He showed also frontal bossing, small jaw, and high palate (Fig. 1A). He showed hypotonia and severe feeding difficulties with frequent vomiting until the age of 3 months. Later, he showed excessive growth, and his psychomotor development delayed in terms of head control at the age of 7 months, and walking alone at 21 months. He spoke no words but understood several simple words. At the age of 22 months, he died due to Reye's syndrome following viral enterocolitis. Pathological findings of the liver tissue collected by needle biopsy showed characteristic fatty degeneration compatible with Reye's syndrome.

### **Patient II-2 (second son)**

The second son was born as appropriate for-date (Table 1), and his hands and feet were mildly large, and he had long face, prominent forehead with high hairline, and small pointed chin (Fig. 1B). The weight gain was poor until 4 months of his age because of frequent vomiting after feeding. He held up his head at 5 months, walked alone at 17 months, and spoke a first word at 18 months. His hands at 5 year 8 months showed advanced bone age corresponding to 7 year 11 months. At 7 years 9 months, his head circumference (HC) was 56.0 cm (+3.2SD). He attends a regular primary school with a full IQ value of 70 (WISC-III).

### **Patient II-3 (daughter)**

The daughter was born as severe large for-date (Table 1), and had a large head, frontal bossing with high hairline, large low set ear, small chin, large hands and feet (Fig. 1C). At the age of one month, she underwent on balloon dilation for congenital pulmonary stenosis. She held up her head at 4 months, and walked alone at 12 months. She spoke a first word at 12 months, and phrases at 2.5 years. Bone age of her hands at 2 year 2 months was advanced for a year. Development test (New-K style for the Japanese) performed at 3 year 4 months was within normal limit with a full DQ value of 85.

### **Patient I-2 (mother)**

The mother was 37 years old with height of 164.7 cm (+1.2SD), weight of 96.5 kg (+5.4SD), and HC of 58.4 cm (+2.7SD). She had a fairly large head with slightly prominent forehead, and big hands and feet. The chin was small for her large face (Fig 1D). She was born as the second child of the healthy parents. Her elder sister appeared normal. She was born as appropriate for-date with HC of 35.5 cm (+1.8SD). In neonatal period, she received phototherapy for several days against severe jaundice. She rolled over at the age of 7 months, and walked alone at 18 months. She was however a good runner in her childhood. No intelligence test was performed, but she graduated from a regular senior high school with lower achievement. At present she is a homemaker and nursing two kids.

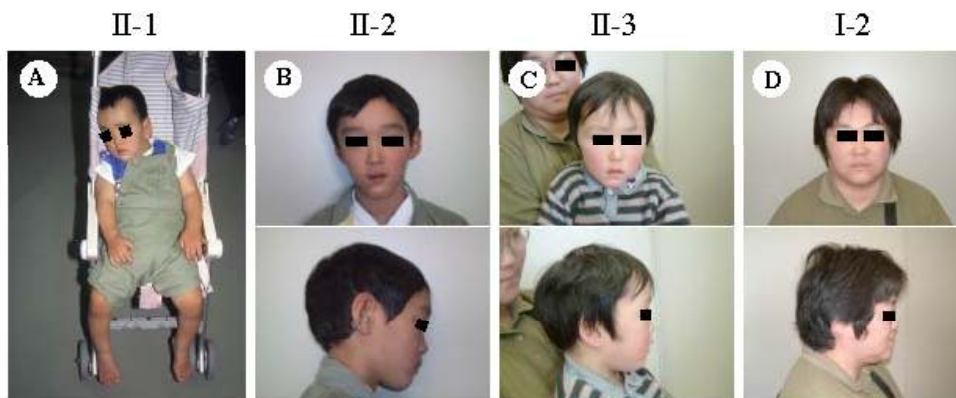
In this family, there were some obvious differences in the phenotypes of Sotos syndrome (Table 1), especially in the severity of mental deficit between male and female gender.

# FAMILIAL SOTOS SYNDROME

**Table 1** Clinical features of the members in the Japanese familial Sotos syndrome

patient	II-1 (first son)	II-2 (second son)	II-3 (daughter)	I-2 (mother)
sex	male	male	female	female
age	22 months	7 years	3 years	36 years
gestation(weeks)	38	38	38	40
birth weight (g)	3,500 (+1.8SD)	3,440 (+0.6SD)	4,366 (+3.6SD)	2,950 (-0.8SD)
birth length (cm)	53.0 (+1.8SD)	51.0 (+1.0SD)	55.5 (+3.1SD)	50.0 (+0.4SD)
HC at birth (cm)	38.0 (+2.9SD)	36.0 (+1.7SD)	38.0 (+3.7SD)	35.5 (+1.8SD)
<b>major criteria</b>				
over growth in childhood	++	++	++	++
advanced bone age	N.A.	+	+	N.A.
macrocephaly	++	++	++	++
delayed motor development	++	+	-	-
mental retardation	++(N.A.)	+(IQ 70)	-(DQ 85)	+(N.A.)
<b>facial characteristics</b>				
frontal bossing	+	+	+	+
midfacial narrowing	-	-	-	-
palpebral fissures slanting downwards	-	-	-	-
small jaw	+	+	+	+
high palate	+	-	-	-
deep set nails	+	+	-	-
large ear	++	++	++	++
large hands and feet	++	++	++	++
<b>others</b>				
febrile seizure	+	++many times	-	-
hypotonia	+	-	-	-
neonatal hypoglycemia	-	-	-	-
neonatal feeding problems	+++till 5 months	+++till 5 months	-	-
neonatal jaundice	-	-	-	++severe
heart defect	-	-	+pulmonary stenosis	-
brain anomaly	+subependymal cysts	+subependymal cysts	-	-
osteoporosis	-	-	-	-
malignancy	-	-	-	-

N.A.= not assessed



**Fig. 1.** Facial features in a Japanese familial Sotos syndrome with *NSD1* mutation.

(A); patient II-1 at age 22 months, (B); patient II-2 at age 6 years 6 months, (C); patient II-3 at age 3 years 3 months, (D); patient I-2 at 37 years.

## METHODS

### FISH analysis

In order to identify microdeletions within the portion of 5q35, fluorescent *in situ* hybridization (FISH) analysis with the BAC clone RP1-118m12, which contains the *NSD1* gene, was employed (Mitsubishi Chemicals, Tokyo, Japan). The tel 5p probe was used as a control.

### **Analysis of genomic DNA**

After obtaining informed consent, peripheral blood was obtained from the proband and his family members, and DNA was extracted from lymphocytes using standard method. As the first son had already passed away, his DNA was extracted from his frozen liver tissue collected by needle biopsy. Each of 22 exons covering the entire coding region of the *NSDI* gene was amplified by the polymerase chain reaction (PCR) with the primer sets designed by Douglas et al. (8) and the product was directly sequenced.

### **Analysis of *NSDI* mRNA**

Total RNA extracted from peripheral lymphocytes or liver tissue (patient II-1) was treated with DNase I to avoid genomic DNA contamination. From pretreated RNA, cDNA was synthesized by reverse transcriptase (RT) with random primers. RT-PCR product with an appropriate set of primers were separated by gel extraction method, and sequenced directly on an automatic DNA sequencer as described previously (18). We found a mutation at the splice donor site of exon 13, so *NSDI* transcripts of the patients were analyzed using a forward primer on exon 11 (5'CCCAAGGAGACTGTTGAGGA3') and a reverse on exon 15 (5'GTGGCTTTTTGCCTGCTTTA3') in order to confirm the splicing abnormality.

## **RESULTS**

### **FISH analysis**

Since more than 70% of Japanese cases of Sotos syndrome carry microdeletions encompassing the *NSDI* gene located in 5q35, microdeletion was examined using FISH. However, FISH analysis performed on patient II-2 and II-3 showed normal two signals of both the probe RP1-118m12 and tel 5p (data not shown). No microdeletion was detected in patient II-2 and II-3.

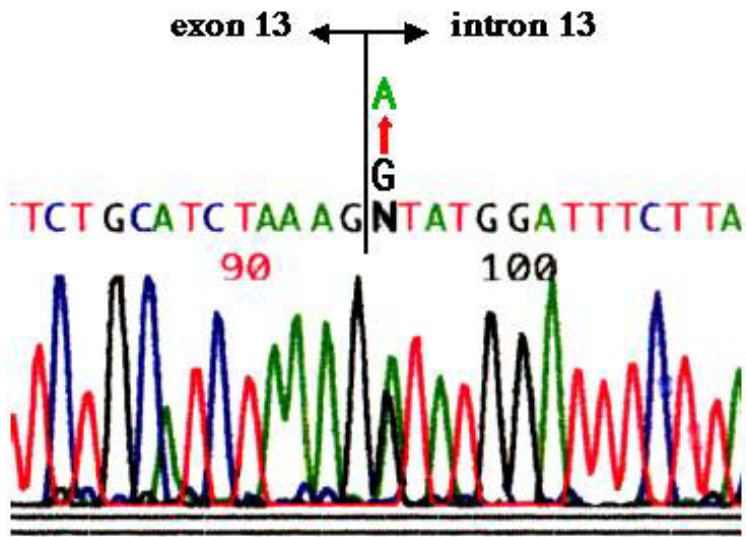
### **Analysis of genomic DNA and *NSDI* mRNA**

To find point mutations in the proband, genomic DNA from patient II-3 was examined for *NSDI* mutations. Although no mutations in coding region of every exon was identified, a hetero-signal of G and A at the first base in intron 13 was identified (Fig. 2). The nucleotide change was confirmed after subcloning sequencing. Therefore, patient II-3 was concluded to have a point mutation at the splice donor site (IVS13+1G>A) in one allele. Genomic DNA of other patients was analyzed for the specific mutation of IVS13+1G>A identified in patient II-3. We confirmed the identical mutation in the splice donor site in patient II-1, II-2 and I-2.

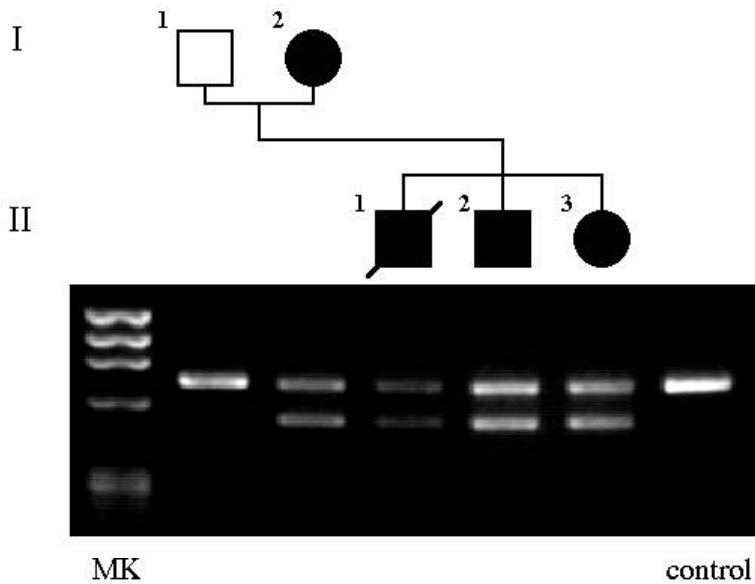
In order to determine abnormalities at the mRNA level, *NSDI* transcripts of the patients were analyzed by RT-PCR amplifying from exon 11 to exon 15. Two amplified fragments of different lengths were visualized from all the patients (Fig. 3). Sequencing of each amplified product by gel extraction method revealed that the longer band corresponded to normal splicing product encompassing exon 11-15, the shorter product lacked exon 13 (data not shown). Skipping of exon 13 (201 bp) induced by the mutation of the splice donor site of intron 13 was *in-frame* so that it is predicted to result in the smaller incomplete *NSDI* protein. The lacking part contains the plant homeo domain (PHD)-II.

In the unaffected husband (I-1), elder sister, and parents of patient I-2, DNA analysis showed normal sequences in the splice donor site of intron 13, and only the normal-sized product was detected on mRNA analysis (Fig. 3).

FAMILIAL SOTOS SYNDROME



**Fig. 2.** Partial sequence of the *NSDI* gene in splice donor site of exon 13. A hetero-signal of G (wild) and A (mutant) at the first base of intron 13, which reveals the mutation of G to A (IVS13+1G>A).



**Fig. 3.** Examination of the *NSDI* transcripts of the patients. PCR-amplified products obtained from the patients and healthy husband were separated by electrophoresis in a 2% agarose gel. Two fragments of different lengths were visualized from the patients. Only the normal-sized product was detected in the husband (I-1). The family pedigree is shown above the gel. MK: DNA size maker of HAE III-digested  $\phi$ X174 DNA.

## DISCUSSION

We identified a novel mutation involving the splice donor site in the *NSD1* gene (IVS13+1G>A) in a Japanese familial case of Sotos syndrome. This is the first case of Japanese familial Sotos syndrome. Including our case, only 16 familial cases with proven abnormalities in *NSD1* have been reported. These familial cases with Sotos syndrome do not agree with the hypothesis that *NSD1* mutations are associated with an underlying defect in fertility (8). Kurotaki et al. (14) speculated that microdeletion rather than *NSD1* point mutation might have a deleterious effect on fertility. In support of it, no microdeletions were identified in all familial cases (8 missense, 5 frameshift, 2 nonsense, 1 splice donor site, 1 deletion of 3 amino acids) (Table 2) (3,11,14,19,20). Familial cases tend to carry missense mutations more likely than non-familial cases (19). Severity of mental retardation may be also associated with rarity of familial cases. More than 70% of Japanese cases carry microdeletions so that familial cases of Sotos syndrome seem to be very rare in the Japanese race. In addition, this is the first report testing *NSD1* abnormality over three generations of the family. In the result of genomic DNA analysis, we confirmed that the mother (patient I-2) had a *de novo* mutation, and her three children (patient II-1, -2 and -3) carried the same mutation as an autosomal dominant mode in common with several familial cases already reported (3,11,14,20). It would be so rare among the familial Sotos syndrome that all three children were affected.

**Table 2** Summary of familial Sotos syndrome with *NSD1* aberrations.

nationality	patient	location	mutation	amino acids change	affected domain	reference
Finnish	father, son	exon 2	8964delC	frameshift	-	Koglund et al (2003)
	mother, 2 daughters	exon 5	2333T>G	L778X	-	Tatton-Brown (2005)
Isvaelike	mother, son	exon 5	2386-2389del	frameshift	-	Kurotaki et al (2003)
	mother, daughter	exon 6	3882delT	frameshift	-	Tatton-Brown (2005)
	mother, son	exon 10	4417C>T	R1473X	-	Tatton-Brown (2005)
	mother, son	exon 13	4779-81delTTTinsATTTC	frameshift	PHD II	Tatton-Brown (2005)
	mother, daughter	exon 13	4855T>C	C 1619R	PHD II	Tatton-Brown (2005)
	father, 3 sons	exon 14	4987C>T	R1663C	PHD III	Tatton-Brown (2005)
German	mother, daughter	exon 16	5375G>T	G1792V	PWWP II	Tatton-Brown (2005)
	father, 2 daughters	exon 18	5737A>G	N1913D	SAC	Boer et al (2004)
German	mother, daughter, son	exon 21	6241T>G	L2081V	C/H rich region	Boer et al (2004)
		exon 23	7576C>T	P2526S	-	
		exon 22	6291delG	frameshift	-	Tatton-Brown (2005)
Turkish	father, son	exon 22	6370T>C	C 2124R	PHD V	Tatton-Brown (2005)
	mother, daughter, son	exon 23	6532delTGC CCC AGC	2178-2180delCPS	PHD V	Turkmen et al (2003)
Japanese	mother, 2 sons, daughter	intron 13	IVS13+1G>A	skip exon13	PHD II	our case

Thirteen mutations involving splice sites have been reported (3,5,8,13,19,20). In only four of them, amino acids changes were determined. If resulting in the indicated exon skipping due to a mutation in splice site in all cases, frameshift should occur in 10 individuals. Three exceptions, resulted in skipping of exon 18 or 19, were *in-frame*, but lacked a part of the functional SET domain. In our case, skipping of exon 13 was also *in-frame*, and PHD-II domain was included in the lacking part. Phenotypes of all patients with splice site mutation were typical Sotos syndrome. These summaries lead us to conjecture that *in-frame* mutations are not necessarily associated with milder clinical features. We should accumulate enough number of cases to compare the phenotypes of those who carry *in-frame* and *out-of-frame* exon skipping mutations.

It is of interest that some obvious differences of clinical features were seen in our familial case. For example, delayed psychomotor development, neonatal feeding problems, periventricular subependymal cysts (9) and febrile seizures were seen in patient II-1 and II-2

## FAMILIAL SOTOS SYNDROME

but not II-3 and I-2, congenital heart defect (pulmonary stenosis) only in patient II-3, and severe neonatal jaundice in patient I-2 (Table 1). Similarly, distinct degrees of overgrowth, advanced bone age, developmental delay were seen in each of two German families (3). There have been few reports showing phenotype description in familial cases.

Tatton-Brown et al. (19) compared the phenotypes of Sotos syndrome cases carrying the identical mutation occurred independently in 2 to 5 unrelated individuals. There were some variations in phenotypes, especially in mental deficit, congenital heart defect, and seizures. For example, an individual with 2386delGAAA mutation identified in 3 unrelated patients (5,19) had congenital heart defect and brain ventriculomegaly, while the other two had only scoliosis. These evidences suggest that not only *NSDI* gene but other factors such as environment or undiscovered genes may influence phenotypes of Sotos syndrome. Indeed, Baujat et al. (2) found 11p15 anomalies in two cases of typical Sotos syndrome patients who did not carry any *NSDI* aberration. Brown et al. (4) reported a pair of concordant monozygotic twins and one of them met the clinical criteria for Sotos syndrome, while the other seemed quite normal. A postconceptual somatic mutation or an epigenetic change only could explain the discordance observed in that twin.

Phenotype differences observed dominant in our male cases (patient II-1 and II-2), especially mental retardation, seizures, neonatal feeding problems, and periventricular subependymal cysts were all associated with central nervous system (CNS). We have few studies concentrating on the effects of gender on the phenotypes of this syndrome. Cole et al. (7) reported that the tendency of normalization of overgrowth (height and weight) was more pronounced in females and was probably related to their early puberty. From our case it is an interesting finding that there may exist some difference in phenotypes of Sotos syndrome related with gender.

To elucidate the factors concerning phenotype variations in Sotos syndrome, it is a crucial issue to clarify the expression pattern of *NSDI* in each organ. Kurotaki et al. (12) reported *NSDI* is expressed in the fetal/adult brain, kidney, skeletal muscle, spleen, and the thymus, and faintly in the lung. *NSDI* transcripts of patient II-1 were to be extracted from his liver tissue collected by needle biopsy. This provides new evidence that a certain level of expression of *NSDI* exists in the liver.

In conclusion, we identified the first Japanese familial case carrying the same mutation involving splice donor site (IVS13+1G>A), which results in the *in-frame* skipping of exon 13. Each case shows variable phenotypes and severity, which might be partly related with gender. The present family case will contribute to understand genotype-phenotype correlation in Sotos syndrome.

### REFERENCES

1. Allanson, J.E., Cole, T.R. 1996. Sotos syndrome: evolution of facial phenotype subjective and objective assessment. *Am. J. Med. Genet.* **65**:13-20.
2. Baujat, G., Rio, M., Rossignol, S., Sanlaville, D., Lyonnet, S., Le Merrer, M., Munnich, A., Gicquel, C., Cormier-Daire, V., Colleaux, L. 2004. Paradoxical *NSDI* mutations in Beckwith-Wiedemann syndrome and 11p15 anomalies in Sotos syndrome. *Am. J. Hum. Genet.* **74**:715-720.
3. de Boer, L., Kant, S.G., Karperien, M., van Beers, L., Tjon, J., Vink, G.R., et al. Genotype-phenotype correlation in patients suspected of having Sotos syndrome. *Horm. Res.* **62**:197-207.
4. Brown, W.T., Wisniewski, K.E., Sudhalter, V., Keogh, M., Tsiouris, J., Mizejeski, C., Schaefer, G.B. 1998. Identical twins discordant for Sotos syndrome. *Am. J. Med. Genet.* **79**:329-333.



5. **Cecconi, M., Forzano, F., Milani, D., Cavani, S., Baldo, C., Selicorni, A., et al.** 2005. Mutation analysis of the NSD1 gene in a group of 59 patients with congenital overgrowth. *Am. J. Med. Genet.* **134**:247-253.
6. **Cohen, M.M.Jr.** 1999. Tumors and nontumors in Sotos syndrome. *Am. J. Med. Genet.* **84**:173-175.
7. **Cole, T.R., Hughes, H.E.** 1994. Sotos syndrome: a study of the diagnostic criteria and natural history. *J. Med. Genet.* **31**:20-32.
8. **Douglas, J., Hanks, S., Temple, I.K., Davies, S., Murray, A., Upadhyaya, M., Tomkins, S., Hughes, H.E., Cole, T.R.P., Rahman, N.** 2003. NSD1 mutations are the major cause of Sotos syndrome and occur in some cases of Weaver syndrome but are rare in other overgrowth phenotypes. *Am. J. Hum. Genet.* **72**:132-143.
9. **Herini, E.S., Tsuneishi, S., Takada, S., Sunartini, Nakamura, H.** 2003. Clinical features of infants with subependymal germinolysis and choroid plexus cysts. *Pediat. Int.* **45**:692-696.
10. **Hersh, J.H., Cole, T.R., Bloom, A.S., Bertolone, S.J., Hughes, H.E.** 1992. Risk of malignancy in Sotos syndrome. *J. Pediatr.* **120**:572-574.
11. **Hoglund, P., Kurotaki, N., Kytola, S., Miyake, N., Somer, M., Matsumoto, N.** 2003. Familial Sotos syndrome is caused by a novel 1 bp deletion of the NSD1 gene. *J. Med. Genet.* **40**:51-54.
12. **Kurotaki, N., Harada, N., Yoshiura, K., Sugano, S., Niikawa, N., Matsumoto, N.** 2001. Molecular characterization of NSD1, a human homologue of the mouse *Nsd1* gene. *Gene* **279**:197-204.
13. **Kurotaki, N., Imaizumi, K., Harada, N., Masuno, M., Kondoh, T., Nagai, T., et al.** 2002. Haploinsufficiency of NSD1 causes Sotos syndrome. *Nat. Genet.* **30**:365-366.
14. **Kurotaki, N., Harada, N., Shimokawa, O., Miyake, N., Kawame, H., Uetake, K., et al.** 2003. Fifty microdeletions among 112 cases of Sotos syndrome: low copy repeats possibly mediate the common deletion. *Hum. Mutat.* **22**:378-387.
15. **Nagai, T., Matsumoto, N., Kurotaki, N., Harada, N., Niikawa, N., Ogata, T., et al.** 2003. Sotos syndrome and haploinsufficiency of NSD1: clinical features of intragenic mutations and submicroscopic deletions. *J. Med. Genet.* **40**:285-289.
16. **Rio, M., Clech, L., Amiel, J., Faivre, L., Lyonnet, S., Le Merrer, M., et al.** 2003. Spectrum of NSD1 mutations in Sotos and Weaver syndromes. *J. Med. Genet.* **40**:436-440.
17. **Sotos, J.F., Dodge, P.R., Muirhead, D., Crawford, J.D., Talbot, N.B.** 1964. Cerebral gigantism in childhood. A syndrome of excessively rapid growth and acromegalic features and a nonprogressive neurologic disorder. *N. Engl. J. Med.* **271**:109-116.
18. **Surono, A., Takeshima, Y., Wibawa, T., Ikezawa, M., Nonaka, I., Matsuo, M.** 1999. Circular dystrophin RNAs consisting of exons that were skipped by alternative splicing. *Hum. Mol. Genet.* **8**:493-500.
19. **Tatton-Brown, K., Douglas, J., Coleman, K., Baujat, G., Cole, T.R.P., Das, S., et al.** 2005. Genotype-phenotype association in Sotos syndrome: An analysis of 266 individuals with *NSD1* aberrations. *Am. J. Hum. Genet.* **77**:193-204.
20. **Turkmen, S., Gillessen-Kaesbach, G., Meinecke, P., Albrecht, B., Neumann, L.M., Hesse, V., et al.** 2003. Mutations in NSD1 are responsible for Sotos syndrome, but are not a frequent finding in other overgrowth phenotypes. *Eur. J. Hum. Genet.* **11**:858-865.
21. **Winship, I.M.** 1985. Sotos syndrome - autosomal dominant inheritance substantiated. *Clin. Genet.* **28**:243-246.