



Value of Convex-Type ST-Segment Elevation and Abnormal Q Waves for Electrocardiographic-Based Identification of Left Ventricular Remodeling in Hypertrophic Cardiomyopathy

Furuki, Maky

(Degree)

博士 (医学)

(Date of Degree)

2009-03-25

(Date of Publication)

2011-12-08

(Resource Type)

doctoral thesis

(Report Number)

甲4665

(URL)

<https://hdl.handle.net/20.500.14094/D1004665>

※ 当コンテンツは神戸大学の学術成果です。無断複製・不正使用等を禁じます。著作権法で認められている範囲内で、適切にご利用ください。



Value of Convex-Type ST-Segment Elevation and Abnormal Q Waves for Electrocardiographic-Based Identification of Left Ventricular Remodeling in Hypertrophic Cardiomyopathy

MAKY FURUKI, HIROYA KAWAI*, TETSUARI ONISHI,
and KEN-ICHI HIRATA.

*Division of Cardiovascular Medicine, Department of Internal Medicine,
Kobe University Graduate School of Medicine, Kobe, Japan*

Received 8 January 2009/ Accepted 14 January 2009

Key Words: Hypertrophic cardiomyopathy, convex ST-segment elevation, abnormal Q waves, LV dysfunction, ventricular remodeling.

Several studies have demonstrated that the natural course of hypertrophic cardiomyopathy can be variable, often unpredictable with high morbidity and mortality. Therefore, screening for potential cases and periodical evaluation of affected patients is compelling. The purpose of our study is to assess a relationship of the electrocardiographic finding of ST-segment elevation and/or abnormal Q waves with the development of left ventricular enlargement and wall motion abnormalities in the echocardiography and to propose these findings as a sign of left ventricular remodeling in patients with hypertrophic cardiomyopathy. We enrolled 110 patients with hypertrophic cardiomyopathy. Standard echocardiography and 12-lead electrocardiograms were analyzed. After initial evaluation, follow up was conducted with a mean interval of 20.3 months. In the electrocardiograms we found ST-segment elevation in 43.6% and abnormal Q waves in 18.1%; and left ventricular enlargement in 12.7% and wall motion abnormalities in 21.8% in the echocardiograms. Three different patterns of ST-segment elevation were acknowledged: concave (13.6 %), straight (16.3 %) and convex (13.6%). There was a close relationship between the electrocardiographic finding of convex ST-segment elevation and/or abnormal Q waves and the occurrence of left ventricular enlargement and/or wall motion abnormalities in the echocardiograms with a sensitivity of 62% and a specificity of 85%. However, the straight and concave-type ST-segment elevation showed a less significant relationship with the echocardiographic findings. This study suggested that the electrocardiographic finding of convex ST-segment elevation and abnormal Q waves could be valuable for detection of disease progression in patients with hypertrophic cardiomyopathy.

Hypertrophic cardiomyopathy (HCM) is a primary cardiac disorder, relatively common and determined by a variety of mutations encoding contractile proteins of the cardiac sarcomere. This genetic diversity is related with a heterogeneous and complex clinical expression. For example, there is often left ventricular (LV) hypertrophy in the absence of ventricular dilatation, but there are also cases when the LV hypertrophy is not so evident. Furthermore, HCM may progress from a nondilated state with normal systolic function to a

CONVEX STE AND ABNORMAL Q IN PROGRESSIVE HCM

dilated form with systolic dysfunction and failure (25,26). The risk for heart failure or sudden cardiac death increases as long as the disease progresses (16). Therefore, screening for potential cases and periodical evaluation of patients with HCM is compelling.(4) In a general basis, screening, evaluation and follow up of patients with HCM is supported by laboratory investigation. The transthoracic echocardiography in HCM is evidently the most important form of laboratory investigation, and its diagnostic and screening accuracy has been very helpful in the need to avoid the use of invasive tools (25,26,41). Nevertheless, the high cost of the echocardiography in developing countries still exerts an important influence in the availability and cost-effectiveness of the mentioned procedure.

In this context, the electrocardiography (ECG) is a noninvasive, considerably non-expensive, accessible and also reliable tool for screening and evaluation of patients with HCM (19,20,27). Previous studies demonstrated that the ECGs in patients with HCM have a high prevalence of abnormalities, particularly if the patients are symptomatic (19,20,26,41). There are increased lead voltage, alterations in the ST-segments and T waves including deep T-wave inversion (giant negative T), pathologic deep and wide Q waves, and conduction abnormalities of different kinds (27). Still, there are few studies regarding to the ECG findings of disease progression.

Therefore, the purpose of our study is to demonstrate a relationship between the electrocardiographic findings of ST-segment elevation and/or abnormal Q waves and the development of LV enlargement and/or wall motion abnormalities (WMA) in the echocardiography, and to propose the presence of these electrocardiographic findings as a sign of LV remodeling in patients with HCM (13,22).

MATERIALS AND METHODS

Patient Population

A retrospective cohort design was used. A total number of 123 patients with HCM in different clinical stages of the disease were included. All patients commuted periodically to Kobe University Hospital from 2001 to 2007. Initially, all patients underwent a clinical examination with a complete history and physical examination. Subsequently, a standard 12-lead ECG was acquired, and in the presence of suspicious abnormalities transthoracic echocardiography was performed. The diagnosis of HCM was defined by a hypertrophied, nondilated LV in the absence of another systemic or cardiac disease that is capable to produce the magnitude of hypertrophy evident (e.g. systemic hypertension, aortic valve stenosis) (25,26). Patients with advanced conduction system disease, intrinsic valve disease or a history of ischemic heart disease were excluded. Therefore, the final population consisted of 110 patients (age 66.6 ± 12.3 years; range: 18-90 years; 73 males and 37 females).

A follow up evaluation was performed with a mean interval of 20.3 months after the initial evaluation (range: 4-50 months). Respective echocardiographic and electrocardiographic examinations were conducted.

Echocardiography

The echocardiographic studies were performed using several machines including SSH 770A (Toshiba Medical Systems, Tokyo, Japan), Vingmed System Five/Vivid-7 (General Electric-Vingmed, Milwaukee, WI, USA), and Sonos 5500 (Philips Medical Systems, Andover, MA, USA). All patients were examined in the left lateral supine position. An M-mode tracing obtained just below the mitral valve leaflet was derived from the parasternal short-axis view. We measured LV end-diastolic (LVDd) and end-systolic (LVDs) diameters

and calculated fractional shortening. LV enlargement was considered when LVDd > 50 mm. LV end-diastolic and end-systolic volumes were derived from apical 2- and 4-chamber views and LV ejection fraction (EF) was calculated using biplane modified Simpson's rule. An EF < 50% was considered as LV systolic dysfunction. Two-dimensional evaluation of ventricular wall motion was performed from all views. LV wall thickness was measured in 4 segments of the anterior and posterior septum, and posterior and lateral free walls at the level of papillary muscle from parasternal short and long axis views and apical views. An LV maximum wall thickness > 13 mm was considered as LV hypertrophy (28,30). From the long axis view, we searched for the existence of systolic anterior motion of mitral valve (SAM). Subsequently, color flow Doppler mapping was displayed to determine evidence of flow turbulence in LV outflow tract (LVOT) or mid-ventricle. Continuous wave Doppler analysis was performed to determine and measure pressure gradients in the LVOT and mid-ventricle.

Electrocardiography

Standard 12-lead ECG reports were retrieved from medical records for further analysis. The criteria for abnormal ECG findings was defined based on previous studies in HCM as follows: abnormal Q wave \geq 25% of the R wave in depth or \geq 0.3 mV in depth and/or > 0.04 s in duration in at least 2 contiguous leads except aVR, evidence of high voltage in the precordial leads, ST-segment depression: upsloping type > 0.1 mV at 0.08 s after the J point, or downsloping type > 0.05 mV, ST-segment elevation > 0.2 mV and T-wave inversion > 0.1 mV except aVR and V1, V2 (5,19,34,42).

Furthermore, ST-segment elevation was classified into three types according to the morphology of the ST elevation after the J point on any precordial derivation (Fig. 1): concave type, ST-T segment rises with downward convexity; straight type, ST-T segment rises obliquely like an inclined plane; and convex type, ST-T segment rises with an upward convexity (15,21).

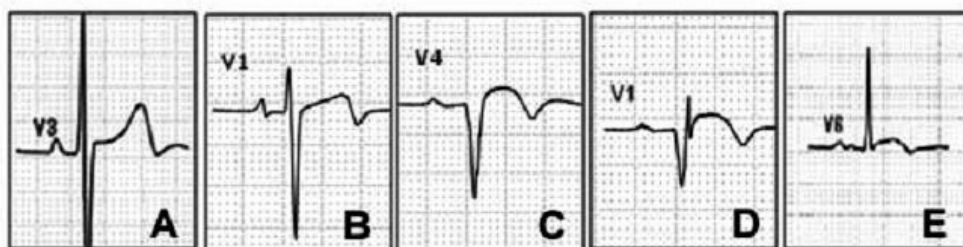


Figure 1 Three different types of ST- segment elevation in the ECG.
A = concave-type; B = straight-type; C,D & E= convex-type

Statistical Analysis

Statistical analysis was performed using SPSS statistical software (version 15.0; SPSS Inc., Chicago, Illinois) and Microsoft Excel 2000 with an add-in software Statcel2 (OMS Inc., Saitama, Japan). Analysis of the receiver-operating characteristic (ROC) curves was used to assess the sensitivity and specificity of the electrocardiographic findings for the detection of disease progression for HCM by echocardiography. Chi-square tests were used to compare between two variables.

RESULTS

Echocardiographic findings

Among 110 patients with HCM, we found no signs of obstruction in 64 (58.1%) patients (Table I). However, in 46 (41.78%) patients we found obstructive HCM as follows: 14 (12.7%) displayed LVOT obstruction with SAM and subaortic flow gradients, and 30 (27.2%) presented mid ventricular obstruction (MVO) with intracavitary gradients, and 2 (1.8%) presented simultaneous double-site dynamic obstruction in LVOT and mid-ventricle respectively.

From 110 patients, we found asymmetric septal hypertrophy (ASH) in 91(82.7%). Thirty eight (34.5%) showed obstructive HCM: 14 (12.7%) patients depicted LVOT obstruction and 22 (20%) showed MVO. Similarly, the 2 uncommon cases of double-site obstruction corresponded likewise to the group of ASH. Nineteen (17.2%) patients presented apical HCM (APH). Eleven (10%) of these patients did not show signs of obstruction but 8 (7.2%) displayed MVO.

Table I. Echocardiographic Findings of Patients with ASH or APH

	Total		ASH		APH	
	Number	%	Number	%	Number	%
Non obstructive HCM	64	58.1	53	48.1	11	10.0
Obstructive HCM	46	41.8	38	34.5	8	7.2
LVOTO	14	12.7	14	12.7	0	0.0
MVO	30	27.2	22	20.0	8	7.2
LVOTO+MVO	2	1.8	2	1.8	0	0.0
WMA	24	21.8	19	17.2	5	4.5
Global WMA	13	11.8	11	10.0	2	1.8
Focal WMA	11	10.0	8	7.2	3	2.7
Apical aneurysm	6	5.4	5	4.5	1	0.9
LV enlargement	14	12.7	10	8.0	4	3.6
EF < 50%	9	8.1	8	7.2	1	0.9

ASH, asymmetrical septal hypertrophy; APH, apical hypertrophic cardiomyopathy; HCM, hypertrophic cardiomyopathy; LVOTO, left ventricular outflow tract obstruction; MVO, mid-ventricular obstruction; WMA, wall motion abnormalities; LV, left ventricular; EF, ejection fraction

Twenty four (21.8%) patients presented WMA: 13 (11.8%) showed global WMA, from which 11 (10.0%) corresponded to the ASH group and 2 (1.8%) to the APH group. The rest 11 (10.0%) patients presented WMA confined to certain areas of the ventricle. This included 8 (7.2%) from the ASH group and 3 (2.7%) from the APH group. Six (5.4%) of these patients depicted an apical aneurysm formation, 5 (4.5%) were from the ASH group and 1 (0.9%) from the APH group. Five of the 6 patients with apical aneurysm presented also MVO.

Fourteen (12.7%) patients presented LV enlargement and 9 (8.1%) showed LV systolic dysfunction with an EF<50%. Ten (8.0%) patients that presented LV enlargement corresponded to the ASH group and 4 (3.6%) with APH ended in progressive LV enlargement. Eight (7.2%) patients from the ASH group and 1 (0.9%) with APH showed LV systolic dysfunction, respectively.

Electrocardiographic findings

In the electrocardiographic studies, 94 (85.4%) patients were in sinus rhythm (Table II). Fourteen (12.7%) patients showed atrial fibrillation and 2 (1.8%) developed atrial flutter.

Fifty three (48.1%) patients presented evidence of high voltage in the precordial leads. Abnormal Q waves were seen in 20 (18.1%) patients and ST segment elevation was evidenced in 48 (43.6 %). Three different patterns of ST-segment elevation were acknowledged: concave in 15 (13.6 %), straight in 18 (16.3 %) and convex in 15 (13.6 %) of the total population of 110 patients. ST-segment depression was found in 74 (67.2%) patients and negative T waves in 100 (90.9%).

Table II. Electrocardiographic Findings

	Number of	
	cases	%
Rhythm		
Sinus	94	85.4
AF	16	14.5
QRS complex		
High voltage	53	48.1
Abnormal Q waves	20	18.1
ST-segment		
ST elevation	48	43.6
Concave	15	13.6
Straight	18	16.3
Convex	15	13.6
ST depression	74	67.2
T wave		
Negative T	100	90.9

AF, atrial fibrillation or flutter.

Follow up evaluation of patients with HCM

A follow up evaluation of patients with HCM was performed with a mean interval of 20.3 months. During follow up periods, new WMA appeared in 11 patients and left ventricular diameter increased in 4 patients. Totally, in 15 patients, echocardiographic changes occurred.

Within these 15 patients, the initial evaluation revealed the convex-type of ST-segment elevation and/or abnormal Q waves in 8 patients. And the last evaluation showed those abnormalities in 12 patients.

CONVEX STE AND ABNORMAL Q IN PROGRESSIVE HCM

Diagnostic value of ECG findings for detection of disease progression of HCM

The sensitivity for WMA and/or LV enlargement in the convex-type of ST-segment elevation was higher compared with the concave and straight types (Fig. 2). The relation between the convex-type of ST-segment elevation and WMA or LV enlargement yielded a sensitivity of 42%, with a specificity of 95% and an accuracy of 83%. Abnormal Q waves compared with the occurrence of WMA and/or LV enlargement in the echocardiography yielded a sensitivity of 36% and a specificity of 89%. After follow up evaluation, the analysis of the relation between the convex-type of ST-segment elevation and WMA or LV enlargement yielded a sensitivity of 54%, with a specificity of 96% and an accuracy of 82%. Relation between abnormal Q waves and WMA and/or LV enlargement in the echocardiography yielded a sensitivity of 41% and a specificity of 93%.

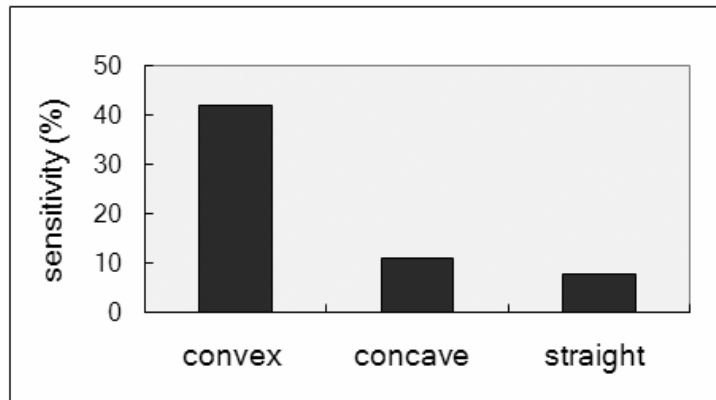


Figure 2 Comparison of sensitivity for identification of LV WMA and/or LV enlargement among 3 different patterns of ST- segment elevation.

Although the sensitivity of convex-type ST-segment elevation analyzed alone was low (42%), when combining convex-type ST-segment elevation and/or abnormal Q wave and compared again with WMA and/or LV enlargement, the specificity was 85% and the sensitivity increased to 62% (Table III). Furthermore, after follow up, the relation of combined convex-type ST-segment elevation and/or abnormal Q wave with WMA and/or LV enlargement yielded a sensitivity of 69% with a specificity of 88%.

Table III. Diagnostic Value of Convex type ST-segment Elevation and/or Abnormal Q waves for Identification of Left Ventricular Dysfunction

Criteria	Sensitivity (%)	Specificity (%)	PPV (%)	NPV (%)	Accuracy (%)
Convex ST elevation	42	95	73	84	83
Abnormal Q waves	36	89	50	82	77
Convex ST elevation and/or abnormal Q waves	62	85	55	87	76

PPV, positive predictive value; NPV, negative predictive value.

DISCUSSION

Several studies have been performed in order to assess thoroughly the natural course of HCM. It has been shown that the general features of the disease vary widely within the course of time (22,33).

LV systolic dysfunction in progressive HCM

In our study 12.7% of patients with HCM showed LV enlargement, 11.8% a global hypokinetic ventricle, and 8.1% systolic dysfunction with low EF. After follow up, another 4 patients developed LV enlargement and 11 WMA. Previous studies suggested that this group of patients is more likely to present greater myocyte death, extensive myocardial fibrosis, scarring and fiber disarray as the underlying mechanism for development of global WMA (6,38,40). Thaman et al. suggested that ventricular remodeling could be a part of the mechanism for development of systolic impairment, which in turns was caused by molecular and cellular changes such as ischemia, increased collagen synthesis and fibroblast proliferation (39). Furthermore, Ohba et al. demonstrated the presence of late gadolinium enhancement in MRI examination in 7 patients with dilated phase of HCM (31). The study showed the relationship between myocardial fibrosis and progressive change from HCM to dilated phase, as well as to irreversible cardiac dysfunction.

In our study, patients with apical HCM had an association with development of MVO. This in turns was followed by formation of a third chamber and WMA of different degrees confined to the apical segments. Even though, we also had evidence of patients with ASH who developed MVO in a substantial proportion. Additionally, a few cases of APH progressed to dilated phase of HCM resulting in a global WMA. To explain the mechanisms for development of focal and global WMA, there have been several postulates. For instance, an increased interstitial fibrosis leading to impaired myocardial contraction, disorganization of the myocytes leading to inefficient, nonuniform contraction or the mechanic determinant of cavity obstruction and the impairment of myocardial perfusion (2,35). Ishiwata et al. followed up 162 patients with HCM for an average period of 13.3 years (14). From this cohort, 16 patients gradually developed new different forms of LV WMA and were divided into 2 different groups: 11 presented apical segmental dysfunction with midzone obstruction, and the remaining 5 showed generalized hypokinesis, as seen in dilated cardiomyopathy. The

CONVEX STE AND ABNORMAL Q IN PROGRESSIVE HCM

mechanisms of WMA were considered different for each group: apical WMA was considered to reflect regional ischemia caused by intracavitary obstruction, whereas myocardial fibrosis was suggested as the underlying mechanism of progression towards global myocardial dysfunction and dilated cardiomyopathy-like features (7,10,11).

ST-segment changes in HCM

In patients with HCM, depolarization and repolarization abnormalities are common (29). It has been documented that changes in QRS-segment and ST-T segment in resting conditions are developed frequently in patients with HCM and angiographically normal coronary arteries (9,32). In this context, there are several studies suggesting that the possible underlying mechanisms for repolarization abnormalities in patients with HCM may be other than myocardial ischemia (3,9,29). Brady et al. presented a study regarding the causes of ST-segment abnormalities in patients with chest pain (3,4). LV hypertrophy was the most frequent cause (49%) followed by acute myocardial infarction (29%) and left bundle branch block, occurring at equal frequencies. Furthermore, Lahiri et al. performed an investigation of the mechanism for exercise-induced ST-segment elevation from a population of 215 patients with previous myocardial infarction (23). Their study concluded that exercise-induced ST segment elevation is probably reflecting abnormal LV wall motion in the majority of the patients, rather than reversible myocardial ischemia. Harada et al. presented a rare case of ASH which progressed to MVO with an apical aneurysm formation (12). The ECG showed ST-segment elevation with terminal T inversion and ambulatory ECG revealed nonsustained ventricular tachycardia. Given that the coronary angiograms showed no narrowing of the epicardial coronary arteries, compression of the aberrant intramural coronary arteries combined with mechanical distress or MVO were proposed to be the cause of the apical aneurysm formation (24).

In our study, patients with history of ischemic heart disease were not included. Nevertheless, ST-segment elevation was present in almost one-half of the total population. Half of the patients with WMA (21.8%) and LV enlargement (12.7%) presented ST-segment elevation. Hence, it appears that the gradual evolution of secondary changes such as myocardial fibrosis, scarring and stiffening could have interfered with the normal transmission of electrical forces through the ventricles and caused the repolarization abnormalities. Likewise, in the 30 patients with MVO, 5 presented apical aneurysm formation, and all of them presented ST-segment elevation and/or abnormal Q waves (Figs. 3 and 4).

Thus, patients with these ECG findings presented high intracavitary pressures and WMA of different degrees confined to the apical segments. This in turns could have acted as an underlying mechanism for the repolarization changes found in this group of patients from our study.

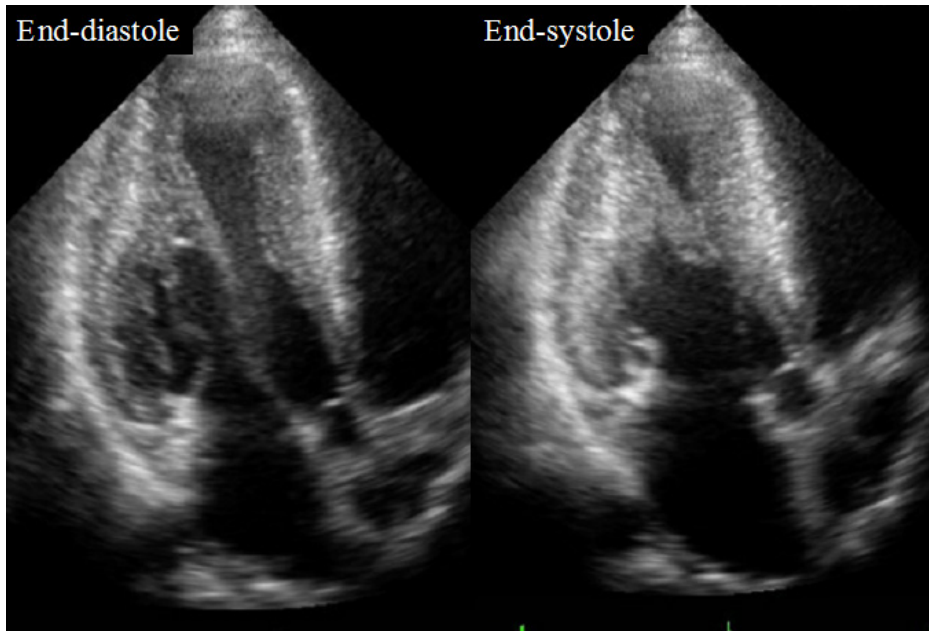


Figure 3 Echocardiography of a representative case
Apical long axis view at end-diastole and end-systole, showing apical akinesis and aneurysm formation.

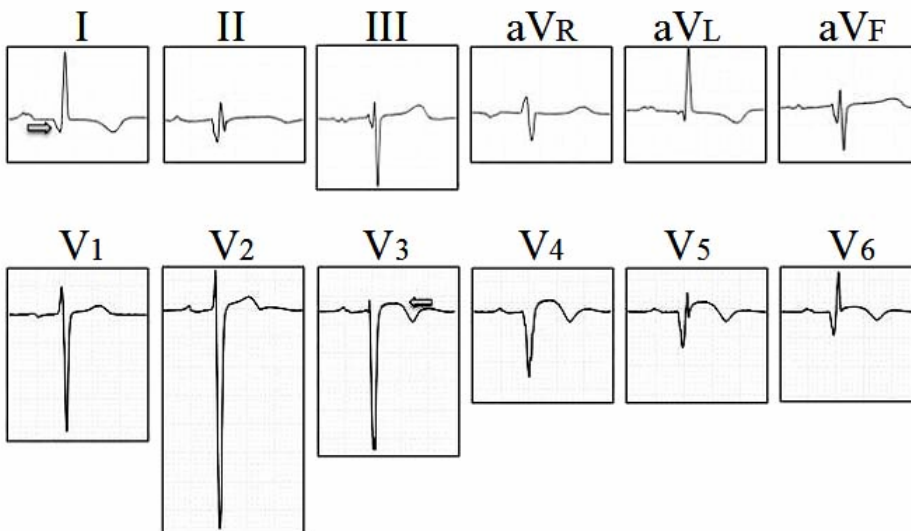


Figure 4
ECG of a representative case (the same patient of Figure 3).
Showing convex type of ST-segment elevation in V3-6 and deep, wide Q waves in II, aVF and V4-6 (arrows).

Three types of ST-segment patterns

Two studies regarding the shape of ST-segment elevation and its clinical implications were reported previously. Karadede et al. compared 3 groups of patients with different shapes of ST-segment elevation in order to assess the level of myocardial damage and predict further clinical course in the early period of acute myocardial infarction (15). Their

study concluded that the concave-type of ST-segment elevation on admission is associated with better LV function and more viable myocardium. Whereas the straight-and specially the convex-type are an ominous sign of higher grade of LV dysfunction, more severe necrotic myocardium, presence of late potentials and probably a worse prognosis. Similarly, Kosuge et al. examined the relation between the shape of ST-segment elevation and infarct size in a population of 77 patients, aiming to find a predictive value for myocardial viability and LV function after acute myocardial infarction (21).

In the present study, we found 3 different types of ST-segment elevation including straight, concave and convex in patients with HCM. To our knowledge, this is the first study suggesting a potential relationship between ST-segment shape and ventricular remodeling. The underlying mechanism for the convex-type of ST-segment elevation in patients with HCM has not been studied before. Our proposed mechanism is the combination of several factors. In patients with HCM, myocardial tissue changes such as cell injury and myocardial fibrosis could have impaired the normal transmission of membrane potentials, resulting in the abnormal configuration of ST-T segments. Mechanical distress (such as high intracavitary pressures and WMA) were associated with development of convex-type of ST-segment elevation in this study, reflecting a possible mechanical interference with the transmission of electrical forces through the ventricles. Furthermore, we found evidence that the convex-type of ST-segment elevation in the ECG was associated with higher grade of LV systolic dysfunction in the echocardiograms, whereas straight and concave-type showed a less significant relationship with the echocardiographic findings.

Thus, we hypothesize that the impairment of ventricular function due to ventricular remodeling, myocardial contractile dysfunction and less effective cardiac pumping function in patients with HCM may be traduced in a process which involves complex molecular and cellular mechanisms. It could result likewise, in disruption of the transmission of membrane potentials and the abnormal ST-T segment configuration.

During the follow up evaluation we realized that the electrocardiographic abnormalities appeared even before the echocardiographic changes in some patients. But the exact momentum and mechanism of the onset of these particular repolarization abnormalities still needs additional elucidation.

Pathological Q waves in HCM

Two main mechanisms were suggested in several studies for development of abnormal Q waves in patients with HCM: 1) loss of local electrical forces due to transmural myocardial fibrosis; or 2) altered direction of the resultant initial QRS vector due to increased electrical forces of disproportionate hypertrophy of the basal ventricular septum and/or basal LV free wall, unopposed by apical electrical forces (18). Sato et al., using magnetic resonance imaging (MRI) to evaluate the relationship between ECG features and the distribution of hypertrophy in patients with HCM, suggested that an exaggerated initial electrical activation and depolarization of ventricular septum could be the primary mechanism for abnormal Q waves (36). Similarly, Dumont et al. examined 108 patients with cardiac MRI to clarify the mechanism of ECG abnormalities encountered in HCM (8). Abnormal Q waves were acknowledged as the result of the inter-relation between upper anterior septal thickness with other regions of the ventricles. In patients with wider Q waves myocardial fibrosis was suggested to play a role.

Screening progressive HCM with combined electrocardiographic and echocardiographic findings

Progression of HCM is characterized by LV systolic dysfunction and dilatation (37,38). We found a close relationship between the ECG finding of convex ST-segment elevation and the occurrence of WMA and/or LV enlargement in the echocardiography. The sensitivity of convex-type ST-segment elevation when compared alone with WMA or LV enlargement was low (42%). Nevertheless, when combining convex-type ST-segment elevation and/or abnormal Q waves and compared again the specificity was 85% and the sensitivity increased to 62%. Hence, in this study the combination of abnormal Q waves and ST-segment elevation demonstrated to be better for detecting patients with progressive HCM and ventricular remodeling. In the other hand, patients that remained in time without apparent changes in wall compliance, cavity dimensions nor ventricular geometry, did not show a correlation with electrocardiographic features and deterioration of LV function.

Additionally, during the follow up evaluation we realized that from 15 patients that showed new echocardiographic changes (WMA and/or LV enlargement), 8 already presented electrocardiographic abnormalities (convex-type of ST-segment elevation and/or abnormal Q waves) in the initial evaluation. Hence, the electrocardiographic abnormalities may appear even before the echocardiographic changes and they could be considered as predictors of progressive HCM and ventricular remodeling.

Study Limitations

First, we understand that there are other non-invasive diagnostic methods that should be performed simultaneously with those included in this study.

Second, the majority of the patients from our study were outpatients; we were unable to perform histological analysis of myocardial tissue. We make a major remark in the need of simultaneous histological analysis of myocardial tissue to improve the validity of our study (17).

Third, patients with records of ischemic heart disease were deliberately excluded from this study. Nevertheless, a comparison among patients with angiographically documented coronary artery disease could yield new insights and further comparisons of the mechanisms underlying repolarization changes in patients with HCM (1).

Conclusion

In our study we found a significant correlation between the findings of ST-segment elevation and/or abnormal Q waves in the electrocardiogram and the apparition of WMA and/or LV enlargement in the echocardiogram. Additionally, convex-type of ST-segment elevation in the ECGs demonstrated to be related with higher grade of LV dysfunction in the echocardiogram. Thus, the electrocardiographic findings of convex ST-segment elevation and abnormal Q waves could be a sign of disease progression and ventricular remodeling in patients with HCM.

ACKNOWLEDGEMENTS

First, I will like to thank the Nippon Foundation and The Association of Nikkei and Japanese Abroad for providing me the life changing opportunity to study in a highly formative University in Japan. And second, I want to thank my family for being the source of motivation and for supporting me with love and understanding during all this time.

REFERENCES

1. Akakabe, Y., Kawasaki, T., Yamano, M., Miki, S., Kamitani, T., Kuribayashi, T., Matsubara, H., and Sugihara H. 2008. Septal Q wave as a marker of septal ischemia in hypertrophic cardiomyopathy. *Circ J*; **72**: 953 –957.
2. Betocchi, S., Hess, O.M., Losi, M.A., Nonogi, H., and Krayenbuehl H.P. 1993. Regional Left ventricular mechanics in hypertrophic cardiomyopathy. *Circulation*; **88**:2206-2214.
3. Brady, W.J., Perron, A.D., Martin, M.L., Beagle, Ch., and Aufderheide T.P. 2001. Cause of ST segment abnormality in ED chest pain patients. *Am J Emerg Med*; **19**(1):25-28.
4. Brady, W.J., Perron, A.D., Ullman, E.A., Syverud, S.A., Holstege, C., Riviello, R., and Ghammaghami C. 2002. Electrocardiographic ST segment elevation: A comparison of AMI and non-AMI ECG syndromes. *Am J Emerg Med*; **20**(7):609-612.
5. Charron, P., Dubourg, O., Desnos, M., Isnard, R., Hagege, A., Millaire, A., Carrier, L., Bonne, G., Tesson, F., Richard, P., Bouhour. J.B., Schwartz, K., and Komajda M. 1997. Diagnostic value of electrocardiography and echocardiography for familial hypertrophic cardiomyopathy in a genotyped adult population. *Circulation*; **96**:214-219.
6. Choudhury, L., Mahrholdt, H., Wagner, A., Choi, K.M., Elliott, M.D., Klocke, F.J., Bonow, R.O., Judd, R.M., and Kim R.J. 2002. Myocardial scarring in asymptomatic or mildly symptomatic patients with hypertrophic cardiomyopathy. *J Am Coll Cardiol*; **40**(12):2156-2164.
7. Dumont, C., Monserrat, L., Soler, R., Rodríguez, E., Fernández, X., Peteiro, J., Bouzas, B., Piñón, P., and Castro-Beiras A. 2007. Clinical significance of late gadolinium enhancement on cardiac magnetic resonance in patients with hypertrophic cardiomyopathy. *Rev Esp Cardiol.*; **60**(1):15-23.
8. Dumont, C.A., Monserrat, L., Soler, R., Rodriguez, E., Fernandez, X., Peteiro, J., Bouzas, A., Bouzas, B., and Castro-Beiras A. 2006. Interpretation of electrocardiographic abnormalities in hypertrophic cardiomyopathy with cardiac magnetic resonance. *Eur Heart J*; **27**:1725-1731.
9. Ha, J.W., Choi, B.W., Rim, S.J., Kang, S.M., Jang, Y., Chung, N., Shim, W.H., and Cho S.Y. 2005. Extensive subepicardial fibrosis in a patient with apical hypertrophic cardiomyopathy with persistent ST-segment elevation simulating acute myocardial infarction. *Circulation*; **112**:49-50.
10. Hansen, M., and Merchant N. 2007. MRI of hypertrophic cardiomyopathy: part I, MRI appearances. *Am. J. Roentgenol.*; **189**(6):1335-1343.
11. Hansen, M., and Merchant N. 2007. MRI of hypertrophic cardiomyopathy: part II, differential diagnosis, risk stratification, and posttreatment MRI appearances. *Am. J. Roentgenol.*; **189**(6):1344-1352.
12. Harada, K., Shimizu, T., Sugishita, Y., Yao, A., Suzuki, J., Takenaka, K., Hirata, Y., Nagai, R., and Takahashi T. 2001. Hypertrophic cardiomyopathy with midventricular obstruction and apical aneurysm. A case report. *Circ J*; **65**(10):915-919.
13. Harris, K.M., Spirito, P., Maron, M.S., Zenovich, A.G., Formisano, F., Lesseret, J.R., Mackey-Bojack, S., Manning, W.J., Udelson, J.E., and Maron B.J. 2006. Prevalence, clinical profile, and significance of left ventricular remodeling in the end-stage phase of hypertrophic cardiomyopathy. *Circulation*; **114**:216-225.
14. Ishiwata, S., Nishiyama, S., Nakanishi, S., and Seki A. 1993. Two types of left ventricular wall motion abnormalities with distinct clinical features in patients with hypertrophic cardiomyopathy. *Eur Heart J*; **14**:1629-639.

15. **Karadede, A., Aydinalp, O., Temamogullari, A.V., and Toprak N.** 2002. The relationship of ST segment elevation shape with preserved myocardium and signal-averaged electrocardiography in acute anterior myocardial infarction. *Heart Vessels*; **16**:146–153.
16. **Kitaoka, H., Kubo, T., Okawa, M., Hitomi, N., Furuno, T., and Doi Y.L.** 2006. Left ventricular remodeling of hypertrophic cardiomyopathy. Longitudinal observation in a rural community. *Circ J*; **70**: 1543–1549.
17. **Koda, M., Takemura, G., Okada, H., Kanoh, M., Maruyama, R., Esaki, M., Li1, Y., Miyata, S., Kanamori, H., Li1, L., Ogino, A., Kondo, T., Minatoguchi, S., Fujiwara, T. and Fujiwara H.** 2006. Nuclear hypertrophy reflects increased biosynthetic activities in myocytes of human hypertrophic hearts. *Circ J*; **70**: 710 –718.
18. **Koga, Y., Yamanaga, A., Hiyamuta, K., Ikeda, H., and Toshima H.** 2004. Mechanisms of abnormal Q waves in hypertrophic cardiomyopathy assessed by intracoronary electrocardiography. *J Cardiovasc Electr*; **15(12)**:1402-1407.
19. **Konno, T., Shimizu, M., Ino, H., Yamaguchi, M., Terai, H., Uchiyama, K., Ohe, K., Mabuchi, T., Tomoya, K., and Mabuchi H.** 2004. Diagnostic value of abnormal Q waves for identification of preclinical carriers of hypertrophic cardiomyopathy based on a molecular genetic diagnosis. *Eur Heart J*; **25**:246-251.
20. **Konno, T., Shimizu, M., Ino, H., Fujino, N., Hayashi, K., Uchiyama, K., Kaneda, T., Inoue, M., Masuda, E., and Mabuchi H.** 2005. Phenotypic differences between electrocardiographic and echocardiographic determination of hypertrophic cardiomyopathy in genetically affected subjects. *J Intern Med*; **258**:216-224.
21. **Kosuge, M., Kimura, K., Ishikawa, T., Kuji, N., Osamu, T., Sugiyama, M., and Ishii M.** 1999. Value of ST-segment elevation pattern in predicting infarct size and left ventricular function at discharge in patients with reperfused acute anterior myocardial infarction. *Am Heart J*; **137(3)**:522-527.
22. **Kubo, T., Kitaoka, H., Okawa, M., Matsumura, Y., Hitomi, N., Yamasaki, N., Takashi, F., Jun, T., Masanori, N., Akinori, K., and Yoshinori L.D.** 2005. Lifelong left ventricular remodeling of hypertrophic cardiomyopathy caused by a founder frameshift deletion mutation in the cardiac myosin-binding protein C gene among Japanese. *J Am Coll Cardiol*; **46**:1737-1743.
23. **Lahiri, A., Balasubramanian, V., Millar Craig, M.W., Crawley, J., and Raftery E.B.** 1980. Exercise-induced ST segment elevation: Electrocardiographic, angiographic, and scintigraphic evaluation. *Br Heart J*; **43**:582-588.
24. **Mantica, M., Della Bella, P., and Arena V.** 1997. Hypertrophic cardiomyopathy with apical aneurysm: a case of catheter and surgical therapy of sustained monomorphic ventricular tachycardia. *Heart*; **77**:481-483.
25. **Maron, B.J., Towbin, J.A., Thiene, G., Antzelevitch, Ch., Corrado, D., Arnett, D., Moss, A.J., Seidman, C.E., and Young J.B.** 2006. Contemporary definitions and classification of the cardiomyopathies: An American Heart Association scientific statement from the council on clinical cardiology, heart failure and transplantation committee; quality of care and outcomes research and functional genomics and translational biology interdisciplinary working groups; and council on epidemiology and prevention. *Circulation*; **113**:1807-1816.
26. **Maron B.J.** 2002. Hypertrophic cardiomyopathy: a systematic review. *JAMA*; **287**:1308-1320.
27. **Maron B.J.** 2001. The ECG as a diagnostic tool for HCM: Revisited. *A.N.E.*; **6(4)**:277-279.

28. **Maron, B.J., Piccininno, M., Casey, S.A., Bernabo, P., and Spirito P.** 2003. Relation of extreme left ventricular hypertrophy to age in hypertrophic cardiomyopathy. *Am J Cardiol*; **91**:626-628.
29. **Moore, R.B., Shapiro, L.M., and Gibson D.G.** 1984. Relation between electrocardiographic repolarization changes and mechanical events in left ventricular hypertrophy. *Br Heart J*; **52**: 516-523.
30. **Morita, H., Larson, M.G., Barr, S.C., Vasan, R.S., O'Donnell, C.J., Hirschhorn, J.N., Levy, D., Corey, D., Seidman, C.E., Seidman, J.G., and Benjamin E.J.** 2006. Single-gene mutations and increased left ventricular wall thickness in the community: The Framingham heart study. *Circulation*; **113**:2697-2705.
31. **Ohba, M., Hosokawa, R., Kambara, N., Tadamura, E., Mamede, M., Kubo, S., Yamamuro, M., Fujita, M., Kimura, T., Nohara, R., and Kita T.** 2007. Difference in myocardial flow reserve between patients with dilated cardiomyopathy and those with dilated phase of hypertrophic cardiomyopathy. *Circulation*; **71**:884-890.
32. **Otieno, H., Vivas, Y., Traub, D., Raman, A., and Polam Ch.** 2006. Contrast echocardiography in apical hypertrophic cardiomyopathy. *Circulation*; **114**:33-34.
33. **Panza, J.A., and Maron B.J.** 1989. Relation of electrocardiographic abnormalities to evolving left ventricular hypertrophy in hypertrophic cardiomyopathy during childhood. *Am J Cardiol*; **63**:1258-1265.
34. **Prineas, R., Crow, R., and Blackburn H.** 1982. The Minnesota Code Manual of Electrocardiographic Findings. Standards and Procedures for Measurements and Classification. Boston: John Wright, PSC Inc.
35. **Sato, T., Yamanari, H., Ohe, T., and Yoshinouchi T.** 1996. Regional left ventricular contractile dynamics in hypertrophic cardiomyopathy evaluated by magnetic resonance imaging. *Heart Vessels*; **11**:248-254.
36. **Sato, T., Nakamura, K., Yamanari, H., Yoshinouchi, T., and Ohe T.** 1998. Relationship between electrocardiographic features and distribution of hypertrophy in patients with hypertrophic cardiomyopathy. *Circ J*; **62**:483-488.
37. **Shimizu, M., Ino, H., Yamaguchi, M., Terai, H., Hayashi, K., Nakajima, K., Taki, J., and Mabuchi H.** 2002. Heterogeneity of cardiac sympathetic nerve activity and systolic dysfunction in patients with hypertrophic cardiomyopathy. *J Nucl Med*; **43**(1):15-20.
38. **Terai, H., Shimizu, M., Ino, H., Yamaguchi, M., Uchiyama, K., Oe, K., Nakajima, K., Taki, J., Kawano, M., and Mabuchi H.** 2003. Changes in cardiac sympathetic nerve innervation and activity in pathophysiologic transition from typical to end-stage hypertrophic cardiomyopathy. *J Nucl Med*; **44**(10):1612-1617.
39. **Thaman, R., Gimeno, J.R. , Murphy, R.T., Kubo, T., Sachdev, B., Mogensen, J., Elliott, P.M., and McKenna W.J.** 2005. Prevalence and clinical significance of systolic impairment in hypertrophic cardiomyopathy. *Heart*; **91**:920-925.
40. **Tseng, W.Y., Dou, J., Reese, T.G., and Wedeen V.J.** 2006. Imaging myocardial fiber disarray and intramural strain hypokinesis in hypertrophic cardiomyopathy with MRI. *J Magn Reson Imaging*; **23**:1-8.
41. **Wigle E.D.** 2001. Cardiomyopathy: The diagnosis of hypertrophic cardiomyopathy. *Heart*; **86**:709-714
42. **Wisten, A., Andersson, S., Forsberg, H., Krantz, P., and Messner T.** 2004. Sudden Cardiac Death in the young in Sweden: electrocardiogram in relation to forensic diagnosis. *J Intern Med*; **255**:213-220.